Aucun article ou résumé dans cette revue ne peut être reproduit sous forme d'imprimé, photocopie, microfilm ou par tout autre procédé sans l'autorisation expresse des auteurs et de l'éditeur. Editions Phlébologiques Françaises
No article or abstract in this journal may be reproduced in the form of print, photocopy, microfilm or any other means without the express permission of authors and the editor. Editions Phlébologiques Françaises

Phlébologie ANNALES VASCULAIRES 2019, 72, 1, p. 63-71

SOCIÉTÉ FRANÇAISE DE PHLEBOLOGIE

Chapter 8

Doppler ultrasonography and venous malformations

Fannie Forgues

Summary

Venous malformations (VM) are the most common vascular malformations encountered in the activity of the vascular physician.

Progress in understanding these vascular anomalies has led to the creation of classifications, the major contribution of which is the homogenisation of descriptions and denominations.

The Duplex ultrasound scan (DUS) is the first-line exam to be taken.

It is non-invasive and easily achievable in children and newborns.

It allows the confirmation of the diagnosis of VM by the detection of a slow flow and to refine the diagnosis, by specifying the presence of combined malformations, associating a capillary and/or lymphatic and/or arterial component.

The DUS also allows the diagnosis of the 2 main complications of venous malformations, thrombosis and venous insufficiency.

The examination report must be standardized.

The truncular or extratruncular shape of the VM should be mentioned and as much detail as possible on anatomical relationships and measurements should be noted.

Each VM is unique and each particularity or complication found on ultrasound can have an impact on the choice of treatment.

The purpose of this chapter is to help physicians who are confronted with VMs in their practice to better understand this pathology, so that they can better explore and treat it.

Introduction

For years, the absence of a precise name and classification of vascular malformations has led not only to difficulties in understanding this pathology, but also to diagnostic and therapeutic errors.

The Hamburg and Mulliken classifications have made it possible to standardise the semantics used to describe these lesions, and to improve communication between the actors involved in patient care.

This chapter will discuss the Duplex ultrasound (DUS) examination to be performed in the event of a venous malformation (VM), the vocabulary and important points to be included in the report.

It will also deal with endovenous ultrasound guided treatments.

Definition

According to the classification of the International Society for the Study of Vascular Anomalies, VMs are vascular malformations [1].

They are made up of dysplastic veins whose walls are devoid of smooth muscle cells.

Vascular malformations are abnormalities of the vascular system acquired during embryonic development.

These anomalies may affect the arterial, lymphatic, capillary or venous system.

Vascular malformations can be pure or mixed with each other.

If they are associated with tissue dysmorphic disorders, they are called complex.

Present from birth, they never regress.

Aucun article ou résumé dans cette revue ne peut être reproduit sous forme d'imprimé, photocopie, microfilm ou par tout autre procédé sans l'autorisation expresse des auteurs et de l'éditeur. Editions Phlébologiques Françaises
No article or abstract in this journal may be reproduced in the form of print, photocopy, microfilm or any other means without the express permission of authors and the editor. Editions Phlébologiques Françaises

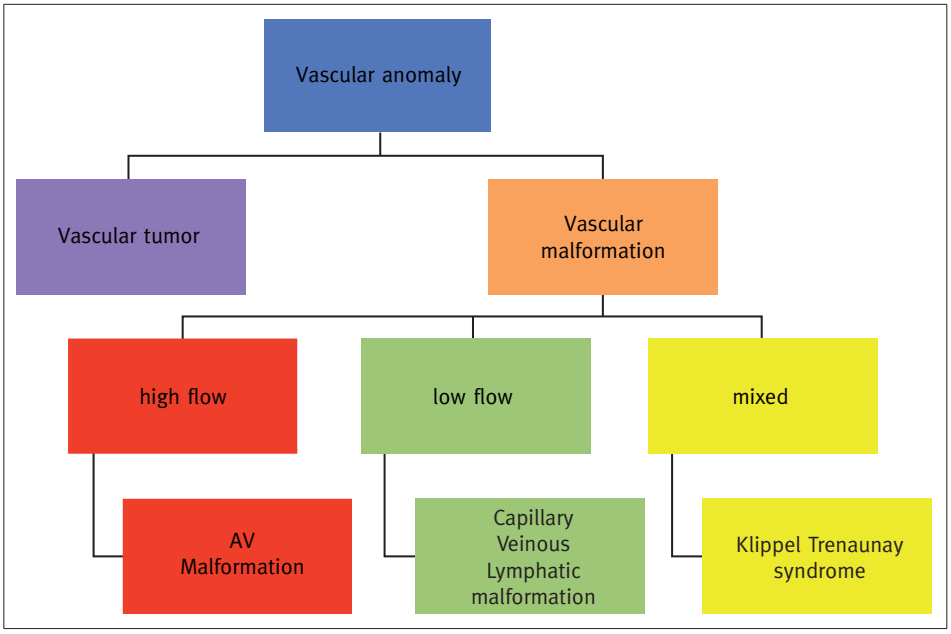

Table 1: Mulliken's classification.

Vascular tumours, unlike vascular malformations, consist of a proliferation of endothelial cells and have the ability to regress.

Mulliken's classification **(Table 1)** takes into consideration the hemodynamics of lesions, distinguishing between low flow malformations (hemodynamically inactive) and high flow malformations (hemodynamically active).

This classification highlights the important role of DUS in the diagnosis of vascular malformations.

A venous malformation is a slow flow malformation.

Classification

Depending on the stage of occurrence of the anomaly, the Hamburg classification **(Table 2)** distinguishes two forms of VM [2].

Extratruncular VMs appear early in embryogenesis, before the formation of venous trunks.

They are made up of immature mesenchymal cells and can proliferate under the influence of the hormonal cycle, during pregnancy, trauma or surgery.

These extratruncular malformations are at high risk of recurrence after treatment.

Table 2: Hambourg Classification.

CLASSIFICATION ACCORDING TO THE PREVAILING VASCULAR FORM
– arterial malformation – arteriovenous malformation – venous malformation – lymphatic malformation – capillary malformation – mixed vascular malformations
CLASSIFICATION ACCORDING TO EMBRYOGENESIS
– extratruncular malformation • infiltrating, • limited – truncular malformation • obstruction - aplasia, hypoplasia, coarctation, • dilatation - localized: aneurysm - diffuse: ectasia

Truncular VMs appear later, during the formation of venous trunks and are limited to a vascular segment.

They are made up of mature cells and have a low risk of recurrence in case of treatment.

Aucun article ou résumé dans cette revue ne peut être reproduit sous forme d'imprimé, photocopie, microfilm ou par tout autre procédé sans l'autorisation expresse des auteurs et de l'éditeur. Editions Phlébologiques Françaises
No article or abstract in this journal may be reproduced in the form of print, photocopy, microfilm or any other means without the express permission of authors and the editor. Editions Phlébologiques Françaises

Epidemiology

Vascular malformations are rare [3] with an overall incidence of 1.5%.

VMs (venous malformations) are the most common and account for two-thirds of vascular malformations.

VMs are most often isolated from the same individual.

The location is ubiquitous [4] with a predominance on the extremities (40%) and the cervico-facial region (40%), with VMs affecting the trunk in only 20% of cases.

VMs can be found in any type of tissue or organ.

In 96% of patients, the lesion is sporadic, but there are rare family forms (multiple cutaneous and mucosal venous malformations, glomuvenous malformations).

Clinic

The clinical signs in a patient with VM are varied.

They depend on the truncular or extratruncular shape of the malformation.

In the case of an extratruncular VM, the signs depend on the location and surrounding tissue.

In mucocutaneous areas, a soft, depressible, non-pulsatile, bluish or purple skin mass or layer is observed, with a normal skin temperature in the absence of complications.

The lesion swells in a sloping position or during a closed glottis force and empties when the limb is raised.

Calcifications are sometimes felt through the skin.

They correspond to phleboliths and are pathognomonic of a venous type malformation.

In the presence of a recent thrombotic complication, the malformation can become hot, hard and painful.

In joint locations, hemarthrosis can cause severe pain and swelling of a joint.

In bone areas, there may be limb asymmetry; fractures have been reported.

In case of airway damage, respiratory disorders can occur, as well as sleep apnea or even respiratory distress with life-threatening prognosis.

Muscle localisation can cause pain, especially after trauma or physical exercise.

In the case of truncular VM, clinical signs are essentially of two kinds, varying according to, whether there are venous obstructions or dilations:

- ***If obstructions:*** **signs of venous insufficiency, development of a tributary venous network, or persistence of an embryonic vein.**
- ***If dilatations:*** **signs related to a thrombo-embolic event.**

A VM, in any form, may also be asymptomatic and incidental discovery, on an imaging examination.

Doppler ultrasound diagnosis

Initial ultrasound checkup: general principles

DUS is the first-line non-invasive examination to be performed on any patient with a VM at the extremities.

It is a safe, reliable, economical and non-irradiating test. It is well adapted to the pediatric population.

It is strongly recommended (grade 1B) before treatment with foam sclerotherapy [5].

A high frequency linear probe (10 to 15 MHz) is used for surface exploration and a low frequency convex probe (3-8 MHz) for deep areas [6].

The examination at the level of the lower limbs must be done lying down and then standing up, it must be bilateral and comparative, and must investigate arterial and venous networks.

When a vascular anomaly is discovered, the Doppler ultrasound must provide some information.

B-Mode echography allows a morphological study of the malformation and the entire vascular network of the region concerned:

- **Simple description of the morphology of the lesion: essentially tissue lesion (vascular tumor) or presence of vessels with few tissues involved (vascular malformation);**
- **Measures of the lesion;**
- **Location of the lesion: vascular segment reached in case of truncal malformation; depth and type of surrounding tissue in extra-truncular malformations (cutaneous, subcutaneous, muscular ...);**
- **Search for evidence for recent thrombosis, compressing the vascular structures with the probe;**
- **Search for phleboliths. Phleboliths are ancient venous thrombi calcifications. They appear as a limited, hyperechoic thickening of the venous wall with a posterior shadow cone (Fig. 2);**
- **Search for other vascular structures near the lesion and their involvement in the malformation;**
- **Study of arterial and venous vascular anatomy of the four limbs and identification of normal vascular structures, anatomical variations and truncular malformations.**

Aucun article ou résumé dans cette revue ne peut être reproduit sous forme d'imprimé, photocopie, microfilm ou par tout autre procédé sans l'autorisation expresse des auteurs et de l'éditeur. Editions Phlébologiques Françaises
No article or abstract in this journal may be reproduced in the form of print, photocopy, microfilm or any other means without the express permission of authors and the editor. Editions Phlébologiques Françaises

The POWER and COLOR DOPPLER Ultrasound allow a hemodynamic study:

- **determination of the type of flow: a slow flow is found in venous malformations;**
- **Doppler settings must be adapted to low speeds, usually in the range of 0 to 5 cm/s, to be able to highlight the flow;**
- **The flow is monophasic with little or no modulation, and has no arterial rhythmicity;**
- **The presence of a spontaneously detected flow in a vein with high velocities and systolic pulsatility indicates an arteriovenous malformation or vascular tumour;**
- **The detection or not of power Doppler arterial rhythmicity within the lesion is an essential element;**
- **It distinguishes between slow flow vascular malformations, fast flow malformations and vascular tumours, for which the management is completely different;**
- **Venous reflux manoeuvres or a Valsalva manoeuvre can be carried out to induce a flow, particularly in VMs, when the flow is not detected spontaneously;**
- **In the case of VM in particular, a venous insufficiency assessment must be carried out with a study of the superficial and deep network.**

Doppler ultrasound of truncular venous malformations

Truncular venous malformations with dilatation

Within truncular VMs with dilatation, the Hamburg classification cites two related entities, synonyms for some authors.

Phlebectasia and venous aneurysm, are essentially distinguished by a morphological criterion which is the extent of dilation on the venous trunk, with phlebectasia reaching a larger venous segment.

The DUS examination looks for the same data for both malformations.

Phlebectasia is a regular dilatation involving a significant part of a venous trunk or its entirety [7]

In the deep venous network, this is the most common truncular VM.

They can be located in the superficial or deep venous network.

Phlebectasia can be asymptomatic, and are often discovered by chance, especially in abdominal locations or in the deep venous network of the lower limbs.

In superficial areas, they are more easily identifiable, but remain under-diagnosed because of the lack of knowledge of this malformation by a large proportion of physicians [8].

Jugular phlebectasias are the most commonly reported in the literature and are most often asymptomatic or not very symptomatic.

However, laryngeal and pharyngeal discomfort, major bleeding due to trauma, thromboembolic complications and Claude-Bernard-Horner syndrome have been described.

The DUS is the first-line examination, due to its non-invasive nature; in many cases it is enough for monitoring phlebectasias **(Fig. 1a, b, c, d)**.

In B Mode echography, phlebectasia is a regular dilatation spread over a segment of the vein, with a normal diameter upstream and downstream.

Bilateral examination, when possible, is important for comparing diameters between the healthy and dilated sides.

The measurement of the maximum antero-posterior diameter, made in cross-section, and the extent of phlebectasia, measured in longitudinal section, should be noted in the report to allow monitoring of the malformation.

In the case of jugular phlebectasia in children, Eksioglu [9] suggests that an antero posterior diameter greater than 15 mm is necessary to confirm the diagnosis.

Compression with the probe allows the authentication of a thrombus, either partially obstructive (wall thrombus) or totally obstructive.

A sludge can also be visualized showing the venous stasis within the dilated vein portion.

In color doppler, the flow is sometimes "not visualised" due to slow speeds.

With the help of venous reflux manoeuvres, the color mode allows to complete the description of a possible thrombus (wall, non-occlusive, occlusive).

The power Doppler, in the absence of complication, returns to a monophasic flow with respiratory rhythmicity.

In the case of phlebectasia, reflux is often found with pathological thresholds of more than one second at the deep venous network and half a second at the superficial network.

Venous aneurysm is defined as a localised dilatation of a non-varicose venous segment

The maximum diameter of the aneurysm is one and a half to two times larger than the diameter of the healthy vein upstream or downstream [10].

This malformation is dangerous because it is often asymptomatic and under-diagnosed; it is not uncommon for its first clinical manifestation to be a pulmonary embolism.

Aucun article ou résumé dans cette revue ne peut être reproduit sous forme d'imprimé, photocopie, microfilm ou par tout autre procédé sans l'autorisation expresse des auteurs et de l'éditeur. Editions Phlébologiques Françaises
No article or abstract in this journal may be reproduced in the form of print, photocopy, microfilm or any other means without the express permission of authors and the editor. Editions Phlébologiques Françaises

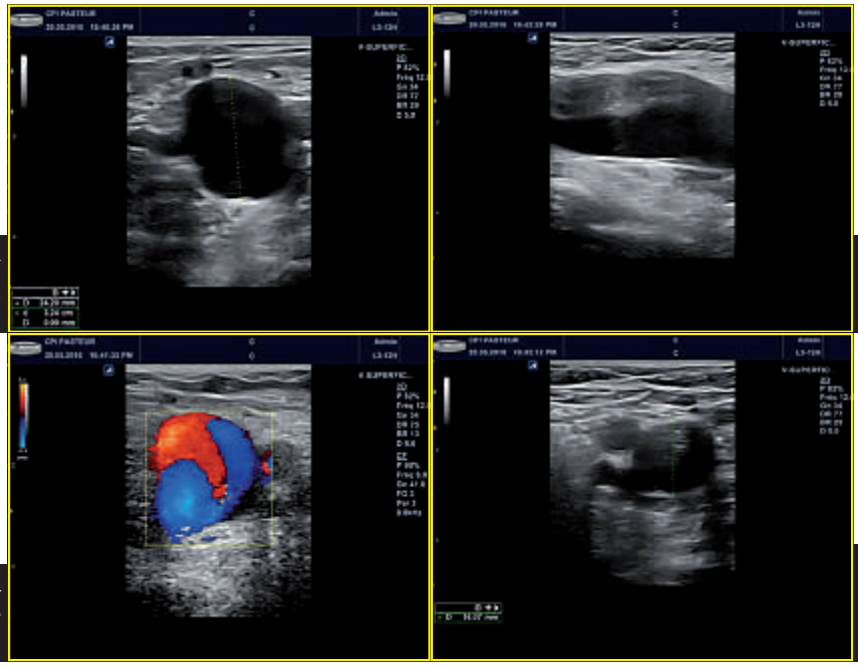

Fig. 1a: Left femoral vein phlebectasia in cross section in B mode.

Fig. 1b: Longitudinal section in B mode with a sludge.

Fig. 1c: Colour Doppler cross section: absence of wall thrombus.

Fig. 1d: Measurement of the antero- posterior diameter of the contralateral common femoral vein.

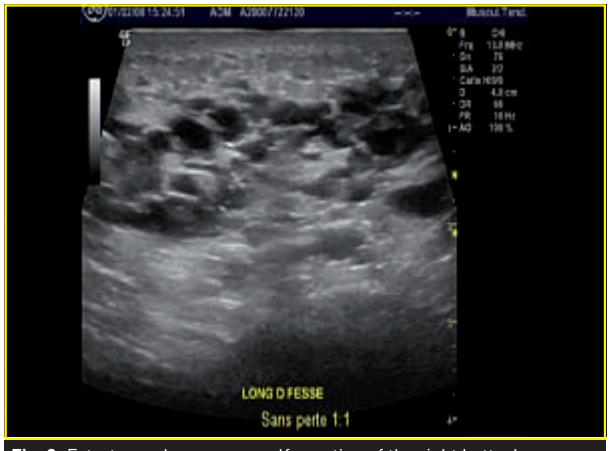

Fig. 2: Extratruncular venous malformation of the right buttock, integrated into a complex venous, lymphatic and capillary malformation with digestive and urinary damage.

Presence of wall thrombus and a phlebolith with posterior acoustic shadow cone.

The DUS examination is identical to that described for phlebectasia and focuses on the morphological description of the lesion and the search for thrombotic complications and venous insufficiency.

Truncular venous malformations with obstruction

Aplasias and hypoplasias are mainly represented.

These malformations, when they occur on the deep venous network, are accompanied by a tributary venous network that must be mapped.

Aplasia or hypoplasia of the inferior vena cava may initially be manifested by ilio-femoral venous thrombosis.

Before this episode, most patients are asymptomatic thanks to tributary veins through the lumbar and epigastric azygos network.

The occurrence of thrombosis unbalances the venous flow in the tributary network and leads to severe post-thrombotic syndrome in almost all of these patients.

In the lower limbs, the collaterality of deep venous network obstruction is ensured by the nearby superficial veins or by a persistent embryonic vein.

The tributary superficial venous network and the discomfort to venous return caused by hypoplasia or aplasia, generate signs and symptoms of venous insufficiency in the affected limb.

A tributary vein is dilated due to additional loading and increased flow and has spontaneous slow venous flows at Doppler.

These veins may remain competent but are most often incompetent, either by excessive dilatation of the vein or by avalvulia in persistent embryonic veins.

Aucun article ou résumé dans cette revue ne peut être reproduit sous forme d'imprimé, photocopie, microfilm ou par tout autre procédé sans l'autorisation expresse des auteurs et de l'éditeur. Editions Phlébologiques Françaises
No article or abstract in this journal may be reproduced in the form of print, photocopy, microfilm or any other means without the express permission of authors and the editor. Editions Phlébologiques Françaises

The destruction of a tributary network is formally contraindicated, since it exposes the patient to a worsening of his venous insufficiency, which can lead to the appearance of an ulcer or venous claudication.
It is therefore essential to clearly identify, when it exists, a tributary vein in DUS, and to differentiate it from a varicose vein.

The DUS examination of any dilated superficial vein of the lower limbs requires a morphological and hemodynamic study of the entire venous network of the lower limbs.

Diagnosis of aplasia or popliteal hypoplasia is sometimes difficult with DUS, because of the large tributary varicose veins that prevent its identification.

In B mode, a venous segment is nonexistent or has a narrowed size.

The discovery of a persistent embryonic vein should lead to a systematic search for aplasia of a homolateral deep venous trunk.

Persistent embryonic veins are also considered truncular VM [11].

It is a vein of the embryonic vascular system that has not regressed during the truncular phase of angiogenesis and persists after birth.

The immaturity of the cells, of which it is composed, leads to the absence of a valve in this vein and therefore to severe venous reflux in orthostatism.

Like any VM, these persistent embryonic veins are at high risk of thromboembolic events, especially in patients with Klippel-Trenaunay syndrome.

The DUS examination, in addition to specifying the state of the deep venous network, the presence of reflux or thrombotic complications, allows the mapping of the lateral marginal vein and its incontinent perforators.

The two persistent embryonic veins:

The lateral marginal vein:

- **The marginal lateral vein has a tortuous path on the lateral face of the lower limb;**
- **Its involvement in the deep venous network [12] is found in 33% of the cases in the internal iliac vein, in 37% in the femoral veins (superficial or deep), in 14% in the great saphenous vein and in 11% in the popliteal vein;**
- **When the approach is at the lower limb, the whole course of the marginal veins is well followed by ultrasound and the perforating well visualized;**
- ***A lateral marginal vein* may not be associated with deep vein obstruction;**
- **In this case it is easy to access and if necessary, it can be treated by surgical and thermal ablation or by injection (sclerotherapy with foam).**

Sciatic vein:

- ***The sciatic vein* is intrafascial and follows the sciatic nerve on the posterior thigh;**
- **In its complete form, it is born from the popliteal vein and terminates in the internal iliac vein;**
- **Its access is more difficult for a treatment.**

Avalvulia, or absence of a valve, is another form of hypoplasia and is therefore considered as an obstructive truncular VM

This anomaly affects the superficial or deep venous network at the extremities.

This results in severe signs of venous insufficiency, with no history of venous thrombosis, in a young subject.

DUS allows diagnosis by showing severe reflux, particularly in the deep veins, without associated thrombotic sequelae (occlusion, sequestration, tributary network).

On the contrary, the vein is regular, without any observed valvular sinus or valve, along the entire path of the vein.

Doppler ultrasound of extratruncular venous malformations

The DUS examination is used to determine the location, possible extension of the malformation, drainage veins and their connections.

It also allows the diagnosis of frequent thrombotic complications.

The semantics used in the report are very important.

It allows a clear and intelligible description of the VM by the greatest number of people.

Thus, we can distinguish between limited and infiltrating malformations.

- ***In case of localised malformation*, the malformation is small and it is necessary to specify the nature of the surrounding tissue (muscular, subcutaneous...).**
- ***In case of diffuse malformation*, it is necessary to note the anatomical territories concerned, such as the lateral face of the thigh and leg, and the different invasive tissue planes that can be explored on ultrasound.**

The DUS analysis in the vast majority of cases, makes it possible to specify whether it is a pure VM or a combined malformation.

In B mode echography, pure extratruncular VM [13] is presented in the form of anechoic pockets, grouped in clusters, of variable size.

In the absence of complication, these pockets are compressible under the probe, and a sludge can be visualized.

Aucun article ou résumé dans cette revue ne peut être reproduit sous forme d'imprimé, photocopie, microfilm ou par tout autre procédé sans l'autorisation expresse des auteurs et de l'éditeur. Editions Phlébologiques Françaises
No article or abstract in this journal may be reproduced in the form of print, photocopy, microfilm or any other means without the express permission of authors and the editor. Editions Phlébologiques Françaises

In case of incompressibility, it may be either a combined veno-lymphatic malformation or a thrombosis.

In the latter case, endoluminal material is found.

In color doppler, with the help of venous reflux manoeuvres, color mounts the thrombus.

The number of veins allowing the drainage of the malformation must be noted as well as the diameter and the end point of each of these veins.

In power doppler, there is a single-phase slow flow. Sometimes venous reflux and Valsalva manoeuvres are necessary to highlight the venous flow.

Combined malformations associate a venous component with a lymphatic and/or capillary and/or arterial component

The DUS examination is not contributive for the diagnosis of the capillary component.

On the other hand, in the case of a venolymphatic malformation, the lymphatic component appears as a transonic cystic mass, well limited, united or multilocular of more or less large size.

In case of intracystic hemorrhage, the contents become echogenic and a fluid level can be visualized.

In power Doppler, no flow is detected within the lesion.

A low vascular flow can be found in the periphery or in the septa.

Ultrasound in B mode finds a nidus with afferent arteries and dilated drainage veins, in case of arteriovenous malformation.

Within the nidus, there is a cardiac rhythmic flow with a significant diastolic component and high circulatory velocities.

In drainage veins, the flow has arterial modulation with high velocities for venous flow.

Complex venous malformations

Complex VMs associate one or more vascular malformations with tissue damage.

The most well-known complex VM remains Klippel-Trenaunay syndrome.

In two thirds of cases [14], it is in the form of a clinical triad combining:

- **a superficial or deep truncular VM,**
- **a capillary malformation (98% of cases) and/or extratruncular VM in the muscle and/or lymphatic malformation,**
- **bone or soft tissue hypertrophy.**

The most common site of injury is at the extremities (lower limbs).

Truncular VM results in often abnormal venous drainage at the affected extremity, with persistent embryonic vein, aplasia or hypoplasia of a deep venous segment, valvular incompetence and/or venous phlebectasia or aneurysms.

Limb hypertrophy is essential for diagnosis.

For this reason, X-ray images with comparative measurements of the lower limbs are included in the initial check-up.

The affected limb is increased in length and circumference by bone and muscle hypertrophy.

The risk of bleeding on varicosities, particularly visceral varicosities, and the risk of thromboembolism coexist in these patients.

Bean syndrome or Blue rubber bled nevus syndrome combines cutaneous and visceral VMs [15].

The extratruncular cutaneous VMs are distributed throughout the body, with a predominance on the palms of the hands and the soles of the feet.

They are in the form of blue, soft nodules made of "rubber nipples'.

Visceral VMs cause digestive bleeding, sometimes occult, revealed by anemia, or sometimes in the form of haematemesis or melena.

Digestive bleeding is the major cause of severity of this syndrome.

Maffucci syndrome [16] combines superficial extratruncular VMs located in the form of blue nodules and multiple enchondromas, at high risk of degeneration into chondrosarcoma.

Enchondromas are mainly located on the fingers and toes, leading to bone deformities and fractures.

Ultrasound guidance and endovenous treatment

Ultrasound guidance is used in the treatment of mainly extratruncular VMs, with foam sclerotherapy and endovenous laser ablation.

Before any interventional treatment, except in rare cases of limited superficial VM, an MRI is performed to confirm the pure venous component of the malformation, to specify the deep extension of the lesion and its relationship to the normal truncular venous network (grade 1A) [17].

A multidisciplinary committee advice is necessary. This committee makes it possible to confirm the diagnosis and to propose the most appropriate treatment according to the lesion and the patient's expectations.

In the case of localised intravascular coagulopathy (LIC) of the malformation, which may be complicated by thrombosis or bleeding during an invasive procedure, physicians of the multidisciplinary committee issue an opinion about anticoagulant therapy surrounding the procedure.

Aucun article ou résumé dans cette revue ne peut être reproduit sous forme d'imprimé, photocopie, microfilm ou par tout autre procédé sans l'autorisation expresse des auteurs et de l'éditeur. Editions Phlébologiques Françaises
No article or abstract in this journal may be reproduced in the form of print, photocopy, microfilm or any other means without the express permission of authors and the editor. Editions Phlébologiques Françaises

Currently, there is no consensus on the use of anticoagulant therapy to prevent thrombotic complications.

An invasive procedure is indicated:

- in the prevention of haemorrhagic or thrombotic complications;
- in the event of a location where the vital prognosis is at stake, particularly in the airways;
- if the patient has pain or a functional difficulty that affects his/her quality of life;
- if the aesthetic damage is significant [18].

Sclerotherapy is an invasive procedure used in the treatment of Venous Malformations.

The most effective sclerosing agent is absolute alcohol, but it provides many complications, such as deep vein thrombosis and pulmonary embolism, nerve damage and skin necrosis.

It is therefore necessary to hospitalise the patient to monitor the consequences of alcohol sclerosis.

The procedure is performed under general anesthesia and fluoroscopy.

Due to the high rate of complications with alcohol and the severity of these complications, the use of ultrasound-guided foam sclerotherapy has undergone significant development.

Indeed, even if it is a less efficient treatment, ultrasound guided foam sclerotherapy with sodium tetradecyl sulfate or polidocanol, provides good results on symptom improvement with few complications [19].

In case of limited superficial malformation, foam sclerotherapy can be performed in a medical office.

Before any treatment, the DUS makes it possible to check again the absence of arterial flow.

It then makes it possible to identify the target bag and choose the injection site.

Most often, the puncture is done directly with a needle. It is advisable not to push suddenly on the piston of the syringe because the massive and too fast arrival of foam causes immediate pain in the treated area.

Since the veins are devoid of muscle cells, there is no venous spasm when the sclerosing agent is injected, but only a simple filling of the vascular lumen.

Ultrasound identification of drainage veins and their relationship to the deep venous network at the extremities is important to stop injection and limit the risk of deep venous thrombosis. The volumes injected must remain reasonable, even if it means repeating consultations.

Endovenous thermal ablation needs DUS control before treatment to make sure in the absence of thrombosis and to perform echo mapping, even if this is often reduced to its bare essentials.

Then, the ultrasound guidance is almost constant: for the choice of puncture site, for the tumescence and for the positioning of the probe.

Treatment of VM with the endovenous laser seems to provide good results with little recurrence; it is particularly true for head and neck VMs [20].

Thermal venous ablation techniques are also recognised as effective in the treatment of superficial venous insufficiency.

They may be indicated in the case of dilated truncular malformation of the superficial venous network of the limbs or in the case of persistent embryonic vein, after ensuring the normality of the deep venous network and the absence of collaterality.

Ultrasound monitoring is recommended after performing an interventional procedure.

It includes a first ultrasound control one week after the procedure to ensure that there is no venous thrombosis.

If there are no complication, a second ultrasound control is performed six to twelve weeks after the procedure to evaluate the effectiveness of the treatment and the possible persistence of untreated venous segments.

Additional treatment sessions may be necessary to achieve the desired result.

Thereafter, an annual follow-up by ultrasound is desirable to verify the effectiveness of the treatment in the medium and long term and to detect late recurrences.

Conclusion

Venous malformations are the most common malformations found in a vascular practice.

The investigation and the clinical inspection remain essential before the Doppler ultrasound examination is carried out.

The DUS confirms the absence of cell proliferation and the presence of a slow flow in the vessel.

The conclusion of the report should indicate the kind of malformation found according to the Hamburg and Mulliken classifications, the specific characteristics of the malformation explored, and any complications found.

The decision to operate for these VMs should be discussed in a multidisciplinary committee.

The choice is often made first of all for endovenous, echo-guided minimally invasive techniques, but these can also be used in combination or as a complement to surgery.

Aucun article ou résumé dans cette revue ne peut être reproduit sous forme d'imprimé, photocopie, microfilm ou par tout autre procédé sans l'autorisation expresse des auteurs et de l'éditeur. Editions Phlébologiques Françaises
No article or abstract in this journal may be reproduced in the form of print, photocopy, microfilm or any other means without the express permission of authors and the editor. Editions Phlébologiques Françaises

Bibliography

[1] Enjolras O., Mulliken JB. Vascular tumors and vascular malformations (new issues). Adv Dermatol. 1997; 13: 375-423.

[2] Belov S. Classification of congenital vascular defects. Int Angiol J Int Union Angiol. sept 1990; 9(3): 141-6.

[3] Eifert S., Villavicencio JL., Kao TC., Taute BM., Rich NM. Prevalence of deep venous anomalies in congenital vascular malformations of venous predominance. J Vasc Surg. mars 2000; 31(3): 462-71.

[4] Fishman SJ., Mulliken JB. Hemangiomas and vascular malformations of infancy and childhood. Pediatr Clin North Am. déc 1993; 40(6): 1177-200.

[5] Rabe E., Breu FX., Cavezzi A., Coleridge Smith P., Frullini A., Gillet JL., et al. European guidelines for sclerotherapy in chronic venous disorders. Phlebol Venous Forum R Soc Med. juill 2014; 29(6): 338-54.

[6] Laroche J-P., Becker F., Khau-Van-Kien A., Baudoin P., Brisot D., Buffler A., et al. Quality standards for ultrasonographic assessment of peripheral vascular malformations and vascular tumors. Report of the French Society for Vascular Medicine. J Mal Vasc. févr 2013; 38(1): 29-42.

[7] Malik V., Kumari A., Murthy T. Unusual case of focal neck swelling: Phlebectasia of internal jugular vein with intracranial extension. Int J Appl Basic Med Res. avr 2015; 5(1): 58-60.

[8] Sander S., Eliçevik M., Unal M., Vural O. Jugular phlebectasia in children: is it rare or ignored? J Pediatr Surg. déc 1999; 34(12): 1829-32.

[9] Eksioglu AS., Senel S., Cinar G., Karacan CD. Sonographic measurement criteria for the diagnosis of internal jugular phlebectasia in children. J Clin Ultrasound JCU. oct 2013; 41(8): 486-92.

[10] Lee BB., Villavicencio L., Chapter 68. General considerations. Congenital vascular malformations. Section 9. Arteriovenous anomalies. In: Rutherford's vascular surgery 7th ed Saunders Elsevier 2010: 1046-64.

[11] Lee BB. Marginal vein is not a varicose vein; it is a venous malformation. Veins Lymphat. 2014; 3(4050): 64-70.

[12] Lefebvre D., Elias A., Leger P. Anomalies veineuses congénitales des membres inférieurs. *In:* EMC. Elsier Masson; 2004. (Radiologie et imagerie médicale; vol. 32-225-NaN-20).

[13] Masand P. Radiographic findings associated with vascular anomalies. Semin Plast Surg. mai 2014; 28(2): 69-78.

[14] Jacob AG., Driscoll DJ., Shaughnessy WJ., Stanson AW., Clay RP., Gloviczki P. Klippel-Trénaunay Syndrome: Spectrum and Management. Mayo Clin Proc. 1 janv 1998; 73(1): 28-36.

[15] Enjolras O. Systematized complex vascular malformations. Rev Prat. 15 oct 1992; 42(16): 2048-52.

[16] Kaplan RP., Wang JT., Amron DM., Kaplan L. Maffucci's syndrome: two case reports with a literature review. J Am Acad Dermatol. nov 1993; 29(5 Pt 2): 894-9.

[17] Gloviczki P. Handbook of Venous Disorders: Guidelines of the American Venous Forum Third Edition. CRC Press; 2008. 769 p.

[18] Lee BB., Baumgartner I., Berlien P., Bianchini G., Burrows P., Gloviczki P., et al. Guideline. Diagnosis and treatment of venous malformations. consensus document of the international union of phlebology (iup): updated-2013. Int Angiol J Int Union Angiol. 10 juin 2014.

[19] Yamaki T., Nozaki M., Sakurai H., Takeuchi M., Soejima K., Kono T. Prospective randomized efficacy of ultrasound-guided foam sclerotherapy compared with ultrasound-guided liquid sclerotherapy in the treatment of symptomatic venous malformations. J Vasc Surg. mars 2008; 47(3): 578-84.

[20] Bisdorff-Bresson A. Thérapeutiques endovasculaires des malformations veineuses périphériques. Moyens thérapeutiques. *In :* Thérapeutiques endovasculaires des pathologies veineuses. 2013. p. 265-70.