Aucun article ou résumé dans cette revue ne peut être reproduit sous forme d'imprimé, photocopie, microfilm ou par tout autre procédé sans l'autorisation expresse des auteurs et de l'éditeur. Editions Phlébologiques Françaises
No article or abstract in this journal may be reproduced in the form of print, photocopy, microfilm or any other means without the express permission of authors and the editor. Editions Phlébologiques Françaises

Phlébologie ANNALES VASCULAIRES 2019, 72, 2, p. 78-91

SOCIÉTÉ FRANÇAISE DE PHLEBOLOGIE

Chapter 19

Duplex ultrasound assessment in PREsence of Varicose veins After operatIve Treatment (PREVAIT)

Luc Moraglia

Abstract

The relatively recent evolution of the treatment of superficial venous insufficiency has led to the emergence of new forms of recurrences; all recurrences are referred under acronym PREVAIT (**PRE**sence of Varicose veins **A**fter operat**I**ve **T**reatment).

The frequency of PREVAIT is estimated at 13 to 65%. Therapeutic management requires a meticulous Doppler assessment, in the form of a written report and precise mapping.

This assessment will be greatly facilitated by an effective methodology based on sufficient knowledge of the different modes of recurrences and their expressions.

This chapter aims to systematize as much as possible these modes and expressions of varicose recurrences and offers practical remarks and advices to carry out this sometimes difficult assessment.

The latest studies published on the subject show that varicose recurrences after operative intervention will remain a daily problem for vascular physicians for a long time to come. The echodoppler assessment is the essential diagnostic and pre-therapeutic step.

Introduction

Since the beginning of the 21st century, the management of superficial venous insufficiency has evolved considerably. Previously, the notion of varicose recurrences was essentially represented by recurrences after surgery (REVAS [1]).

The development of endovenous, chemical and thermal ablative techniques and, to a lesser extent, minimally invasive surgical techniques, presenting also specific varicose recurrence possibilities, has led to the definition of a concept to cover all situations.

PREVAIT is the acronym proposed by the VEIN-TERM consensus [2] meaning the PREsence of Varices After operatIveTreatment.

Three types of varicose veins are possible:

A - Real recurrences, by the reappearance of varicose veins in the operated area (not visible at the recommended follow-up Duplex ultrasound at one month) that may result from different processes:

- **The transformation of healthy veins into incompetent veins, generally due to the evolution of the disease, multifactorial and multidimensional etiology where all levels of the venous system, superficial, deep and perforator system, can be involved.**
- **Neovascularization is frequently involved in junctional recurrences [3] and, in general, at any post-surgical healing site, such as the interfascial channel of saphenous trunk stripping.**
- **Recanalization of occluded veins after ablative endovenous treatment.**

B - Residual varicose veins after the surgical treatment that are visible during the duplex ultrasound check at one month. They result either from a conservative tactical choice or from an incomplete technical procedure. This framework of technical errors was particularly rich at a time when conventional surgery was more or less "blind". In 2006 Perrin reported 29% of tactical and/or technical errors in patients with REVAS [4].

Aucun article ou résumé dans cette revue ne peut être reproduit sous forme d'imprimé, photocopie, microfilm ou par tout autre procédé sans l'autorisation expresse des auteurs et de l'éditeur. Editions Phlébologiques Françaises
No article or abstract in this journal may be reproduced in the form of print, photocopy, microfilm or any other means without the express permission of authors and the editor. Editions Phlébologiques Françaises

C - New varicose veins in another territory, absent during the one-month control, responding to the natural evolution of chronic venous disease.

The possible causes of these recurrences are therefore:

- **Tactical errors.**
- **Technical errors.**
- **Neovascularization.**
- **Progression of the disease.**
- **Intrication of 2 or more of these causes.**

We will come back to this later.

The frequency of PREVAIT is evaluated, depending on studies and techniques used, from 13 to 65% [5] of patients, which justifies the importance of careful assessment, particularly by duplex ultrasound (**DUS**), to develop effective management.

For reasons of simplification of the statement, we will use the term "recurrence" generically, taking care, when necessary, to specify the possible residual nature of the varicose vein described. It should be pointed out that in many cases the distinction is hardly possible and that the intertwining between the different determinants of recurrence makes this distinction ineffective.

Having at his disposal the precise operating report and the report of the preoperative DUS examination established according to the required quality standards [6] increases the chances of correctly analysing recurrence.

Recurrence is evident in the presence of varicose veins after operative intervention, but it may also be suspected in the presence of evocative symptoms during the follow-up. The DUS examination detect early stages of recurrence [7] and is the recommended examination to properly assess recurrence, the first step in appropriate management [8].

This examination doesn't differ much technically from the initial examination [9] and will focus on the superficial venous network, perforating veins (frequently involved in recurrences [10]) and the deep venous network. It will be necessary to describe the leakage points, sources of reflux, the path of the varicose veins and their drainage.

Junctional recurrences in the inguinal area and their drainage

Incomplete resection, due to technical inadequacy, of the saphenofemoral junction (SFJ) **(Fig. 1 and 2)**

Residues of this anatomical entity that is the junction may be more or less visible (terminal valve, intervalvular segment, inguino-abdominal or genital venous afferences of the junction, preterminal valve).

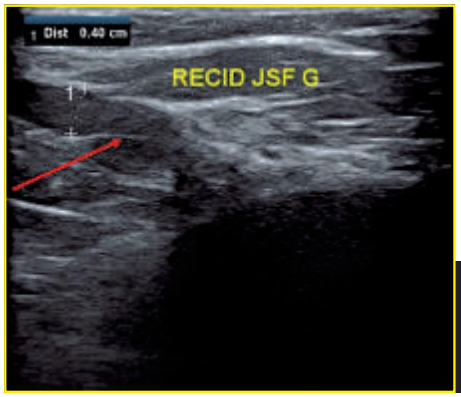

Fig. 1: Cross section left Lower limb: incomplete SFJ resection. Valve in place.

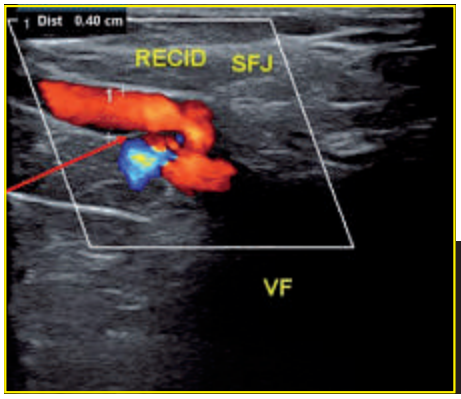

Fig. 2: Cross section left Lower limb: incomplete SFJ resection. Valve in place. Color Doppler.

The diameter of this junctional stump must be indicated; the hemodynamic study will specify the refluxes.

Voluntarily preserved junctions in endovenous ablative procedures. **(Fig. 3)**

For these techniques, chemical or thermal, the rule is not to intervene on the SFJ; therefore this situation is occurring more and more frequently.

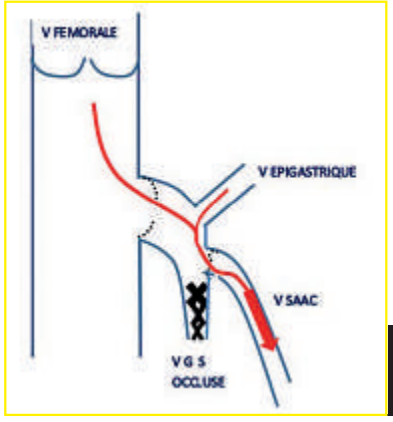

Fig. 3: Recurrence to AASV after endovenous ablative procedure of GSV.

Aucun article ou résumé dans cette revue ne peut être reproduit sous forme d'imprimé, photocopie, microfilm ou par tout autre procédé sans l'autorisation expresse des auteurs et de l'éditeur. Editions Phlébologiques Françaises
No article or abstract in this journal may be reproduced in the form of print, photocopy, microfilm or any other means without the express permission of authors and the editor. Editions Phlébologiques Françaises

When this SFJ is incompetent, it is part of the junctional recurrences.

The reflux can drain into the recanalised trunk, the diameter and length of which will be measured.

But the Anterior accessory Saphenous Vein (AASV) plays an important role in the recurrences observed after endovenous procedures. The incompetence of SFJ is spreading in AASV, which is the cause of a recurrence that is frequently symptomatic [11].

The IUP consensus on the DUS investigation after treatment for varicose veins proposes a classification of echo-hemodynamic results after endovenous ablation [12], which is reproduced below for information.

J: for SFJ or SPJ:
- J0: no patent stump
- J1, J2, J3, J4 etc.: junction with patent stump of 1, 2, 3, 4 cm etc.
RD: reflux; R-: no reflux
T: for GSV/AASV/SSV trunk:
- Ti: invisible trunk
- To: obliterated trunk (diameter: ... mm)
- Tp: completely or partially patent trunk (diameter: ... mm)
- To/Tp or Tp/To: segmental obliteration/patency or patency/obliteration (length of patent segment: ... cm; diameter of residual lumen: ... mm)
RD: reflux; R-: no reflux

Voluntarily preserved junctions after CHIVA or ASVAL

The analysis of the hemodynamic situation after a CHIVA (conservative hemodynamic treatment of venous insufficiency in ambulatory care) or an ASVAL (selective removal of varicose veins under local anaesthesia) will depend on the knowledge of the pre-operative echo-anatomical and hemodynamic status.

Thus, the presence of a reflux in a great saphenous trunk is not necessarily abnormal in the context of a CHIVA (reinjection of the reflux at depth through a reentry perforator, for example) or an ASVAL (persistence of a reflux pending the expected self-regulation after removal of the varicose reservoir).

Junctional recurrences with groin varicose network (GVN) [9]

GVN [12] is a term which covers the presence of reflux veins at the inguinal level, which can be derived from either:

- **of neovascularization**
- **or the dilation of pre-existing veins, particularly Lymph Node Varicose Network (LNVN).**

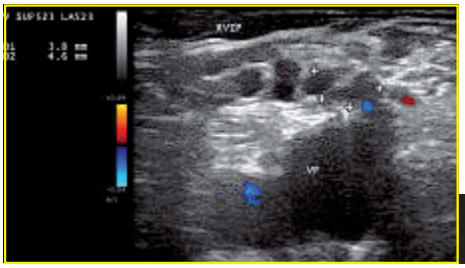

Fig. 4: Cross section right lower limb: GVN by Neovascularization.

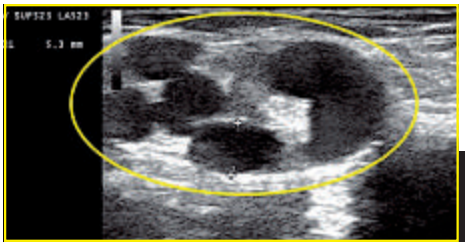

Fig. 5: Cross section: Characteristic aspect of LNVN in the inguinal area.

Fig. 6: Cross section Left lower limb: Recurrence SFJ neovascularization.

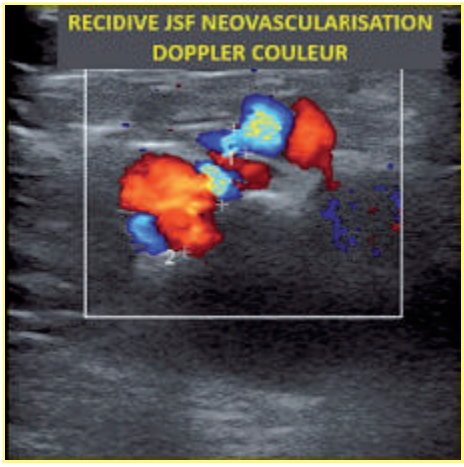

Fig. 7: Cross section Left lower limb: JSF recurrence neovascularization color Doppler.

Aucun article ou résumé dans cette revue ne peut être reproduit sous forme d'imprimé, photocopie, microfilm ou par tout autre procédé sans l'autorisation expresse des auteurs et de l'éditeur. Editions Phlébologiques Françaises
No article or abstract in this journal may be reproduced in the form of print, photocopy, microfilm or any other means without the express permission of authors and the editor. Editions Phlébologiques Françaises

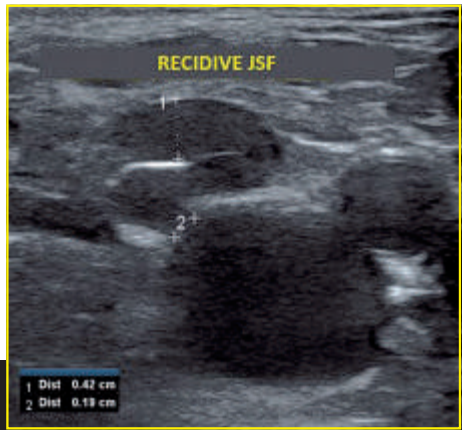

Fig. 8: Cross section Left lower limb: Univocal SFJ recurrence.

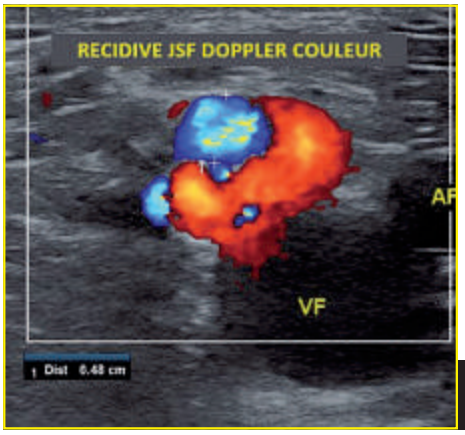

Fig. 9: Cross section Left lower limb: Univocal SFJ recurrence color Doppler.

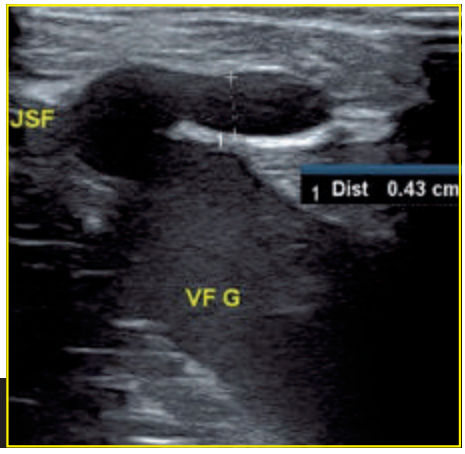

Fig. 10 : Cross section Left lower limb: Univocal JSF recurrence.

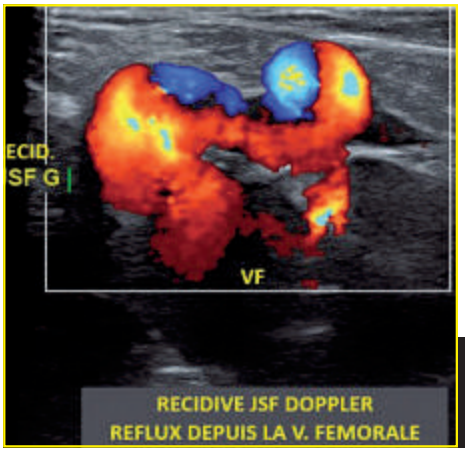

Fig. 11 : Cross section Left lower limb: Univocal SFJ recurrence: visualization of femoral reflux by color Doppler.

Neovascularization is defined in the Vein-Term consensus [2] by the presence of multiple new and tortuous veins, near an anatomical area of a previous venous operative intervention. Their wall is not visible in mode B ultrasonography; colour Doppler can distinguish a single channel (univocal circulatory direction) from a channel consisting of these multiple small vessels (different circulatory directions).

The frequency of neovascularization after endovenous procedures is low [13]; recurrences are represented by recanalizations or by drainage of the junction left in place, when it is incompetent, in an anterior accessory saphenous vein of the thigh or subcutaneous veins.

Dilation of pre-existing veins, as part of a phenomenon adaptive to a local hemodynamic situation considerably modified after stripping and/or high ligation, is probably frequently intertwined with true neoangiogenesis phenomena.

Echographically, the distinction is very difficult, it is rather an etiological diagnosis, which in practice is not of interest, especially since it will not modify the treatment.

Like Stücker [14], it is possible to include in a global "neovascularization" concept the true neoangiogenesis and this adaptive hypertrophy, postoperative, of pre-existing vessels.

When GVN reaches a significant size, it is often referred to as a "cavernoma". This large dilated network is generally next to the junction ligature site. It can communicate with the femoral vein, sometimes at full channel, and present a real therapeutic difficulty; but it can also not be connected with the femoral vein, fed by non-junctional reflux sources (see the chapter on non-junctional recurrences).

The search for reflux (Fig.10 et 11)

It will be done by muscular compression release and/or Vasalva maneuvers. The Vasalva maneuver is only used at the proximal thigh level. In this case:

Aucun article ou résumé dans cette revue ne peut être reproduit sous forme d'imprimé, photocopie, microfilm ou par tout autre procédé sans l'autorisation expresse des auteurs et de l'éditeur. Editions Phlébologiques Françaises
No article or abstract in this journal may be reproduced in the form of print, photocopy, microfilm or any other means without the express permission of authors and the editor. Editions Phlébologiques Françaises

A positive Vasalva maneuver involves a reflux of deep or pelvic-perineal origin.
A reflux only during the compression release maneuver indicates a reflux from the tributaries of the tested vein or from abdominal skin veins.
To validate the notion of junctional recurrence, it is therefore necessary to visualize the reflux into the GVN from the femoral vein, in the operated area. The diameter of the communication must be indicated. Some authors place the limit for a surgical revision at a caliber greater than or equal to 4 mm [15].

Drainage of inguinal junctional recurrences

The reflux can drain in different ways depending on the operating protocol used during the previous procedure.
In the interfascial (saphenous) compartment it may be:

- **The residual trunk or trunk segment of the great saphenous vein or the anterior (or posterior) accessory saphenous vein of the thigh.**
- **The interfascial segment of the Giacomini vein.**
- **A dystrophic plexiform network consisting of small caliber incompetent veins in the interfascial compartment due to neovascularization phenomena.**
- **A flowing channel refluxing in the path of the stripped saphenous vein [16].**

In the supra-fascial (subcutaneous) compartment it may be:

- **Residual tributaries, initially incompetent or not.**
- **Intersaphenous communicators.**

Finally, the reflux can drain into a perforator.

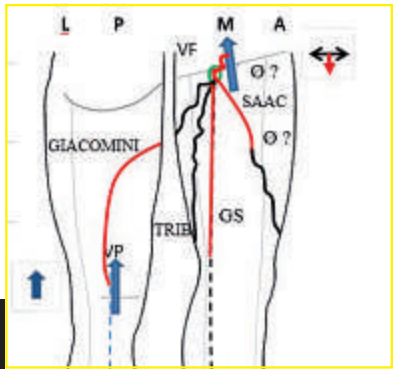

Fig. 12: Diagram SFJ recurrence Some drainage ways.

Junctional recurrences in the popliteal area and their drainage

The sapheno-popliteal junction (SPJ) is not constant, unlike the sapheno-femoral junction, and has a high anatomical variability.
SPJ exists in 60% to 90% of cases but Lemasle has shown that in patients with varicose vein disease (which is the case here) SPJ is present in 90% of cases [17].
The implantation face of this junction on the popliteal vein also varies [17]:

- **Lateral face: 54%.**
- **Medial side: 30%.**
- **Posterior side: 15%.**
- **Anterior face: 1%.**

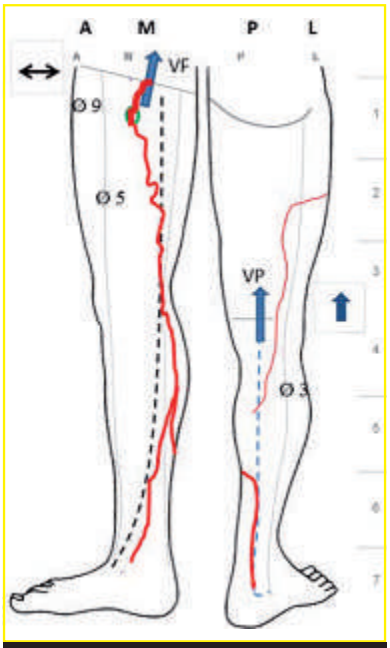

Fig. 14: Shema of recurrence SFJ to AASV.

Fig. 15: Clinical aspect of recurrence SFJ to AASV.

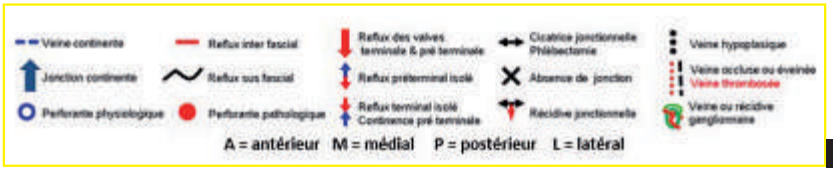

Fig. 13: Example of mapping codes.

Aucun article ou résumé dans cette revue ne peut être reproduit sous forme d'imprimé, photocopie, microfilm ou par tout autre procédé sans l'autorisation expresse des auteurs et de l'éditeur. Editions Phlébologiques Françaises
No article or abstract in this journal may be reproduced in the form of print, photocopy, microfilm or any other means without the express permission of authors and the editor. Editions Phlébologiques Françaises

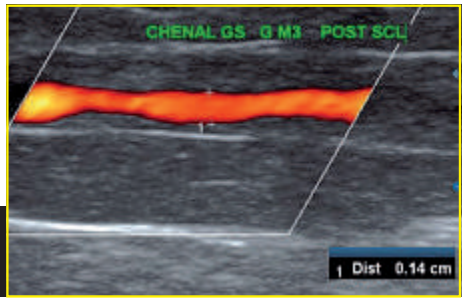

Fig. 16: Longitudinal section: GSV recanalization one year later chemical ablation.

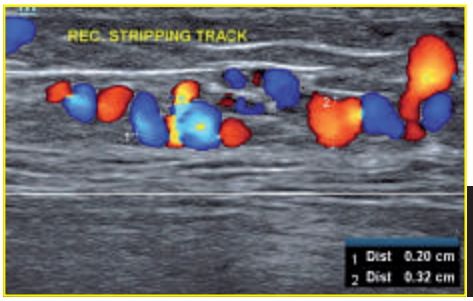

Fig. 17: Longitudinal section: Recurrence by neovascularization in the GSV stripping channel.

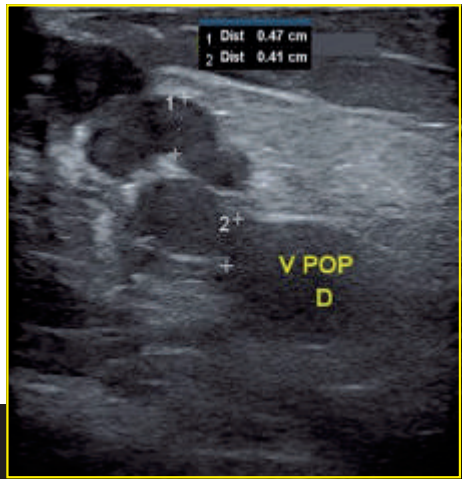

Fig. 18: Cross section right Lower limb: Recurrence SPJ.

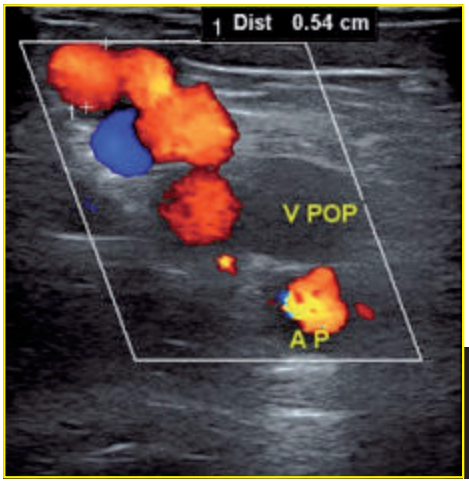

Fig. 19: Cross section right Lower limb: SPJ recurrence, visualization of popliteal reflux by color Doppler.

Finally, the existence in 95% of cases of a cranial extension of SSV [18] and the possibility of a perforator in the popliteal fossa (PFP) adds to the complexity of the examination of this region, already difficult in its native state.

However, we will find characteristics similar to those of the SFJ junctional recurrences.

Incomplete resection, due to technical inadequacy, of the sapheno-popliteal junction

The higher this junction is located and the deeper the implantation, the more difficult the technical gesture of a high ligature of the junction is and the risk of incomplete procedure increased.

It may be a stump and residues of this junction may be more or less visible (terminal valve, intervalvular segment). The diameter of this junctional stump must be indicated; the hemodynamic study will specify the refluxes.

It may be a junction left in place, due to difficult conditions, as seen above; the cranial extension and sometimes the preterminal valve will be visible. The usual data, echo-anatomical and hemodynamic will be provided.

Voluntarily preserved junctions:

In the context of endovenous ablative procedures, but also:

A common junction or trunk with medial gastrocnemius veins (MGVs) that results in a ligation that has not been made flush with the popliteal vein to preserve the MGVs.

Hemodynamics, diameters and drainage, in particular the condition of the trunk of the small saphenous vein (SSV), present, patent or occluded or recanalized, will be recorded, as well as the length of any recanalization.

Pathological popliteal venous network (PPVN) connected to the popliteal vein

Probably, here too, resulting from the neovascularization and/or dilation of pre-existing venules, with the difference that the equivalent of the inguinal LNVN is not found in the popliteal fossa.

Hemodynamics, size and drainage will be studied and documented. In particular, care should be taken to check the reality of junctional recurrence by visualizing a reflux passing from the popliteal vein into the recurrence. **(Fig. 18 et 19).**

Aucun article ou résumé dans cette revue ne peut être reproduit sous forme d'imprimé, photocopie, microfilm ou par tout autre procédé sans l'autorisation expresse des auteurs et de l'éditeur. Editions Phlébologiques Françaises
No article or abstract in this journal may be reproduced in the form of print, photocopy, microfilm or any other means without the express permission of authors and the editor. Editions Phlébologiques Françaises

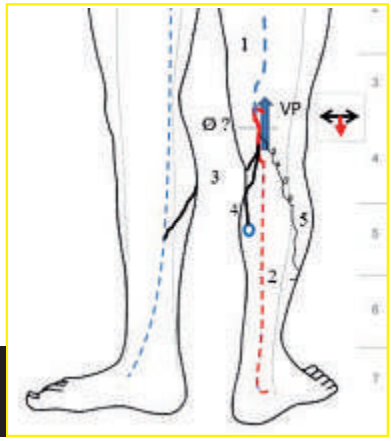

Fig. 20: Diagram: Recurrence SPJ mapping of main drainage channels.

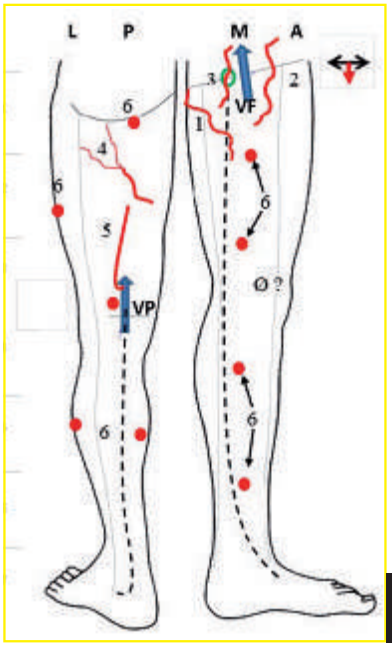

Fig. 21: Diagram: Non-junctional leak points: Mapping.

Drainage of popliteal junctional recurrences (Fig. 20)

It is the same principle as for inguinal junctional recurrences, reflux can drain:

In the interfascial (saphenous) compartment. It may be:

- **Residual cranial extension [1].**
- **The trunk or segment of the residual trunk of the small saphenous vein, possibly recanalized after an endovenous technique [2].**
- **A dystrophic plexiform network consisting of small caliber incompetent veins in the interfascial compartment [2].**
- **A flowing channel refluxing in the path of the stripped saphenous vein [2].**

In the supra-fascial compartment. It may:

- **Intersaphenous communicators [3].**
- **Residual tributaries, initially incompetent or not [5].**

Finally, reflux can drain into a perforator, particularly medial gastrocnemius [4].

Non-junctional recurrences and their drainage

The origins of reflux can be: (see the numbers on the diagram) (Fig. 21)

- **Incompetent pelvic-perineal veins [1], for which will result in a positive Vasalva manoeuvre.**
- **Subcutaneous abdominal veins [2] where the Vasalva is negative. An GVN not connected to the femoral vein [3], (Fig. 22) may be varicose veins of the LNVN (Fig. 22 bis).**

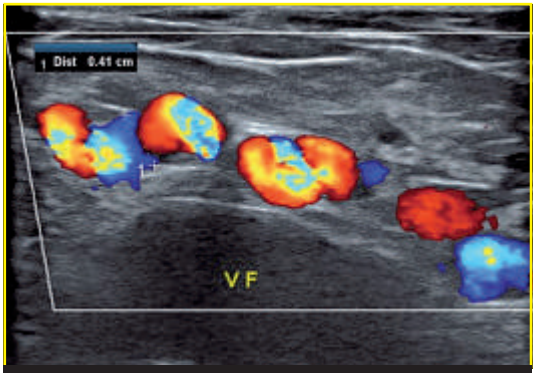

Fig. 22: Longitudinal section Left lower limb: GVN not connected to the femoral vein.

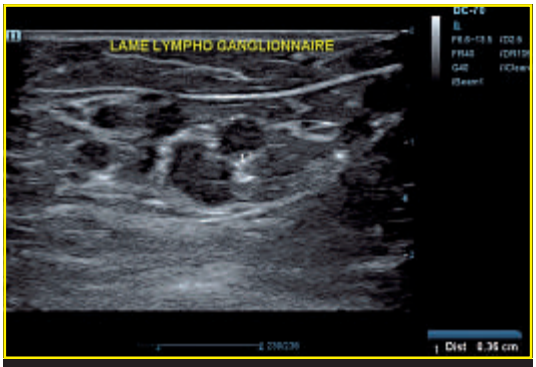

Fig. 22bis: Cross section Left lower limb : Lymph Node Varicose Network.

Aucun article ou résumé dans cette revue ne peut être reproduit sous forme d'imprimé, photocopie, microfilm ou par tout autre procédé sans l'autorisation expresse des auteurs et de l'éditeur. Editions Phlébologiques Françaises
No article or abstract in this journal may be reproduced in the form of print, photocopy, microfilm or any other means without the express permission of authors and the editor. Editions Phlébologiques Françaises

- Incompetent posterior parietal thigh afferences [4].
- The cranial extension of the SSV or a Giacomini vein [5].
- The entire perforator system [19, 20], in particular femoral canal perforators [6], gluteal perforators, lateral thigh perforators, popliteal fossa and leg perforators. The presence of incompetent perforators in the context of recurrences, after surgery, is much more frequent than in the initial assessments 10.

Varicose recurrences visible especially at the root of lower limbs may be the clinical manifestation (including in absence of pelvic congestion syndrome) of chronic pelvic venous insufficiency. The importance of these varicose veins, their resistance to the treatment by foam sclerotherapy or their early recurrence, must lead to a DUS examination of the veins of the pelvic area, first stage of the diagnosis and the possible treatment of the chronic pelvic venous insufficiency (see Chapter 5 in Ultrasons et Phlébologie – Editions phlébologiques Françaises).

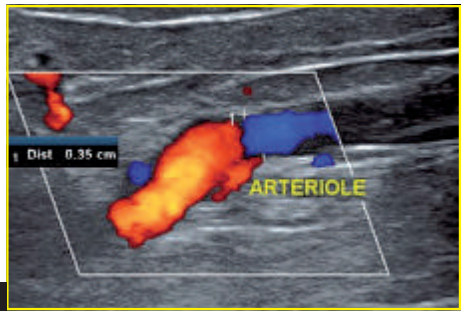

Fig. 23: Femoral perforator.

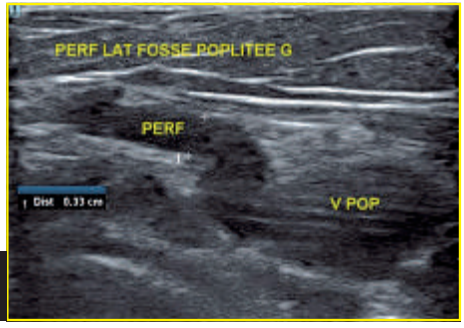

Fig. 24: Cross section left Lower limb: lateral perforator popliteal fossa.

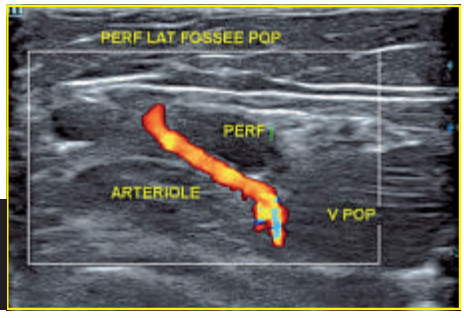

Fig. 25: Cross section left Lower limb: lateral perforator popliteal fossa Color doppler: visualization of the arteriole.

For perforators, the precise location must be indicated according to the nomenclature [19], the size will be specified at the level of the perforation of the muscle fascia as well as the drainage, either in a residual saphenous trunk or in supra-fascial (subcutaneous) tributaries, whose size must also be measured **(Fig. 23)**.

It is often difficult to distinguish ultrasonographically between a lateral junctional recurrence of the SPJ and a perforator in the popliteal fossa. In addition to the fact that the perforator of the popliteal fossa has a very constant anatomical situation, in our experience the junctional recurrences are never accompanied by a satellite arteriole, whereas the perforators (not only those of the popliteal fossa) are always so **(Fig. 24 et 25)**.

Varicosis of the sciatic nerve may also sometimes be involved [21].

Non-junctional refluxes can be associated with each other or with junctional reflux.

The drainage of non-junctional recurrences will be very similar to that of Junctional recurrences:

- A residual trunk or segment of trunk of the great saphenous vein or the anterior (or posterior) accessory saphenous vein of the thigh or the small saphenous vein.
- The cranial extension of the SSV or Giacomini vein.
- Residual tributaries, initially incompetent or not.
- A dystrophic plexiform network consisting of small caliber incompetent veins in the interfascial compartment due to neovascularization phenomena.
- A flowing channel refluxing in the path of the stripped saphenous vein.
- An intersaphenous communicator.

Examination of the deep venous network

This is a completely classic examination, as practiced in an initial assessment of superficial venous insufficiency [22].

Deep venous insufficiency is a risk factor for varicose vein recurrence.

A priori, one could imagine that there would be no change compared to the preoperative assessment, if available, unless, of course, an episode of deep vein thrombosis has occurred since the last assessment.

Therefrom the importance, as always, of the interrogation. However, it should be remembered that studies involving systematic short-term echodoppler examination in post-operative follow-up have shown that asymptomatic deep vein thrombosis is not exceptional. They can sometimes leave a parietal and/or valvular sequelae, with reflux, which requires a systematic repeat of the examination.

Aucun article ou résumé dans cette revue ne peut être reproduit sous forme d'imprimé, photocopie, microfilm ou par tout autre procédé sans l'autorisation expresse des auteurs et de l'éditeur. Editions Phlébologiques Françaises
No article or abstract in this journal may be reproduced in the form of print, photocopy, microfilm or any other means without the express permission of authors and the editor. Editions Phlébologiques Françaises

The examination focuses on common femoral veins, femoral veins and popliteal veins. It is not superfluous to add a check of the medial gastrocnemius veins.

In case of evidence of reflux, or even obstructive phenomena, in the sites studied, it will be necessary to extend the examination step by step, looking for anatomical and/or hemodynamic abnormalities, generally post-thrombotic, exceptionally primary.

Some remarks and practical advice for a well conducted DUS assessment of varicose recurrences

Post-operative Doppler follow-up

It must be distinguished, as perfectly described by De Maeseneer and the group of experts in the IUP consensus document [12], from the PREVAIT DUS assessment, or from an assessment carried out simply in the presence of symptoms suggestive of recurrence.

The ideal is to set up follow-up following the recommendations:

1. immediate,

- **1 to 4 weeks after the operative treatment in one step (surgical or thermal ablation), to check its effectiveness and the absence of venous thromboembolic complications;**
- **or 4 to 8 weeks later, in the case of multiple treatments (chemical ablation, combined treatments, CHIVA, etc.).**

2. subsequent,

- **in the short term (1 year) to assess the probability of recurrence (recanalisation, detection of new refluxes)**
- **in the medium term (2 to 3 years) to monitor developments,**
- **in the long term (more than 5 years), this period being considered sufficient for the development of a possible clinical recurrence.**

The echodoppler assessment of recurrences

It is generally required in the presence of signs (telangiectasia, varicose veins, trophic disorders) or, more rarely, in the reappearance of symptoms of venous insufficiency (pain, heaviness, sensation of swelling, itching, etc.).

This examination is therefore diagnostic in nature, but it should not be forgotten that it will play an essential role in determining the appropriate course of action (operating decision, choice of technique, strategy). Therefore, it is imperative to establish an accurate mapping. No one will claim to do exhaustive examination (recurrences are often complex, especially after surgery) but the decisive elements must certainly not be overlooked.

The first step in the assessment is the medical questioning,

with the aim of specifying the operative history (obviously easier if documents are available, preoperative assessment report, operative report and the early post-operative assessment mentioned in relation to follow-up).

The interview will look for possible episodes of intercurrent venous thromboembolic disease and focus on describing the symptoms.

Fig. 26: Clinical examination: visualization of recurrences and scars.

Clinical examination is essential, on the patient standing up,

in the position of the echodoppler examination, and looks for manifestations of chronic venous disease, allowing the patient to be classified under the CEAP C (C0 to C6). These signs are reported on the map. In addition, it will be necessary to look for the presence of significant scars, in particular to locate the previous operating areas, if no document is available; this can be done, if necessary, on the lying patient **(Fig. 26).**

The echodoppler examination itself

Unlike the initial examination, where the saphenous veins are well systematized (even if surprises are always possible), in the case of recurrence, it must be considered that "everything is possible".

The notion of "exploration" takes on its full meaning here, during which it will be necessary to track down recurrence, refluxes, sometimes difficult to detect, and the drainage of these refluxes.

Aucun article ou résumé dans cette revue ne peut être reproduit sous forme d'imprimé, photocopie, microfilm ou par tout autre procédé sans l'autorisation expresse des auteurs et de l'éditeur. Editions Phlébologiques Françaises
No article or abstract in this journal may be reproduced in the form of print, photocopy, microfilm or any other means without the express permission of authors and the editor. Editions Phlébologiques Françaises

A good equipment [9] [23], well adjusted, is essential for these assessments where we will often explore from the most superficial to the deepest network. It is necessary to have a high frequency linear probe (7.5 - 12 MHz) or, even better, a very high frequency probe (14 to 20 MHz); a microconvex probe from 5 to 10 MHz will be useful in obese patients and to explore the deep network and perforators of the lower limbs; finally a convex low frequency probe for the ilio-cave network, if it seems necessary to extend the deep venous examination to this level.

In the context of recurrence, physiopathological determinism is complex and the cohabitation of the 2 theories, descending and ascending, in the development of varicose veins is likely. A careful study of the supra-fascial varicose veins, often very superficial, is necessary. It therefore requires a very high frequency probe; good settings (see chapter on technique) in B mode, pulsed Doppler and color will greatly facilitate the task. The simple use of a thick layer of gel is sufficient to improve the quality of the images and signals obtained in the first centimetre.

The deep venous examination can be performed at the beginning, during or at the end of the check-up. It will be adapted according to the knowledge of previous assessments, possible intercurrent events and discoveries made during the examination.

Concerning the superficial exploration, care should be taken to collect and transfer to the report and mapping all relevant informations for the development and proposal to the patient of appropriate management [6, 12, 23].

Leak points, refluxing networks and their drainage, either superficial or by re-entry perforators, will be precisely located. The different calibres will be indicated, knowing that during the possible therapeutic procedure (chemical ablation frequently) the practitioner who operates will take precise measures to adapt the treatment applied (concentration of the sclerosing foam for example).

It is often advisable to start the exploration with the operated junction zones. In our personal practice we prefer to start from the clinical manifestation of recurrence (usually visible varicose veins, sometimes the location of symptoms) and go back up the track to the original reflux.

Indeed, in the presence of varicose veins after operative treatment (PREVAIT), knowledge of the technique used, documented (operating report), or supposed (interrogation), and the visualization of a scar (scar of inguinal surgical approach; scar of popliteal surgical approach, or other) will be a precious help. Obviously, a DUS assessment of surgical follow-up, as recommended by the IUP consensus [12], will greatly facilitate the task.

But in "real life", you often have to manage with few elements. The location of visible varicose veins is an indication, but it can be misleading.

Fig. 27: Right medial leg recurrence.

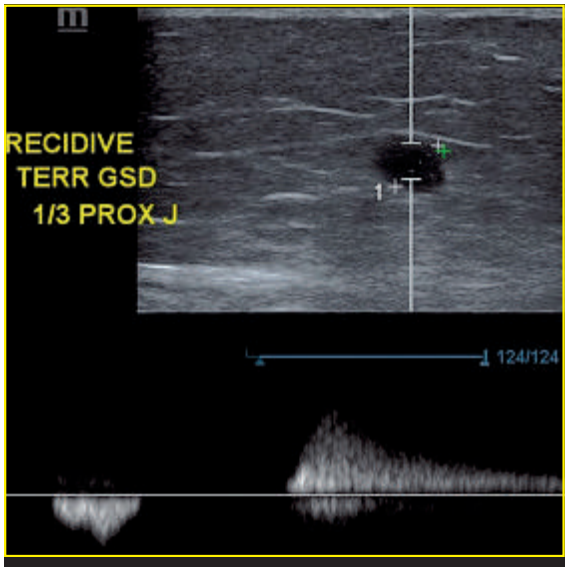

Fig. 28: Cross section: right medial leg recurrence. Ultrasound pict.

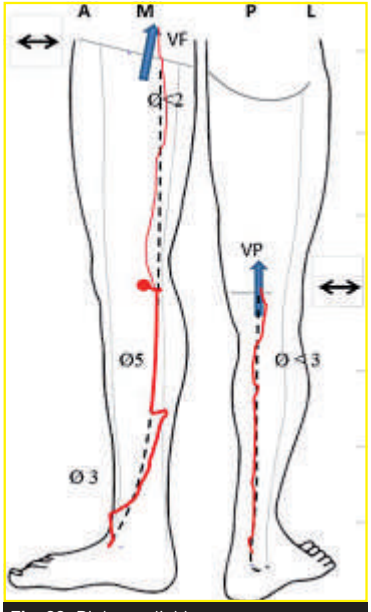

Fig. 29: Right medial leg recurrence. Mapping scheme.

Aucun article ou résumé dans cette revue ne peut être reproduit sous forme d'imprimé, photocopie, microfilm ou par tout autre procédé sans l'autorisation expresse des auteurs et de l'éditeur. Editions Phlébologiques Françaises
No article or abstract in this journal may be reproduced in the form of print, photocopy, microfilm or any other means without the express permission of authors and the editor. Editions Phlébologiques Françaises

Thus, a varicose vein on the medial thigh surface may lead us to a reflux of pelvic-perineal origin (which will not be ignored) or to a junctional or non-junctional reflux, in the inguinal area, or to an unexpected gluteal perforator, or to be a tributary of an anterior accessory saphenous vein of the thigh, etc.

A leg recurrence may find its source of reflux in a superior paratibial perforator, without recurrence at the femoral level, or at any other level **(Fig. 27 to 29).**

Starting from the clinical expression of the disease allows to systematically link it to source(s) of reflux. However, it will be necessary to check the junction areas operated on if they are not directly involved in recurrence in the first part of the examination.

In a second step, with a more medium- or long-term follow-up objective, assessing the risk of clinical recurrence, the clinically silent operated areas will be explored in search of newly emerging incompetent veins.

Finally, the operated areas must be investigated as a priority, but it is obviously necessary to control the non-operated areas, because of the always possible evolution of varicose vein disease.

We propose below a table **(Table 1),** which may be somewhat boring, but which may be useful, especially for our junior colleagues, and also an example of a diagnostic tree for visible thigh recurrences **(Table 2).**

We can thus define 4 parts

- **operated areas with clinical manifestations.**
- **clinically silent operated areas.**
- **non-operated areas with clinical manifestations.**
- **clinically silent non-operated areas.**

This examination can therefore be quite long; it is recommended to be cautious with patients who have difficulty with prolonged standing, some examination times

Table 1:

OTHER ELEMENTS	US DATA	HEMODYNAMICS DATA	DIAGNOSTIC	TYPE	MAIN CAUSE	PROBABLE TECHNIQUE
scar of inguinal surg. approach SISA	**Saphenofemoral junction (SFJ)** in place. Trunk in place	Junctional reflux Color Doppler	REVAS GSV **Junctional (J.)**	**Residual Recurrence (Res. R.)**	**Technical error** +++	**High Ligation (HL)** +/- stripping
SISA	SFJ in place Stripped trunk	**Junctional recurrence J.R.**	REVAS GSV J.	Res. R. + **Real R.**	Technical error	HL + stripping
SISA	SFJ residues	Reflux DVN to SVN	REVAS GSV J.	Real R.	Technical error	HL +/- stripping
SISA	**GVN** connected	Reflux DVN to SVN	REVAS GSV J.	Real R.	Neovascularization	HL +/- stripping
NO SISA	SFJ in place Occluded trunk	J.R. : drainage reflux to AASV	PREVAIT GSV J. **Endovenous ablation (EVA)**	Real R.	Technical error or technical deficiency	EVA
NO SISA	SFJ in place Recanalized trunk (Caliber and length)	J.R. +/-	PREVAIT GSV J. EVA	Real R.	Technical error or technical deficiency	EVA
scar of poplit. surg.approach SPSA	**Saphenopopliteal Junction (SPJ)** in place Trunk in place	J.R.	REVAS SSV J.	Res. R.	Technical error or Tactical choice	HL or **Low Ligation (LL)** upstream of the **medial gastrocnemians (MG)** +/- stripping
SPSA	SPJ in place Stripped trunk	J.R. ; drainage reflux to tributaries	REVAS SSVS J.	Res. R. + Real R	Technical error	HL or LL uspstream MG +/- stripping
SPSA	SPJ residues	Reflux DVN to SVN drainage to tributaries	REVAS PVS J.	Real R.	Technical error	HL +/- stripping
SPSA	**PPVN** connected	Reflux DVN to SVN	REVAS SSV J.	Real R.	Neovascularization	HL +/- stripping
SISA and / or SPSA	GVN and PPVN not connected	**Vasalva +** reflux of pelvic-perineal origin or femoral tributary	REVAS not J. GSV or SSV	Real R. +/- Res. R.	Neovascularization Or Technical error ?	HL +/- stripping
SISA and / or SPSA	GVN and PPVN not connected	**Vasalva -** reflux of abdominal subcut. v. origin or SVN	REVAS not J. GSV or SSV	Real R. +/- Res. R.	Neovascularization Or Technical error ?	HL +/- stripping
SISA and / or SPSA visible or NOT	perforating veins, all types, all locations	Reflux DVN to SVN arterioles visible close to the perforator (Color Doppler)	REVAS or PREVAIT not J.	Real R. +/- Res. R. +/- New **varicose veins (VV)** in another territory	Progression of disease other causes intricated	All types
SISA and / or SPSA visible or NOT	VV not connected to **deep venous network (DVN)**	Reflux in **SVN (superficial venous network)**	REVAS or PREVAIT not J.	Real R. +/- Res. R. +/- New VV in another territory	Progression of disease other causes intricated	All types

Aucun article ou résumé dans cette revue ne peut être reproduit sous forme d'imprimé, photocopie, microfilm ou par tout autre procédé sans l'autorisation expresse des auteurs et de l'éditeur. Editions Phlébologiques Françaises
No article or abstract in this journal may be reproduced in the form of print, photocopy, microfilm or any other means without the express permission of authors and the editor. Editions Phlébologiques Françaises

Table 2:

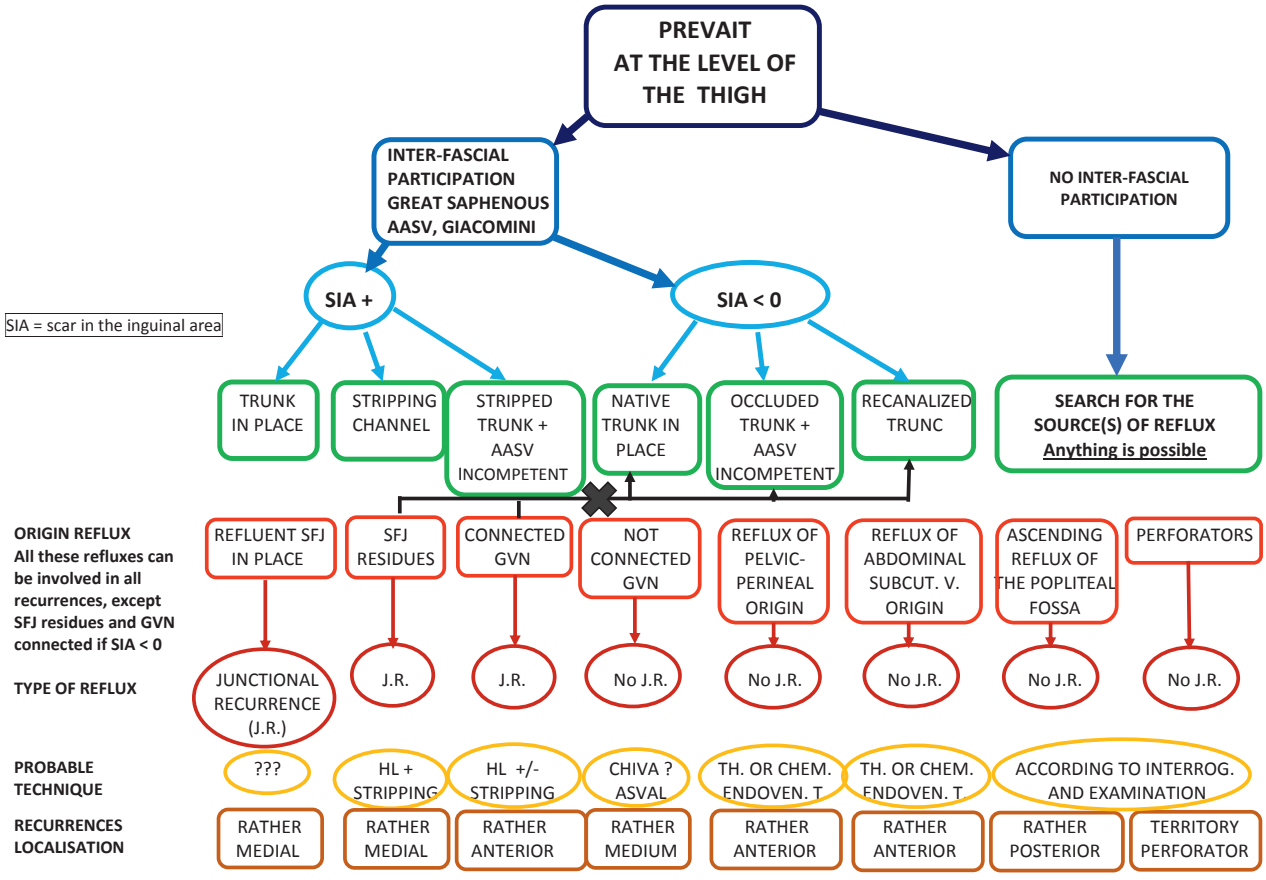

may be performed in a sitting, hanging legs, or lying down position.

This is obviously not a waste of time because the assessment will contribute both to the management of recurrence and to subsequent follow-up.

Conclusion

Currently, several international recommendations are in favour of thermal ablation for the non-conservative treatment of saphenous insufficiency [24, 25].

However, several recent randomized clinical trials [26, 27, 28, 29] show that the frequency of recurrences at 5 years of age differs little between open surgery (high ligation of junction and stripping) and endovenous thermal treatments.

Chemical ablation also gives similar clinical results at 5 years, but with a higher recanalization rate.

O'Donnell, in his review of the literature published in 2016 [13], concludes that there is no difference in the incidence of recurrences between endovenous ablations and high ligation of junction and stripping, but that the causes are different, which has important implications for treatment.

Of course, everyone will argue that the operator's skill and choice of technique used (for example: conventional surgery under general anaesthesia versus tumescent local anaesthesia, or the type of technique and fibre used) should be taken into account.

used and the amount of energy delivered during thermal ablation, as well as the making of sclerosing foam and injection technique) play an essential role in the incidence of PREVAIT.

Aucun article ou résumé dans cette revue ne peut être reproduit sous forme d'imprimé, photocopie, microfilm ou par tout autre procédé sans l'autorisation expresse des auteurs et de l'éditeur. Editions Phlébologiques Françaises
No article or abstract in this journal may be reproduced in the form of print, photocopy, microfilm or any other means without the express permission of authors and the editor. Editions Phlébologiques Françaises

It is nevertheless true that post-operative varicose vein recurrences will remain a daily problem for vascular physicians for a long time to come.

The recommendations of the European Society of Vascular Surgery [30], joining the European recommendations for sclerotherapy [8] and those issued under the auspices of the European Venous Forum and the IPU [31], state:

- Doppler ultrasound is recommended in the recurrence assessment
- Ultrasound guided Foam sclerotherapy, phlebectomy and thermal ablation should be considered as the treatment of recurrences.
- Extensive redo surgery is not recommended.

Duplex ultrasound assessment in presence of varicose veins after operative treatment (PREVAIT) is therefore the essential preamble to the development of the management strategy and its implementation. The diagnostic and pre-therapeutic role requires a written report and precise mapping.

In addition, each time this therapeutic implementation is carried out, it will necessarily be assisted by the Doppler ultrasound. It is not uncommon for these reviews to add new data to the report and complete it. Sometimes, during the immediate post-injection control in a ultrasound guided foam sclerotherapy procedure, the foam acts as a contrast agent and highlights an undetected leak point.

All in all, this examination, which is certainly a bit time-consuming, is often exciting, a real hunt for recurrence, essential to the effectiveness of treatment for these patients, who are still too often left behind.

Bibliographie

[1] Perrin M., Guex JJ., Ruckley CV., et al. Recurrent varices after surgery (REVAS), a consensus document. Cardiovasc Surg 2000; 8: 233-45.

[2] Eklof B., Perrin M., Delis KT., et al. Updated terminology of chronic venous disorders: the VEIN-TERM transatlantic interdisciplinary consensus document. J Vasc Surg 2009; 49: 498-501.

[3] Van Rij AM., Jones GT., Hill GB., et al. Neovascularization and recurrent varicose veins: more histologic and ultrasound evidence. J Vasc Surg 2004; 40: 296-302.

[4] Perrin M., Labropoulos N., Leon LR. Presentation of the patient with recurrent varices after surgery (REVAS). J Vasc Surg 2006; 43: 27-34.

[5] Perrin M. Presence of varices after operative treatment: a review. Phlebolymphology 2014; 21, 3: 158-68.

[6] Auvert J-F., Moraglia L. et al. Quality standards for ultrasound assessment of the superficial venous system of the lower limbs. Journal des Maladies Vasculaires 2014; 39 : 26-46.

[7] De Maeseneer MG., Vandenbroeck CP., et al. Accuracy of duplex evaluation one year after varicose vein surgery to predict recurrence at the saphenofemoral junction after five years. Eur J Vasc Endovasc Surg 2005; 29: 308-12.

[8] Rabe E., et al. European guidelines for sclerotherapy in chronic venous disorders. Phlebology 2013; 28: 308-19.

[9] Auvert J-F., Moraglia L. Exploration ultrasonore de l'insuffisance veineuse superficielle In La Maladie Veineuse Chronique. Elsevier Masson 2015: 55-72.

[10] Van Rij AM. A prospective study of the fate of venous leg perforators after varicose vein surgery. J Vasc Surg 2005; 42: 1156-62.

[11] Nelzen O. Reconsidering the endovenous revolution. BJS 2016; 103: 939-40.

[12] De Maeseneer M., Pichot O., et al. Duplex Ultrasound Investigation of the Veins of the Lower Limb after Treatment for Varicose Veins – UIP Consensus document Eur J Vasc Endovasc Surg 2011; 42: 89-102.

[13] O'Donnell TF., et al. Recurrence of varicose veins after endovenous ablation of the great saphenous vein in randomized trials. J Vasc Surg 2016; 4: 97-105.

[14] Stücker M., Netz K., Breuckmann F., Altmeyer P., Mumme A. Histomorphologic classification of recurrent saphenofemoral reflux. J Vasc Surg 2004; 39: 816-21.

[15] Lemasle P. Anatomie et exploration dans Elsevier Masson. Traité de médecine vasculaire 2011; 2: 129-64.

[16] Munasinghe A., Smith C., et al. Strip-track revascularization after stripping of the great saphenous vein. Br J Surg 2007; 94: 840-3.

[17] Lemasle P., Uhl JF., et al. Confrontation écho-chirurgicale de la terminaison de la saphène externe dans le cadre de la chirurgie d'exérèse. Résultats préliminaires. Phlébologie 1995; 48, 3: 321-7.

Aucun article ou résumé dans cette revue ne peut être reproduit sous forme d'imprimé, photocopie, microfilm ou par tout autre procédé sans l'autorisation expresse des auteurs et de l'éditeur. Editions Phlébologiques Françaises
No article or abstract in this journal may be reproduced in the form of print, photocopy, microfilm or any other means without the express permission of authors and the editor. Editions Phlébologiques Françaises

[18] Georgiev M., Myers KA., Belcaro G. The thigh extension of the lesser saphenous vein: from Giacomini's observations to ultrasound scan imaging. J Vasc Surg 2003; 37: 558-63.

[19] Cavezzi A., Labropoulos N., Partsch H., Ricci S., Caggiati A., Myers K., et al. Duplex ultrasound investigation of the veins in chronic venous disease of the lower limbs e UIP consensus document. Part II. Anatomy. Eur J Vasc Endovasc Surg 2006; 31: 288-99.

[20] Caggiati A., Bergan JJ., Gloviczki P., Jantet G., Wendell-Smith CP., Partsch H. Nomenclature of the veins of the lower limbs: an international interdisciplinary consensus statement. J Vasc Surg 2002; 36: 416-22.

[21] Lemasle P., Uhl JF., Lefebvre-Vilardebo M., Gillot C., Baud JM., Vin F. Veine du nerf sciatique et Maladie Variqueuse: Aspects écho-anatomiques et hémodynamiques. Phlébologie 2001; 54, 2: 219-28.

[22] Gillet JL. Duplex ultrasonography protocol for investigation of patients presenting with recurrent varicose veins after surgery. Phlebolymphology 2009; 13(3): 295-8.

[23] Malgor RD., Labropoulos N. Diagnosis and follow-up of varicose veins with duplex ultrasound: how and why ? Phlebology, 2012; 27 Suppl 1: 10-5.

[24] Gloviczki P., Comerota AJ., Dalsing MC., et al. The care of patients with varicose veins and associated chronic venous diseases: clinical practice guidelines of the Society for Vascular Surgery and the American Venous Forum. J Vasc Surg 2011; 53: 2S-48S.

[25] National Institute for Health and Care Excellence (UK). Varicose veins in the legs: the diagnosis and management of varicose veins. London: NICE Clinical Guideline 2013.

[26] Rasmussen L., Lawaetz M., Bjoern L., et al. Randomized clinical trial comparing endovenous laser ablation and stripping of the great saphenous vein with clinical and duplex outcome after 5 years. J Vasc Surg 2013; 58: 421-6.

[27] Brittenden J., Cotton SC., Elders A., et al. A Randomized Trial Comparing Treatments for Varicose Veins. N Engl J Med 2014; 371: 1218-27.

[28] Rass K., Frings N., Glowacki P., et al. Same site recurrence is more frequent after endovenous laser ablation compared with high ligation and stripping of the great saphenous vein: 5 years Results of a Randomized Clinical Trial (RELACS Study). Eur J Vasc Endovasc Surg 2015; 50: 648-56.

[29] Van der Velden SK, Biemans AA, De MaeseneerMG, et al. Five-year results of a randomized clinical trial of conventional surgery, endovenous laser ablation and ultrasound-guided foam sclerotherapy in patients with great saphenous varicose veins. Br J Surg 2015; 102: 1184-94.

[30] Wittens C., Davies AH., Baekgaard N., et al. Editor's choice – management of chronic venous disease: clinical practice guidelines of the european society for vascular surgery (ESVS). Eur J Vasc Endovasc Surg 2015; 49: 678-737.

[31] Nicolaides A., Kakkos S., Eklof B., Perrin M., et al. Management of chronic venous disorders of the lower limbs – guidelines according to scientific evidence. Int. Angiol. 2014; 33: 87-208.