

Chapter 5

Contribution of ultrasonic explorations in woman's pelvic venous insufficiency

Philippe Lemasle¹, Milka Greiner²

Abstract

Chronic pelvic venous insufficiency is a common pathology, but it is overlooked and underdiagnosed as it sits on the edge of two medical specialties: gynecology and vascular medicine. Its most frequent expression is pelvic varicose veins and pelvic venous reflux towards the lower limbs.

When symptomatic, it is expressed in the pelvic area as a sometimes disabling pelvic congestion syndrome and / or in the lower limbs level, by participating in supplying varicose veins. Consequently, the isolated treatment of lower limb varices without treating pelvic leaks may cause early recurrences.

The ultrasound exploration allows the positive diagnosis of pelvic venous involvement and the classification by pathophysiological types which is a key step before any therapy.

The echo-Doppler is also essential for the diagnosis of superficial points of pelvic venous leaks supplying lower limb varicose veins. In most cases of symptomatic patients, the ultrasound exploration provides sufficient arguments to evaluate the relevance of the pelvic level venous treatment.

It leads to additional imaging techniques, if necessary, or directly to hyper selective pelvic venography. This last investigation achieves an accurate mapping of varicose veins and pelvic venous reflux.

Keywords: pelvic varicose veins, pelvic varices classification, ultrasound diagnosis, pelvic leak points, left renal vein compression, iliac vein compression.

Résumé

L'insuffisance veineuse pelvienne est une pathologie courante, mais mal connue et sous-diagnostiquée, car elle se situe à la frontière de deux spécialités médicales : la gynécologie médicale et la médecine vasculaire.

Elle s'exprime le plus souvent par la présence de varices pelviennes et/ou des reflux veineux pelviens vers les membres inférieurs.

Lorsqu'elle est symptomatique, elle peut s'exprimer à l'étage pelvien, par un syndrome de congestion pelvienne et/ou à l'étage des membres inférieurs, en participant à l'alimentation de varices. Dans ce contexte, le traitement isolé des varices des membres inférieurs sans suppression des points de fuite pelviens peut être la source de récurrences précoces. Les explorations ultrasonores permettent le diagnostic positif des varices pelviennes et leur classification selon des types physiopathologiques, élément clé dans la décision thérapeutique.

L'écho-doppler est indispensable dans le diagnostic et la caractérisation des points de fuite pelviens systématisés superficiels qui alimentent les varices des membres inférieurs.

Chez la majorité des patientes symptomatiques, les explorations ultrasonores fournissent des arguments suffisants pour évaluer la pertinence d'un traitement veineux à l'étage pelvien.

Elles peuvent conduire à demander des imageries de coupe complémentaires, ou si nécessaire, une phlébographie pelvienne hyper-sélective. Ce dernier examen est le seul capable d'établir une cartographie précise des varices et des reflux pelviens, mais doit rester un examen pré-thérapeutique.

Mots clés : varicose pelvienne, classification des varices pelviennes, diagnostic ultrasonore, points de fuite d'origine pelvienne, compression de la veine rénale gauche, compression de la veine iliaque gauche.

1 Cabinet Nouvelle France, 15 rue Pottier, 78150 Le Chesnay, France.

2 Hôpital américain de Paris, département de pathologie vasculaire, 63 Bd Victor Hugo, 92200 Neuilly sur Seine, France.

Introduction

Chronic pelvic venous insufficiency (CPVI) includes all situations, congenital or acquired, that result in a dysfunction of the pelvic venous system.

Varicose veins and pelvic refluxes are the most common pathological expression.

Dysplasias and deep pelvic venous malformations are much rarer.

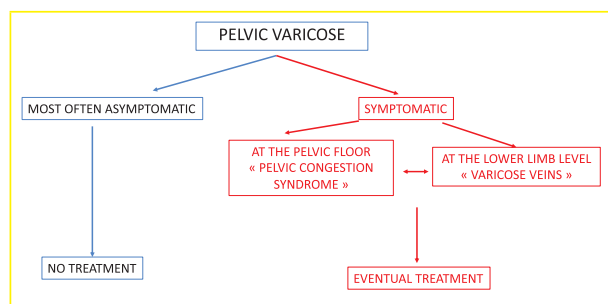
Pelvic varicose veins are very common, in multiparous women, but in the vast majority of cases they are asymptomatic.

When they are symptomatic, they can be responsible for symptoms at two levels:

- at the pelvic level, in the form of pelvic congestion syndrome [1, 2, 3]
- and / or at the lower limb (LL) level by feeding varicose veins [4, 5, 6, 7, 8, 9].

Management of pelvic varicose veins should only be reserved for symptomatic forms, regardless of the level (Table II).

Table I: Clinical manifestations of pelvic varicose veins.



Semantic prerequisites

The definition of pelvic varices includes all pelvic venous dilations, primitive or secondary, related to altered venous return from an abdominal-pelvic area [3].

Varicocele is only a particular form of pelvic varices related to the dilation of the pampiniform plexus (or pèri-ovarian plexus).

Anatomical and hemodynamic prerequisites (Table II).

Pelvic veins drain into 3 main collection systems: internal iliac veins, gonadal veins and rectal veins [3, 9, 10, 11].

Common and internal iliac veins are generally valveless, but parietal and visceral internal iliac tributaries are valved.

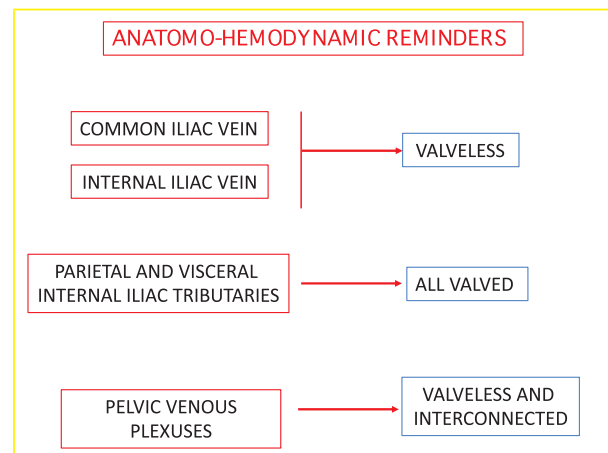
This fact is widely demonstrated by hyper-selective pelvic phlebography.

Visceral tributaries originate from downstream venous plexuses and are largely interconnected.

Pelvic venous anatomy should therefore be considered, not as independent veins draining a specific territory, but as a multiconnected pelvic venous network, itself connected to other networks, in particular to the network of lower limbs.

This anatomical distribution enables to understand how pelvic venous reflux, whatever its origin, can impact any ipsilateral or contralateral pelvic area and/or feed LL varicose veins: a reflux of a left gonadal vein can feed, for example, right perineal varicose veins.

Table II: Anato-hemodynamic diagram of pelvic venous drainage.



Classification of varicose veins and pelvic reflux

In 2005, Milka Greiner [3] proposed a classification based on pathophysiological criteria derived from pelvic phlebographies.

Contribution of ultrasonic explorations in woman's pelvic venous insufficiency.

Three types of venous anomalies (varicose veins and/or venous reflux disease) have been differentiated (**Table III**).

Table III: Classification of pelvic reflux disease and pelvic varices (M. Greiner).

| |
|--|
| <p>Type 1: REFLUX PATHOLOGY : SECONDARY TO A VALVE OR PARIETAL ANOMALY: without pelvic or supra pelvic obstruction of the venous flow.</p> <ul style="list-style-type: none"> - <i>Valve disease:</i> congenital or acquired valve incompetence or lack of valves. - <i>Pelvic venous dilation:</i> congenital or acquired in any sector. - <i>Venous malformations</i> <p>Type 2 VENOUS SUBSTITUTION PATHOLOGY SECONDARY TO A TRUNCAL OBSTRUCTION: secondary to an obstruction of a drainage vein</p> <p>SUPRA-PELVIC OBSTRUCTION:</p> <ul style="list-style-type: none"> - Abnormalities of left renal venous return: Primary= Nutcracker syndromes ; Secondary= Thrombosis - Inferior Vena Cava diseases: Primary= Congenital anomalies ; Secondary= Extrinsic compression, Thrombosis <p>PELVIC OBSTRUCTION: primary= May-Thurner syndromes, secondary= Internal iliac veins congenital anomalies</p> <p>Type 3: EXTRINSEC LOCAL CAUSE: responsible for pelvic venous anomalies</p> <ul style="list-style-type: none"> - Endometriosis - Abdominal or pelvic tumors - Benign masses - Uterine retroversion secondary to the postpartum - Post - infectious or surgical adhesences - Allen Masters syndrome: obstetrical destruction of supporting tissue |
|--|

These three types are identical regardless of the location of the varicose veins, genital or extra-genital.

Each type is associated with a specific therapeutic strategy.

- **Type 1 corresponds to autonomous venous anomalies, either parietal or valvular, responsible for reflux and/or varicose veins. There is no pelvic or supra-pelvic obstruction of the venous flow.**
 This type is the most common.
 It may be valve pathologies or venous dilations, congenital or acquired.
 Women's varicoceles, secondary to pregnancy, are often the result of these two mechanisms.
- **Type 2 is secondary to stenosis or obstruction of a venous drainage pathway, responsible for symptomatic substitute collaterals. The obstruction may be at the pelvic or supra-pelvic location.**
 In this type, the isolated treatment of reflux and pelvic varices, without treatment of the obstacle, can lead to aggravation of venous hyper pressure in the abdominal-pelvic and/or lower limb areas. The treatment of obstruction will only be considered after a multidisciplinary assessment of the benefit/risk ratio.
 The most common obstructions are compressions of the left renal vein (LRV) and compressions of the iliac veins.
- **In type 3, pelvic venous anomalies and pelvic venous reflux disease are secondary to an extrinsic local cause (see Table III). The most frequent cause is endometriosis.**
 The type 3 often contraindicates isolated first-line endovascular treatment. A secondary discussion will take place if a symptomatic venous pathology persists after treatment of the cause.

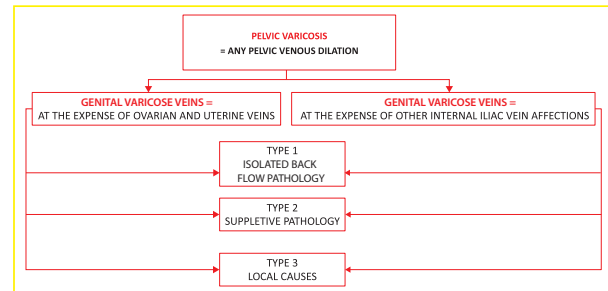
Anatomically, two locations can be differentiated [3, 12]: (**Table III bis**).

- **genital varicose veins, fed by reflux of gonadal or uterine veins;**
- **extra-genital pelvic varicose veins, fed by other internal iliac tributaries, more particularly the gluteal veins (superior et inferior), the obturator and medial pudendal veins.**

These locations can be associated.

These three pathophysiological types are well detected and should be investigated by pelvic venous ultrasound scanning, combined with other cross-sectional imaging study (CT scan, MR imaging) in difficult cases or cases of obstruction.

Table III bis: Summary of the classification.



Transmission mode of pelvic reflux to the lower limbs (Table IV)

Two modes of reflux transmission can be differentiated [10, 12]:

Direct leakage:

Truncal pelvic reflux directly feeds the varicose veins of the lower limbs. Two veins are mainly concerned: the inferior gluteal vein and to a lesser degree, the obturator vein.

Indirect leakage:

Truncal pelvic venous reflux first feeds pelvic varicose veins, which then drain to the lower limbs. Genital refluxes (from gonadal or uterine veins) usually generate indirect leaks.

Extra-genital refluxes can be expressed at the lower limb level, through direct or indirect leakage.

Table IV: Types of transmission of pelvic venous reflux disease to the lower limbs.

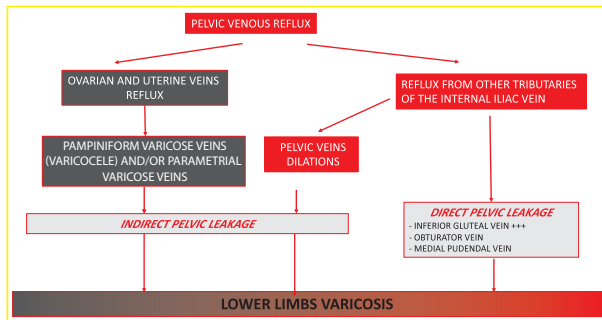
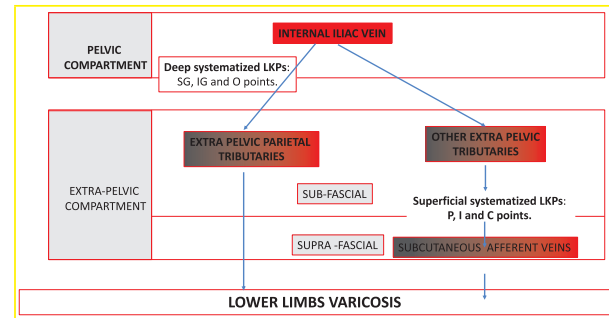


Table V: The different leakage points of pelvic origin.



Externalization mode of pelvic reflux to the lower limbs (Table V)

Whatever the transmission mode, the passage of pelvic reflux to the LL requires communication between the two levels.

In an anatomical drainage pathway, a reverse flow (pelvis to lower limbs) defines a leak point (LKP).

These LKPs can be unsystematized.

In this case, pelvic phlebography highlights a pelvic venous network, of variable size, that transfers pelvic venous blood to lower limbs, without dominant leak.

Conversely, these LKPs can be systematized.

In 2005, Franceschi [4] identified by DUS six systematized and symmetrical LKPs.

They are anatomically known for a long time [5]

- the gluteal points: superior gluteal or SG point and inferior gluteal or IG point
- the obturator point or O point
- the perineal point or P point
- the inguinal point or I point
- the clitoral point or C point

These points are not equivalent. They can be classified into 2 categories according to anatomical and pathophysiological criteria (Table V), but in all cases they correspond to reversed drainage routes.

*Deep systematized LKPs:
These are SG, IG and O points*

They correspond to the anatomical drainage pathways of the extra-pelvic parietal tributaries to the right and left internal iliac veins, their pelvic collecting trunks.

Thus, SG and IG points correspond to the intra-pelvic passage of the gluteal veins, at the level of the large sciatic notch, above (superior gluteal vein) or below (inferior gluteal vein) the piriform muscle.

O Point is the intra-pelvic passage of the obturator vein through the subpubic canal at the obturator hole.

These 3 points are anatomically deep and difficult to access by ultrasonic techniques (US).

*Superficial systematized LKPs:
P, I and C points.*

They correspond to the drainage from an extra-pelvic subcutaneous, suprafascial vein to an extra-pelvic subfascial vein. They can be considered as perforator veins.

Perineal point or P point

- The labia majora are drained by the anterior and posterior labial veins.

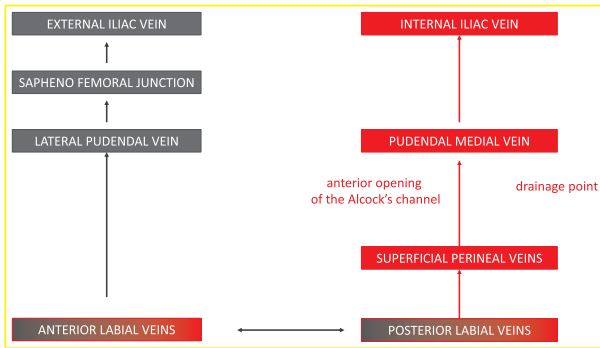
Contribution of ultrasonic explorations in woman's pelvic venous insufficiency.

- The anterior labial veins preferentially drain to the lateral pudendal vein, which joins the external iliac network via the sapheno-femoral junction.
- The posterior labial veins preferentially drain to the superficial perineal veins, then to the medial pudendal vein and ultimately to the internal iliac vein.
- Superficial perineal veins are subcutaneous veins which cross the perineal fascia to drain into the medial pudendal vein through the Alcock's canal located at the posterior 3/4 of the vulva, at the level of the vulvoperineal fold (tables VI).

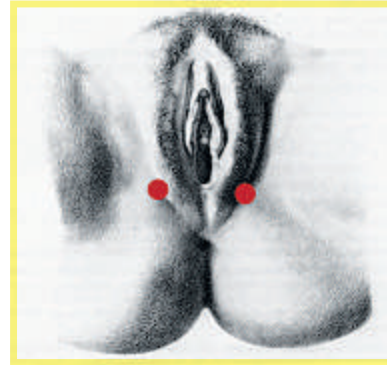

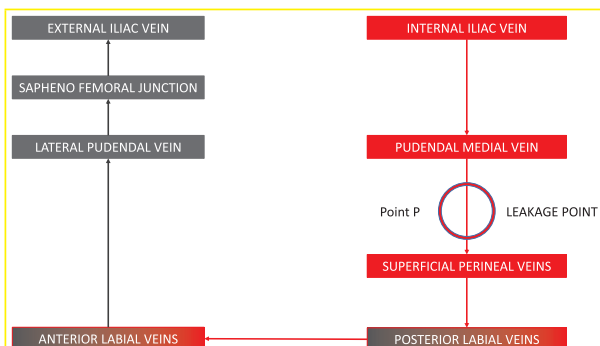
Fig. 1: Location of the P point: 3/4 posterior vulva.

Table VI: Venous drainage pathways of the labia majora.



A truncal reflux of the medial pudendal vein or a reflux from its tributaries, generates an inversion of the pressure gradient in the drained area: the physiological drainage point from the posterior part of the vulva to the medial pudendal vein becomes a perineal leak point or P point (Table VI bis) (fig. 1).

Table VI bis: Hemodynamic diagram of the perineal point or point P.



Inguinal point or I point

The superficial veins of Mount Venus and some epigastric veins drain preferentially into the uterine vein, through the round ligament vein which travels in the inguinal canal. Its external orifice is located above the inguinal ligament, outside femoral vessels.

A venous reflux of the pelvic area, especially from parametrial varicose veins may be externalized through this external orifice, which then becomes the inguinal point or I point (Fig. 2).

In our experience, the presence of a dystrophic venous network – dilated and incontinent – located above the inguinal canal, is pathognomonic of I point.

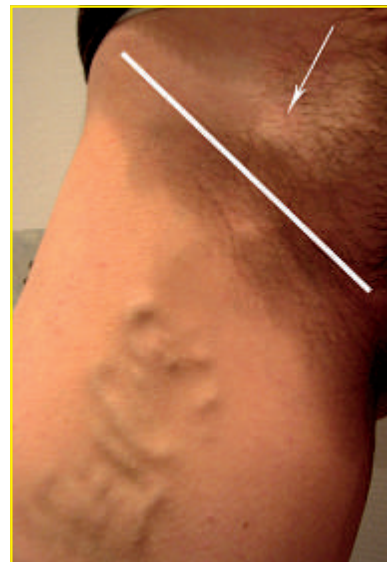

Fig. 2: Location of the I point: situated above the inguinal ligament, outside the femoral vessels.

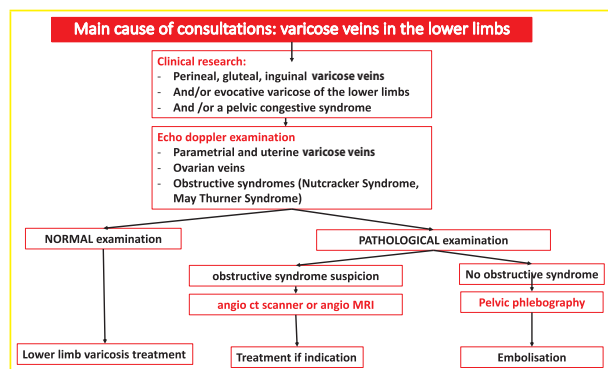
Clitoral point or C point

It is secondary to the incontinence of the medial pudendal vein, at least of its distal segment, which causes an increase in venous pressure of the peri-urethral venous plexus (Santorini plexus) and generates reflux from the deep clitoral veins to the superficial clitoral veins.

This reflux occurs on either side of the clitoris. In practice, this point is more rarely identified.

Decision algorithm

Table VII: Decision-making algorithm for the management of pelvic venous insufficiency.



Our management of the IVPC always follows the same decision algorithm [7, 8], based on 4 steps (Table VII). Only the second step corresponds to the subject of this article, but it is important to place it in its overall context.

Initially, pelvic varicose veins may be suspected in the presence of pelvic congestion syndrome and/or lower limb varicose veins.

The gynecologist's problem is therefore to recognize the venous origin of a chronic pelvic symptomatology and the vascular physician's problem is to recognize the pelvic origin of Lower limb varicose veins.

The second step, based on US exploration, have to confirm, quantify and classify the IVPC.

This first-line investigation is a key step, because in most cases, a decision can be made on the need to other noninvasive explorations (angio CT scan, angio MR) in particular when a venous compression is suspected.

Selective retrograde pelvic phlebography remains the gold standard in the diagnosis of abdominal-pelvic venous pathologies but it is a pre-therapeutic exploration (P and I points included).

Principles of ultrasonic exploration

Our US exploration always follows the same approach, in 5 points:

- search for latero-uterine varicose veins
- examination of gonadal veins;
- research of anatomical or hemodynamic criteria of a Nutcracker syndrome;
- examination of iliac veins and inferior vena cava;
- search for leaks.

In vascular practice, this exploration is carried out in a second phase, when the mapping of LL varicose veins reveals atypical varicose veins or the presence of leak points, suggesting a pelvic origin.

Search for varicose veins in the uterine area

- The examination should be descriptive. Anatomical and hemodynamic criteria should be noted.
- It begins with a supra-pubic exploration, using a macro-convex probe (frequency: 2.5 to 5 MHz).

The peri-uterine venous network is normally tubular, rectilinear, with a diameter of less than 4 mm.

Pelvic varicose veins are dilated and tortuous, with reflux usually at a slow rate, located on either side of the uterus, preferably on the left side (Fig. 3, 4, 5).

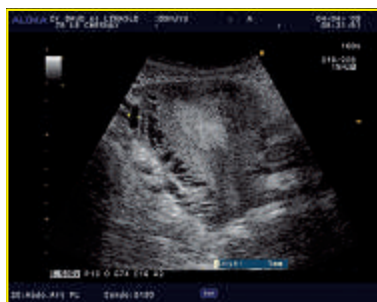

Fig. 3: Abdominal tract. Straight latero uterine varicose veins - straight unilateral forms are rare.

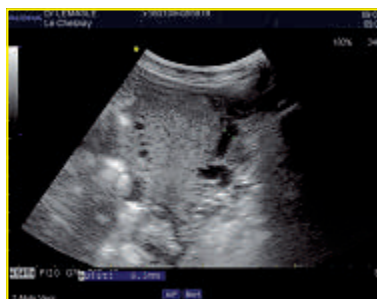

Fig. 4: Abdominal tract. Left lateral-uterine varices, moderately dilated.

Contribution of ultrasonic explorations in woman's pelvic venous insufficiency.

Fig. 5: Abdominal tract. Very important left lateral-uterine varicose veins.

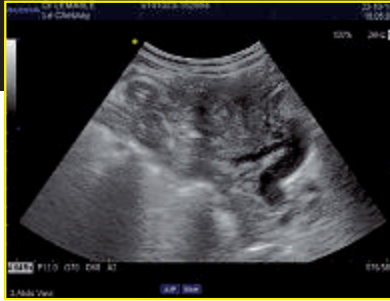

Fig. 6: Abdominal tract. Left lateral-uterine varices. Drainage of left pelvic varicose veins, at least in part, into the right lateral-uterine venous network via the uterine arcuate veins.

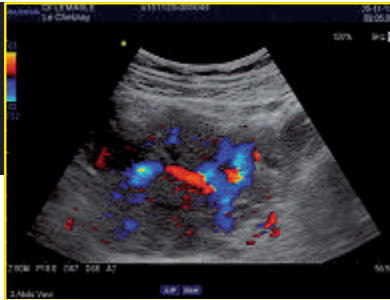
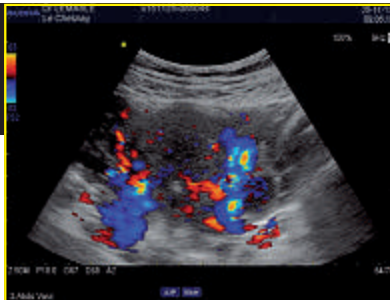


Fig. 7: Abdominal tract. Left lateral-uterine varices. Drainage of the lower pole of pelvic varicosities in the right medial pudendal vein.



There is no threshold diameter, to diagnose genital varicose veins. The presence of dilated arcuate veins crossing the peripheral uterine myometrium or the presence of intra myometrial veins, associated with bilateral peri-uterine varicosities is a good sign (**Fig. 6**). Flow imaging (pulsed Doppler, color or power) confirms the presence of reflux in latero-uterine venous dilatation and sometimes highlights some drainage pathways (**Fig. 6, 7**).

These refluxes can be spontaneous with breathing or caused by abdominal compression maneuvers (soft and prolonged or Valsalva maneuver).

The trans-perineal approach [4, 5], can limit the artifacts related to the mobilization of the abdominal wall during Valsalva maneuver: the patient is in supine gynecological position, the probe placed at the level of the middle perineum.

This position was already used in men to record medial pudendal artery flows in erectile dysfunction assessments.

We do not use transvaginal US for vascular assessment of pelvic varicose veins.

It is useless to find compression of iliac or renal veins, useless for superficial leakage points (P, I and C), but produces superior image quality of lateral-uterine, arcuate and myometrial varices.

Transvaginal ultrasound in high resolution remains essential in the etiological assessment of pelvic symptoms, particularly in the search for ovarian or deep endometriosis or other pelvic pathologies (type 3).

Examination of gonadal veins

The venous territories of the parameters, mesosalpinx, uterine fundus and pampiniform plexus are drained by the gonadal (or ovarian) veins. They are formed by multiple trunks that become a single trunk at the fourth lumbar vertebrae.

The right gonadal vein drains directly into the inferior vena cava and occasionally into the right renal vein.

The left gonadal vein drains usually into the left renal vein.

There are many anatomical variations about the number of trunks (double or even triple) and the termination mode [11].

The ultrasonic evaluation of these variations is incomplete. The best anatomical landmark for locating gonadal veins is the psoas muscle (**Fig. 8**).

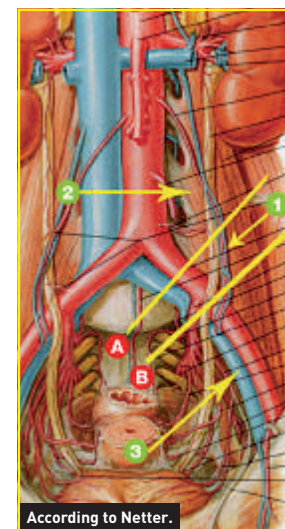
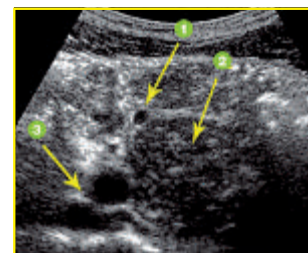
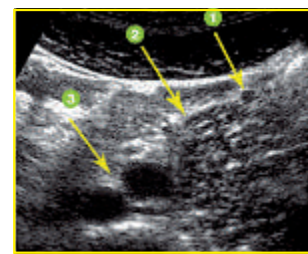
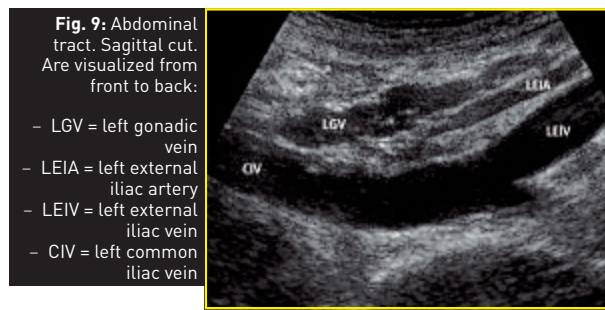


Fig. 8: Ultrasound semiology of the left gonadal vein:
 1: left gonadal vein. 2: psoas muscle. 3: iliac vessels.
 upper image: section A.
 lower image: section B

According to Netter.

On the left side, the upper part of the gonadal vein is located on the anterior edge of the psoas muscle. In its lower part, it is more internal.

On the pelvic level, the left gonadal vein crosses the common iliac vessels. It is sometimes possible to visualize on the same sagittal section, from front to back, the gonadal vein, the iliac artery and then the iliac vein (Fig. 9).



The diameter of the gonadal vein should be noted, but this measurement is only a guide, as a dilated gonadal vein can be draining, and conversely, a thin gonadal vein can have a reverse flow.

Gonadal reflux is achieved with pulsed or color Doppler.

Several types of reflux are documented:

- reflux caused by abdominal hyper pressure maneuvers.
- spontaneous and intermittent reflux.
- permanent reflux in orthostatism or decubitus, more or less modulated by breathing.

The hemodynamic status of the gonadal vein allows for suspicion of the type of varices:

- in type 1 (reflux pathology, without pelvic or supra-pelvic obstacles), reflux can be spontaneous, even quasi-permanent in the case of gonadal steal syndrome, but it remains modulated by respiration.
- in type 2 (obstructive pathology), the left gonadal vein is often the main drainage route for renal flow. In this context, gonadal reflux will be spontaneous, permanent, and little or no modulated by respiration.
- type 3 may be suspected in the presence of a discrepancy between a large varicocele and a moderate ovarian venous reflux.

Search for anatomical or hemodynamic criteria suggesting a significant compression of the left renal vein (LRV)

The symptomatic compressions of the LRV are also termed as Nutcracker syndromes.

Several anatomical forms have been identified:

- the anterior form, the most frequent, corresponds to the compression of the LRV between the superior mesenteric artery (SMA) and the abdominal aorta. When it is symptomatic, this is termed as anterior Nutcracker syndrome (NCS);
- the posterior form, when the LRV is retro-aortic and is compressed between the aorta and the lumbar spine. When there are symptoms, it is called posterior Nutcracker syndrome;
- the combined anterior-posterior form, when the two branches of a duplicated LRV is compressed, the anterior segment between the aorta and the SMA while the posterior segment between the aorta and the vertebral column.

Several authors have attempted to improve the diagnostic criteria for ultrasound investigations. Quantitative ultrasonic criteria to diagnose significant anterior compression have been described, but they are based on studies with small samples [13-15].

The detection of significant LRV stenosis is based on US by measurement of the antero-posterior (AP) diameter of the LRV coupled with Doppler US measurement of the peak flow velocity (PV) of the LRV, made at two levels, near the renal hilum and at the aorto-mesenteric entrapment.

Diagnosis of nutcracker syndrome should be suspected when the AP diameter ratio and the PV ratio at these two points are greater than five.

With this ratio cutoff value of more than 5, the sensitivity and specificity of the Doppler echo for diagnosing Nutcracker syndrome have been reported as 80 to 94% for the anatomical criteria and as 69% and 89% respectively for the velocity criteria.

If we combine these two ratios (sum divided by two), with the cutoff above 5, the sensitivity and specificity are 90 and 100% respectively [14].

However, the LRV has a marked variation in caliber, depending on systolic-diastolic time, inappropriate angle of insonation and above all on patient's position, supine or sitting position. The same remarks apply for the measurement of peak velocity.

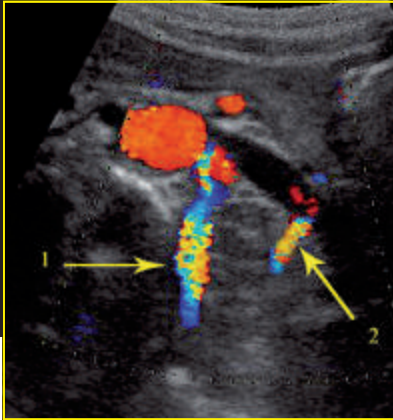
In our practice, an anterior compression is discussed when the distance between the SMA and the aorta is below 5mm. But the most important criterion is indirect. It corresponds to the permanent and non-modulated reflux by breathing recorded in the left gonadal vein. Such a reflux should always suggest a collateral pathway secondary to a tightened stenosis of the LRV and lead to the search for the direct signs mentioned above and the visualization of the other substitution pathways [15, 7] (fig. 10).

The convergence of these anatomical and hemodynamic criteria strongly suggests a significant compression of the LRV and patients should undergo angio CT scan or

Contribution of ultrasonic explorations in woman's pelvic venous insufficiency.

Fig. 10: Abdominal tract. Tight stenosis of the L renal vein termination in the aortomesenteric space. Visualization of fast speeds in the substitution channels:

1 - lumbar vein;
 2 - termination of the L gonadal vein and reverse flow, at high speeds, from the left renal vein to the L gonadal vein.



angio MRI with multi-planer imaging allowing excellent anatomical definition especially of the aorto-mesenteric angle.

Examination of iliac vessels

In this context, the physician looks essentially for post-thrombotic sequelae or venous compression.

The most common compression is the entrapment of the left common iliac vein (LCIV) between the right common iliac artery and the overlying spine, associated with intraluminal synechia or spurs. This is the main form of May-Thurner syndrome, but other compressions can occur all along right or left iliac veins. Iliac vein compression is a frequent anatomic variant and is incidentally commonly observed on many cross-sectional imaging studies. More than 50% luminal compression of the left iliac vein can be seen in up to 25% of asymptomatic healthy individuals [16].

The differentiation between a physiological compression and a hemodynamic compression is challenging.

Hemodynamic compression, generates hyper pressure and upstream venous stasis, which can lead to acute and chronic deep vein thrombosis.

There are US criteria for symptomatic hemodynamic compression:

- slower speeds and reduced respiratory modulation of the upstream venous flow, particularly in the femoral vein
- flow reversal in the ipsilateral internal iliac vein
- presence of substitute varices or channels

Search for systematized leak points

Deep systematized LKPs (SG, IG and O points) are not always directly accessible to ultrasonic explorations.

On the other hand, varicose veins in the territory of their tributaries are easier to identify and represent indirect signs of truncal reflux:

- the superior gluteal vein drains mainly the small, medium and large gluteal muscles. A truncal reflux of this vein result in buttock varicose veins.
- the inferior gluteal vein drains a part of buttocks, thighs and satellite veins of the sciatic nerve by its deep tributary. Buttock varices associated with sciatic nerve varicose veins [17, 18] are very suggestive of incompetent inferior gluteal vein.
- the tributaries of the obturator vein communicate with the medial circumflex veins that drain into the deep femoral vein or the common femoral vein, near the saphenofemoral junction.
- a pre-terminal reflux of the saphenofemoral junction, during Valsalva maneuvers fed by a medial tributary other than the lateral pudendal vein, suggests obturator vein incontinence

It should be noted that a reflux of the obturator vein can also feed labial veins through its genital tributary.

Conversely, the superficial systematized LKPs (P, I and C points) are directly accessible to ultrasonic explorations.

Doppler echo is the most relevant test to identify these LKPs.

Their location has been mentioned above.

They must be characterized by their caliber and hemodynamic status.

The reflux can be spontaneous or caused by the Valsalva maneuvers.

Permanent and unmodulated reflux, especially associated with truncal reflux of the same type, is an additional argument to diagnose venocompressive syndrome.

From a hemodynamic point of view, these superficial systematized LKPs are the preferred drainage pathways for the lower pole of pelvic varicose veins - the upper pole usually drains through the contro-lateral gonadal vein and internal iliac tributaries.

If this drainage is sufficiently effective, there will be no pelvic venous hyper pressure.

This concept has two consequences:

- Pelvic varices with obvious dilatation and reflux, can be asymptomatic at the pelvic level if they are well drained. In other words, the absence of pelvic congestion syndrome is not a sufficient argument for not treating the pelvic venous pathology.

- The isolated ligation of a leak point [19], especially if it is very dilated, without treatment of overlying truncal refluxes, does not seem to be an adequate response.
- This isolated procedure can lead to two harmful effects:
 - an increase in intra pelvic venous pressure and a change of well-drained and asymptomatic pelvic varices into insufficiently drained varices which become symptomatic;
 - the emergence of vaginal and genitals varices after the ligation of the P point if the truncal reflux of the medial pudendal vein can no longer be externalized. These varicose veins are difficult to treat.

If they cannot explore all pelvic refluxes, they are sufficient to identify pelvic varicose veins and very effective to diagnose leak points of pelvic origin, especially when they are superficial.

They suggest the main obstructive syndromes.

In these cases, the diagnosis will be confirmed by a second cross-sectional imaging such as angio MR or angio CT.

Selective retrograde pelvic phlebography remains is the gold standard in diagnosing pelvic venous pathology but must remain a pre-therapeutic exploration.

Conclusion

In the management of pelvic venous disorders, ultrasound explorations are first-line investigations.

References

- [1] Hobbs JT. The pelvic congestion syndrome. Br J Hosp Med 1990; 43: 200-6.
- [2] Villavicencio JL., Gillespie D., Durholt S., et al. Diagnosis and Treatment of the Pelvic Venous Disorders: pelvic congestion and pelvic Dumping Syndromes. In: Cann CC (ed.), Surgical Management of Venous Disease; 1st ed. Baltimore: Williams and Wilkins, 1997; 462-83.
- [3] Greiner M. Syndrome de congestion pelvienne : diagnostic et traitement. Phlébologie 2005; 58: 293-8.
- [4] Franceschi C., Bahnini A. Points de fuite pelviens viscéraux et varices des membres inférieurs. Phlébologie 2004; 57: 237-42.
- [5] Franceschi C., Bahnini A. Treatment of lower extremity venous insufficiency due to pelvic leak points in women. Ann Vasc Surg 2005; 19: 284-8.
- [6] Perrin MR., Labropoulos N., Leon LR Jr. Presentation of the patient with recurrent varices after surgery (REVAS). J Vasc Surg 2006; 2: 327-3.
- [7] Lemasle P. Atlas d'Echo-anatomie veineuse superficielle -Tome 5. La varicose pelvienne de la femme. 2008. Laboratoires TONIPHARM Boulogne-Billancourt.
- [8] Lemasle P. Stratégie diagnostique dans la prise en charge de la varicose pelvienne de la femme. Phlébologie 2009; 62(3): 21-39.
- [9] García-Gimeno M., Rodríguez-Camarero S., Tagarro-Villalba S., and al. Duplex mapping of 2036 primary varicose veins. Duplex mapping of 2036 primary varicose veins. J Vasc Surg 2009; 49 (3): 681-9.
- [10] Greiner M., Faye N., Thouveny F. Traitement endovasculaire par embolisation de l'insuffisance veineuse pelvienne chronique. In : Thérapeutique endovasculaire des pathologies veineuses. Milka Greiner. Springer-Verlag ed 2012; chapitre 17: 236-64.
- [11] Leichter A., Lopez G., Martinez C., Camacho J. Anatomy of the gonadal veins: a reappraisal. Surgery 1991; 109: 735-39.
- [12] Greiner M., Dadon M., Lemasle P., Cluzel P. How does the patho-physiology influence the treatment of pelvic congestion syndrome and is the result long-lasting ? Phlebology 2012; 27 Suppl 1: 58-64.
- [13] Arima M., Hosokawa S., Ogino T. Ultrasonographically demonstrated nutcracker phenomenon: alternative to angiography. Int Uro Nephrol 1990; 22: 3-6.
- [14] Kim SH., Cho SW., Kim HD., & al. Nutcracker syndrome: diagnosis with Doppler US. Radiology 1996; 198: 93-7.
- [15] Takebayashi S., Ueki T., Ikeda N., Fujikawa A. Diagnosis of the nutcracker syndrome with color Doppler sonography: correlation with flow patterns on retrograde left renal venography. AJR Am J Roentgenol 1999; 172 (1): 39-43.
- [16] Lemasle P., Uhl J.F., Lefebvre-Vilardebo M., Gillot C., Baud J.M., et Vin F. Veine du nerf sciatique et Maladie Variqueuse : Aspects écho-anatomiques et hémodynamiques. Phlébologie 2001; 54: 219-28.
- [17] Raffetto JD., Khalil RA. Mechanisms of varicose vein formation: valve dysfunction and wall dilation. Phlebology 2008; 23: 85-98.