Aucun article ou résumé dans cette revue ne peut être reproduit sous forme d'imprimé, photocopie, microfilm ou par tout autre procédé sans l'autorisation expresse des auteurs et de l'éditeur. Editions Phlébologiques Françaises
No article or abstract in this journal may be reproduced in the form of print, photocopy, microfilm or any other means without the express permission of authors and the editor. Editions Phlébologiques Françaises

Phlébologie ANNALES VASCULAIRES 2019, 72, 3, p. 51-70

SOCIÉTÉ FRANÇAISE DE PHLEBOLOGIE

Chapter 18

Ultrasound-Guided Angioplasty of Stenoses of the Vascular Access for Hemodialysis

Fabrice Abbadie

Abstract

Arteriovenous fistula (AVF) dialysis complications are mainly located on the venous side. They are many and varied:
- stenosis,
- thrombosis,
- high volume flow,
- aneurysms,
- compression,
- ischemia of the hand,
- delayed and pseudo delayed maturation,
- edema of the limb and face...

This chapter will only deal with the treatment of stenosis, as this is the most frequent endovascular procedure possible on vascular access for dialysis.

Causes of Stenosis

The arterialized vein of a dialysis AVF is a very "special" vein in several respects. It must gradually increase in volume to reach a diameter of about 6 mm that is easily palpable and therefore easily punctureable **(see Box 1)**. Its wall changes and thickens in just a few weeks after arterialization.

Juxta-anastomotic stenosis

Anastomosed to an artery, its flow profile is similar to that of an artery, yet with low resistance to blood flow (excluding stenosis or downstream occlusion).

Box 1: The rule of 6: To allow dialysis in good conditions, at 6 weeks from its creation, the AVF must have [8]:
- **a minimum of 6 mm diameter**
- **Maximum depth 6 mm from the skin surface**
- **Flow rate above 600 mL/min**

However, as soon as one moves away from the anastomosis, the low compliance of the venous wall causes the parietal thrill to disappear after only a few cm. The 90° to 180° diversion of the arterial flow in the anastomosis sends the shear stresses to the juxta-anastomotic venous wall. They thus generate repetitive strain micro injuries that damage the constantly healing venous wall and stimulate myointimal hyperplasia **(Fig. 1)**.

This is the most common cause of stenosis and the most likely to recur, since angioplasty does not treat the cause. However, their appearance is not constant and depends on multiple parameters including the surgical connection angle between the vein and the artery [1].

Hypodevelopment of the vein

Some stenoses are actually a lack of dilation, a hypodevelopment of the vein with a diameter that does not grow as much as the rest of the vein or as much as necessary.

Aucun article ou résumé dans cette revue ne peut être reproduit sous forme d'imprimé, photocopie, microfilm ou par tout autre procédé sans l'autorisation expresse des auteurs et de l'éditeur. Editions Phlébologiques Françaises
No article or abstract in this journal may be reproduced in the form of print, photocopy, microfilm or any other means without the express permission of authors and the editor. Editions Phlébologiques Françaises

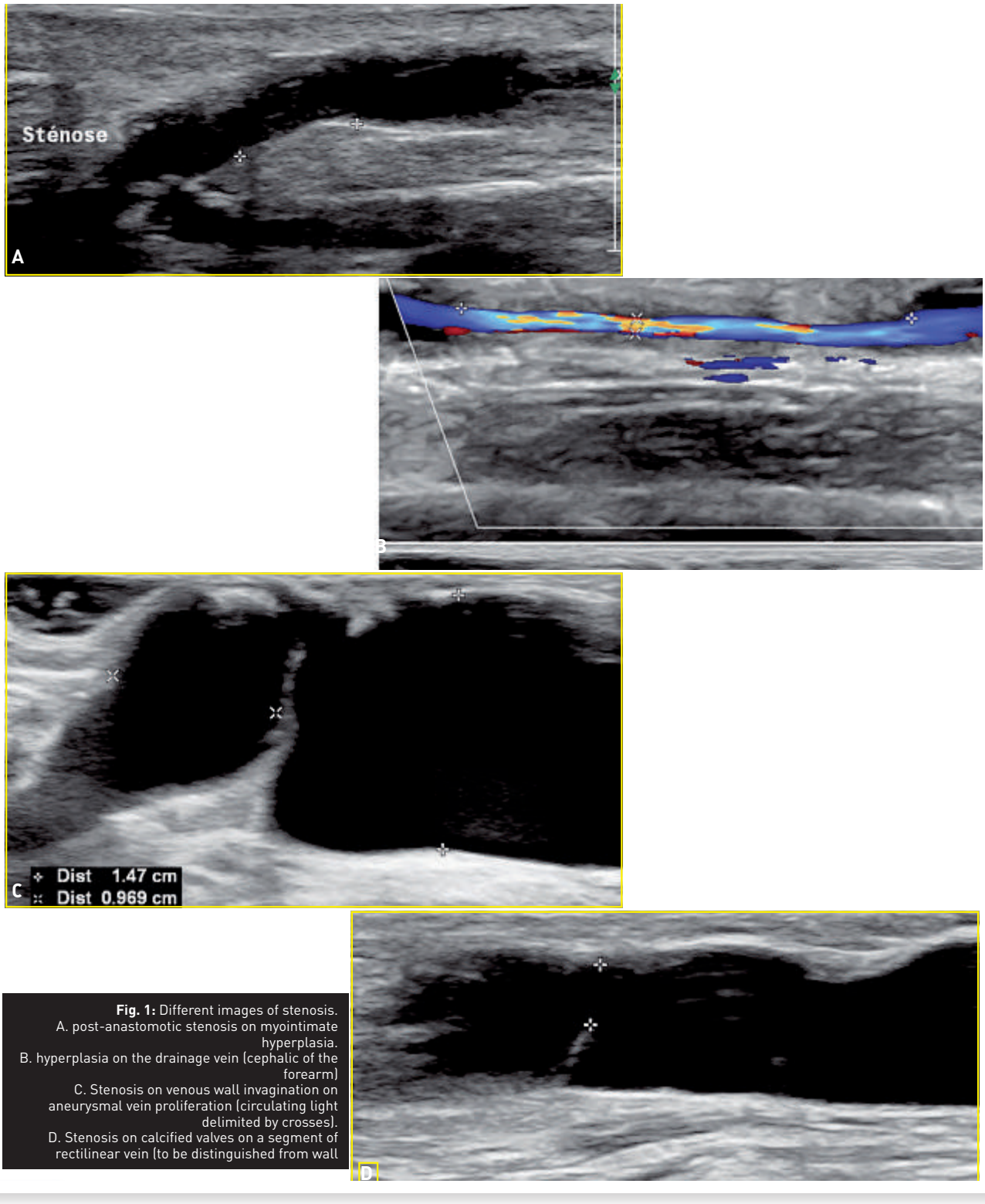

Fig. 1: Different images of stenosis.
A. post-anastomotic stenosis on myointimate hyperplasia.
B. hyperplasia on the drainage vein (cephalic of the forearm)
C. Stenosis on venous wall invagination on aneurysmal vein proliferation (circulating light delimited by crosses).
D. Stenosis on calcified valves on a segment of rectilinear vein (to be distinguished from wall

Aucun article ou résumé dans cette revue ne peut être reproduit sous forme d'imprimé, photocopie, microfilm ou par tout autre procédé sans l'autorisation expresse des auteurs et de l'éditeur. Editions Phlébologiques Françaises
No article or abstract in this journal may be reproduced in the form of print, photocopy, microfilm or any other means without the express permission of authors and the editor. Editions Phlébologiques Françaises

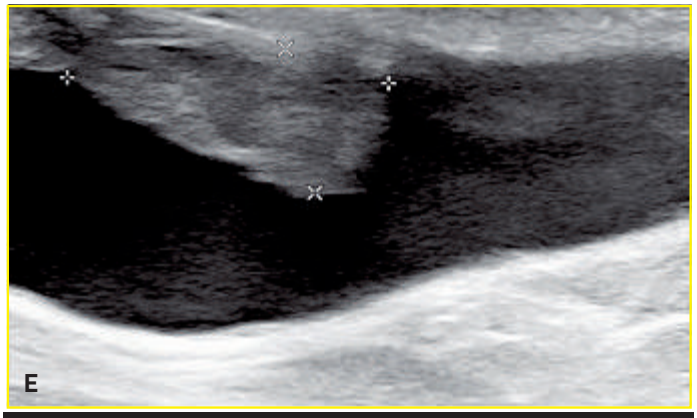

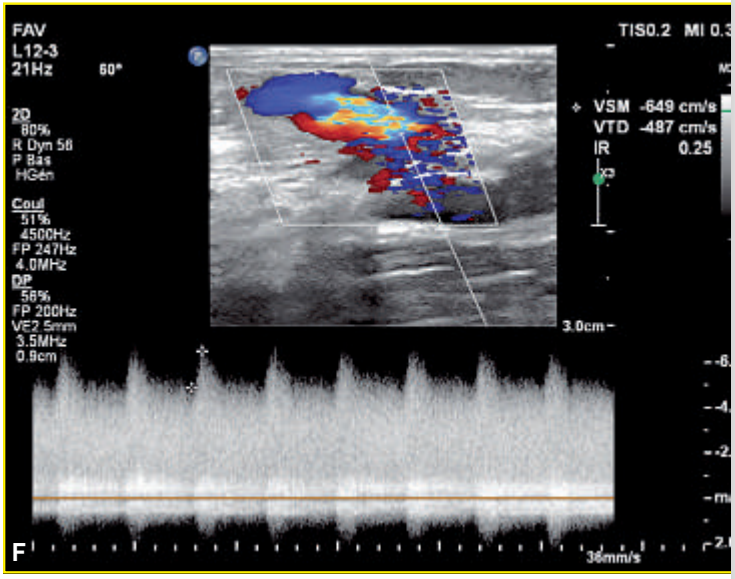

Fig. 1 (continued): Different images of stenosis.
E. Insignificant stenosis on an endoluminal wall hematoma typical of the puncture site. F. Spatial dispersion of the color Doppler signal that extends well beyond the lumen of the vein at the top of the image and spectral dispersion around the pulsed Doppler baseline with very accelerated velocities for both peak systolic velocity (PSV) and end diastolic velocity (EDV).

This lack of development can be due to various causes, most often anatomical.

For examples, here are some configurations or anatomical dispositions which may lead to a hypodelopment of the vein:

- Sequelae of trauma (after venous punctures), venous thrombosis, lymphangitis or inflammatory veinitis
- fibrous ring surrounding the vein with respect to the birth or arrival of collateral;
- short inter-fascial pathway (as saphenous veins can have);
- a path that is reflected on a muscular edge;
- back to front passage of the cephalic vein along the outer edge of the radius;
- cephalic arch.

Another common cause of vein hypodevelopment, which then affects the entire vein, is arterial disease. Isolated but significant arterial stenosis slows the progression of volume flow and, therefore, the development of venous calibre.

Sometimes the duplex ultrasound examination does not identify any focal acceleration of the flow, but it is an artery of generally poor quality because of marked mediacalcosis that does not expand, and therefore does not allow the flow to progress.

Post-puncture

During repeated punctures at the same site (puncture sites should normally be varied, with the exception of the "button hole" technique), it may happen that the repeated aggressions of the posterior wall at the exit of the puncture site generates stenosis by wall hematoma and/or myointimal hyperplasia.

Wall Plicature

Venous hyperpressure (see below) can generate aneurysms which, as they progress, can lead to the appearance of "haustrations", plicatures of the venous wall which can invaginate in the lumen and thus create stenosis **(Fig. 1C)**.

Compression

Some stenoses may also result from compression by post-puncture hematoma on immature AVF s.

Valves

Localized valvular hypertrophy can generate stenosis, this phenomenon is still poorly understood and not systematic.

Calcified venous stenoses

Some very old AVF s will experience endoluminal calcified concretion that can create stenosis.

Post-surgical

Surgical manipulations can be complicated by stenosis, particularly on the central part of superficialized veins (brachial basilar vein for example).

Aucun article ou résumé dans cette revue ne peut être reproduit sous forme d'imprimé, photocopie, microfilm ou par tout autre procédé sans l'autorisation expresse des auteurs et de l'éditeur. Editions Phlébologiques Françaises
No article or abstract in this journal may be reproduced in the form of print, photocopy, microfilm or any other means without the express permission of authors and the editor. Editions Phlébologiques Françaises

Functional

Finally, it should be noted that some stenoses are, sometimes partially, functional. Indeed, a small reduction in size can cause a very significant acceleration of the flow in stenosis if the dialysis AVF is in high volume flow **(see Box 2)**, whereas in normal volume flow conditions this acceleration would be much less important, if not insignificant. Remember that these stenoses do not desserve angioplasty.

Box 2: The volume flow in the access
- Essential parameter for duplex ultrasound evaluation
- Measured on the brachial artery on a straight segment with favorable angle, on a segment free of atheroma [9]
- Average the average speed over several cardiac cycles
- Give an average value of the flow rate over at least 3 measurements up to a minimum of 6 in the event of a value discrepancy or cardiac arrhythmia
- Distrust of the high bifurcation of the brachial artery. Position yourself above, even if it means putting yourself in an axillary position if there is no brachial artery.
- Normal volume flow rate : Radial AVF: 500 to 800 mL/min. Brachial AVF: 800 to 1200 mL/min.
- Volume flow is low if < 500 mL/min. for native AVF and < 600 mL/min. for prosthetic AVF [8]
- High volume flow if value > 1200 mL/min.
- Cardiac impact: output > 2000 mL/min. or > 20% of cardiac output.
- Has a good correlation with the Transonic® measurement made during dialysis [8].

Clinical presentations

A few reminders about how a hemodialysis session works

The arterial puncture site refers to the upstream puncture site (in the direction of flow) on the vein that will be used for the arterial needle of the dialysis machine that will collect blood. The arterial blood pressure (AP) in this line is a negative value measured instantly and continuously by the machine and reflects the resistance to aspiration.

The blood then passes through the extracorporeal circuit to the artificial "kidney" (a tube with a membrane to filter the blood like a kidney). The blood is hemodiafiltered by the machine. Then it is returned by the 2nd "venous" puncture site for the venous line.

The venous blood pressure (VP) in this needle is also monitored continuously. VP reflects the resistance to blood injection. Normally, the blood re-injected by the venous needle is released into the patient's body circulation.

However, a fraction of this blood is immediately reabsorbed by the arterial needle. Thanks to small sodium boluses, the dialysis machine can calculate this recirculation rate normally below 10%. Finally, throughout the session, the machine displays good dialysis quality parameters (dialysance, quantity of urea purified: Kt/V,...).

Occasionally, about once a month, as a matter of routine, an additional device can be connected to the blood system: the Transonic®.

It detects with ultrasonic sensors the passage of a bolus of salted serum and thus calculates the full volume flow rate of the AVF. Unfortunately, this device does not equip all the centres because these procedures are not listed and therefore its use is not reimbursed in each country.

Finally, the time required to compress the puncture sites and stop the bleeding at puncture sites once dialysis is completed is also a useful parameter. Each of these dialysis parameters is set by the dialysis nurses with limit values and alarms. It is therefore possible that it is these anomalies observed during the dialysis session that motivate the ultrasound examination and then angioplasty.

The main clinical pictures are presented in Table 1

Venous stenosis has a different clinical presentation depending on its location on the vein in relation to the puncture sites for dialysis.

The low volume flow illustration can also be caused by stenosis on the arterial side.

The stenosis located between the 2 puncture sites is sometimes clinically unknown, because it can be integrated into a table of minor or changing dysfunctions, and it is then the duplex ultrasound examination that can help in the diagnosis.

A venous hyperpressure table may also result from high volume flow in the access, isolated or associated with venous stenosis.

Diagnostic Duplex ultrasound criteria

Stenosis is diagnosed on direct color Doppler signs

Localized aliasing - while the speed scale is set to maximum for AVFs - with spatial dispersion of the color signal.

At pulsed Doppler:

There is a spectral dispersion associated with an acceleration of the velocity.

In 1998, Robbin et al. [2] defined a stenosis ≥ 50% diameter reduction for a maximum peak systolic velocity (PSV)

Aucun article ou résumé dans cette revue ne peut être reproduit sous forme d'imprimé, photocopie, microfilm ou par tout autre procédé sans l'autorisation expresse des auteurs et de l'éditeur. Editions Phlébologiques Françaises
No article or abstract in this journal may be reproduced in the form of print, photocopy, microfilm or any other means without the express permission of authors and the editor. Editions Phlébologiques Françaises

Table 1: Clinical pictures according to the location of venous stenosis (AP: blood pressure in the arterial needle, VP: blood pressure in the venous needle). * PA is a negative parameter that reflects suction resistance.

	Location of venous stenosis	Upstream of the puncture sites	Between puncture sites	Downstream of puncture sites
	Type of table	Low pressure		Venous hyperpressure
Excluding dialysis	Palpation	Flat/soft vein	Vein stretched to the arterial puncture site	Tight and pulsatile vein along the entire path
			Soft vein from the venipuncture site	Progression of aneurysms
				+/- hand edema
	Arm elevation	Complete emptying	No draining upstream of the stenosis, complete draining downstream	No draining, the vein remain filled
In dialysis	Vein puncture	Difficult	Normal	Easy to use
	Effective blood flow	Lowered	Normal or lowered	Normal or lowered
	AP*	High	Normal or lowered	Lowered
	VP	Lowered	Normal or lowered	High
	Recirculation rate	High	Normal	High
	Dialysis efficiency	Lowered	Normal or lowered	Normal
	Compression time	Normal	Normal (or increased to arterial point)	High

greater than 4 m/s, a ratio of Vs max ≥ 2. The ratio of PSV corresponds to the PSV at the stenosis site divided by the PSV recorded upstream, ideally on a straight segment of correct size. A stenosis ≥ 75% is identified for a ratio of Vs max ≥ 3.

In 2013, Raju et al. [3] also concluded that a ratio of PSV ≥ 2 was the best criterion for detecting stenosis ≥ 50%, with a sensitivity of 96% and a specificity of 57%. The Hawaiian Wo team in 2017 [4] included nearly 780 patients with exclusively native AVFs in its retrospective study and determined that PSV > 5 m/s is the best parameter to identify stenoses with a sensitivity of 89% and a positive predictive value of nearly 99%. The number of false negatives was then only 0.6%, which seems very low. Their analysis is that Vs max < 4 m/s corresponds to stenoses <50% most often unless associated with a 2nd stenosis >50% or heart failure with a low ejection fraction. For them, the velocity ratio cannot be used because it is not sufficiently reproducible, the site chosen to record the upstream flow depends on the operator.

This important series nevertheless suffers from the same weaknesses as the others: the reference comparison is a purely morphological parameter, yet the native approaches sometimes have a wall with very irregular parallelism with pre- or post-stenotic aneurysms making it difficult to identify a reference caliber either on ultrasound or angiography. Symptomatic stenoses (which may be <50% in some maturation delays) are not differentiated from asymptomatic stenoses which also exist. The other pitfall in defining these charts is the volume flow rate of AVF, which varies greatly from patient to patient and has an impact on circulatory velocities. A threshold value of 5 m/s may lead to a number of significant stenoses for low volume flow AVFs (especially those delayed in maturation) being missed. Unfortunately, no studies have been conducted in this regard.

Finally, a purely morphological parameter: the measurement of the endoluminal diameter is also interesting. Fahrtash et al [5] have shown that a diameter of less than 2.7 mm is predictive of vascular access dysfunction, with sensitivity at 90% and specificity at 80%.

The main values to be retained for the practice are summarized in **Table 2**.

Table 2: Diagnostic echo-doppler criteria for hemodynamic and morphological stenoses (PSV : peak systolic velocity) [2, 3, 5]

	Stenosis ≥ 50%	Stenosis ≥ 75%
PSV	≥ 5 m/s	
PSV Ratio	≥ 2	≥ 3
	High risk of malfunctioning	
Diametre	< 2.7 mm	

Aucun article ou résumé dans cette revue ne peut être reproduit sous forme d'imprimé, photocopie, microfilm ou par tout autre procédé sans l'autorisation expresse des auteurs et de l'éditeur. Editions Phlébologiques Françaises
No article or abstract in this journal may be reproduced in the form of print, photocopy, microfilm or any other means without the express permission of authors and the editor. Editions Phlébologiques Françaises

For central veins, a ratio of V max to >2.5 between the upstream and the outlet of stenosis is the criterion used for the diagnosis of proximal deep vein stenosis [6].

Indication of angioplasty

The clinic

As with any invasive procedure, the indication for AVF venous angioplasty is most often based on the clinic.

Venous stenosis must be symptomatic and correspond to one of the clinical presentations described above (Table 1), although some pictures may be incomplete.

The decrease in volume flow rate

The only exception to this rule of relying on the clinic is the significant decrease in fistula flow. Indeed, flow measurement is a paraclinical and not a clinical criterion.

However, a decrease in volume flow rate has been identified as a predictor of thrombosis. Thus, the relative risk of thrombosis within 6 months of AVF is increased by 40% when the volume flow rate is less than 500 mL/min. and multiplied by 2 when the volume flow rate is less than 300 mL/min. [7]

Finally, the American KDOQI (Kidney Disease Outcomes Quality Initiative) recommendations identify low volume flow and volume flow drops AVFs as follows:

- **flow rate < 500 mL/min. for a native approach,**
- **flow rate < 600 mL/min. for prosthetic bypass,**
- **25% drop from the highest known volume flow rate value [8].**

It should be noted that vascular accesses (native and mixed prosthetics) at a volume flow rate of < 600 mL/min. also had a PSV < 1 m/s on the brachial artery in the study by Ko et al [9].

The volume flow measurement must therefore be given the full attention of the operator during the duplex ultrasound examination, so that it is as reliable as possible **(Box 1)**.

These data on volume flow drop justified the strategy of pre-emptive treatment of stenosis without dysfunction but with volume flow drop. This therapeutic strategy is now being challenged by recent meta-analyses [10, 11] which have not shown any improvement in the longevity of AVF, but acknowledge a benefit on the thrombosis rate.

The location of stenosis and AVF

The therapeutic option also depends on the location of the stenosis on the AVF.

- **According to the teams, juxta-anastomotic stenoses of the forearm AVFs can be treated surgically with 1st intention [12].**
- **If, however, an angioplasty treatment has been chosen as a first-line treatment, any recurrences of stenosis should be the subject of a multidisciplinary discussion for re-evaluation of the indication.**
- **Indeed, in the case of forearm AVFs, after one or more recurrences, it generally seems lawful to prefer a surgical reimplantation.**
- **On the other hand, for juxta-anastomotic arm stenoses, angioplasty is preferred in the first intention, as well as for drainage vein stenoses regardless of their sites.**

Procedure

The entire procedure itself has been fully described in Luc Turmel-Rodrigues' reference book [13].

Let us briefly recall the different steps:

- **Ultrasound identification of the artery, vein, lesion and possible obstacles,**
- **Puncture,**
- **Navigation and stenosis crossing by the guidewire,**
- **Mounting the balloon on the guidewire then inflating it,**
- **Checking the result,**
- **Removal of equipment and manual compression.**

The description below provides details on the specificities of ultrasound guidance, which we discuss in more detail.

Ultrasound probe and cuts

A linear probe from 3 to 12 MHz is preferred because some of the vessels are too deep for high-frequency probes to be used easily. At each step of the procedure, the longitudinal view will be the preferred imaging for ultrasound guidance, this view is dynamic with lateral movements over the entire width of the vessel and sometimes completed by axial views. The best cutting plane is the one that displays, on the same longitudinal image, the lesion or obstacle to be crossed and the end of the endovascular equipment. Before the start of the procedure, it is advisable to have examined the entire access in order to acquire landmarks.

Puncture

The use of ultrasound makes it possible to have, even before the beginning of the procedure, an almost complete imaging of the vascular aaccess (since the central vessels are poorly visualized). Thanks to ultrasound, the range of puncture sites is wider than those that can only be felt with the finger or visible to the eye, with the possibility of puncturing the hilly veins.

Aucun article ou résumé dans cette revue ne peut être reproduit sous forme d'imprimé, photocopie, microfilm ou par tout autre procédé sans l'autorisation expresse des auteurs et de l'éditeur. Editions Phlébologiques Françaises
No article or abstract in this journal may be reproduced in the form of print, photocopy, microfilm or any other means without the express permission of authors and the editor. Editions Phlébologiques Françaises

The choice of puncture site must therefore anticipate the important and delicate points of the procedure:

- Navigation, i.e. the ability of the kit to move from the introducer to stenosis;
- distance between the introducer and the stenosis to be treated. Since inflation must, of course, be carried out beyond the introducer and not within it, there must be sufficient distance between the puncture site and the stenosis to allow space for the introducer;
- anticipation of the final compression, which is manual (no use of closing devices on AVFs). For effective compression, you need a back pressure, a support on which to lean. This is most often possible for the superficial veins of the arm and forearm and for the radial artery, which rest on muscle masses, themselves surrounding the bones. However, this is not the case for the brachial artery over a large part of its path, except at the bend of the elbow against the humerus. This makes it a more exceptional site to be punctured.

It is by considering all these criteria that the site to be punctured is chosen, most often on the venous side.

Indeed, arterial punctures are subject to potential complications and difficulties of their own.

Punctures of the brachial artery are more frequent than all other sites: false aneurysm, bulky hematoma, median nerve damage,...

For these reasons, brachial puncture is contraindicated in patients receiving curative anticoagulation [13] and will be performed as little as possible in others.

Puncture of an artery may be hindered by parietal calcifications; this is not uncommon in the case of the radial artery. A highly calcified artery may, exceptionally, be impossible to perforate, not by the needle, but by the dilator of the introducer sheath. In addition, calcifications can also make ultrasound guidance during the procedure more difficult (visualization of equipment, navigation).

Note: The insertion of a 5F desilet into the radial artery upstream of the arteriovenous fistula anastomosis (AVF) often significantly reduces the flow in the AVF. This is even more the case with a 6F introducer. This decrease in flow may increase the risk of per-procedure AVF thrombosis and distort the per-procedure analysis of hemodynamic parameters. Thus, the interpretation of the flow rate becomes tricky, because this flow rate may appear much lower than it will be as soon as the introducer is removed.

Finally, it should be noted that the puncture must be respectful of the vessel that we wish to keep functional. To do this, it must be as frank as possible. However, this is not always easy with superficial veins that can "roll". In practice, local anaesthesia by tumescence is performed about 1 cm from the vein, then the puncture needle passes through the skin 1 cm from the vein and tunnels the path, in this tumescence, before perforating the venous wall. **(Fig. 2)**. The disadvantage of local anesthesia is that it sometimes creates pseudostenosis by spasm of the vein or compression of the vein by the mass effect of the anesthesia fluid.

The choice of the Equipment and its use

Introducer Sheath

The introducer sheath is the device combining dilator and sheath, which will allow the balloon to be introduced and inserted inside the vein.

The choice of the introducer sheath depends on the type of vessel punctured and the type of balloon that will be used.

- Venous or brachial artery puncture
  If the puncture is done on a vein or on the brachial artery, the choice of desilet will be made towards 5F or 6F sheaths (depending on the brand of the balloon), because it allows the use of angioplasty balloons up to 8 mm in diameter.
- Radial artery puncture
  In principle, a 5F desilet is used for the radial artery, with 6F being reserved for radial arteries of "good" size, i.e. at least 4 mm in diameter. In practice, the 5F desirability may be preferred to avoid completely interrupting the arterial flow in the AVF during the procedure.
  Note that 20G needles and 4F sheaths tapered on 0.014" guide are often preferable for puncturing and catheterizing the distal radial artery or small diameter veins. They are replaced by larger introducers depending on the size of the equipment to be used once the initial catheterization has been successfully completed.
- Balloons larger than 8 mm or active balloons: use a 6F or 7F sheath (depending on the brand of balloon).
- 10 mm active balloon: use a 7F to 8F desilets.
- Bare stents: depending on sizes and brands, sheaths from 6F to 8F are required
- Covered stents: they require large 8F or 9F sheaths depending on the self-expanding stents sizes and sheaths lower for balloon-expandable covered stents.

In general, the echo-doppler examination in immediate pre-procedure makes it possible to choose the appropriate balloon and sometimes to anticipate a stenting before starting the procedure. Each manufacturer shall indicate on the balloon or stent package the smallest introducer that can be used to use its equipment.

Navigation equipment

Navigation on the venous part of the AVF is a procedure that requires a little experience. Since the venous network is very superficial, digital compressions can help guide the equipment through the skin, or close collateral vein into which the guidewire should not go.

Aucun article ou résumé dans cette revue ne peut être reproduit sous forme d'imprimé, photocopie, microfilm ou par tout autre procédé sans l'autorisation expresse des auteurs et de l'éditeur. Editions Phlébologiques Françaises
No article or abstract in this journal may be reproduced in the form of print, photocopy, microfilm or any other means without the express permission of authors and the editor. Editions Phlébologiques Françaises

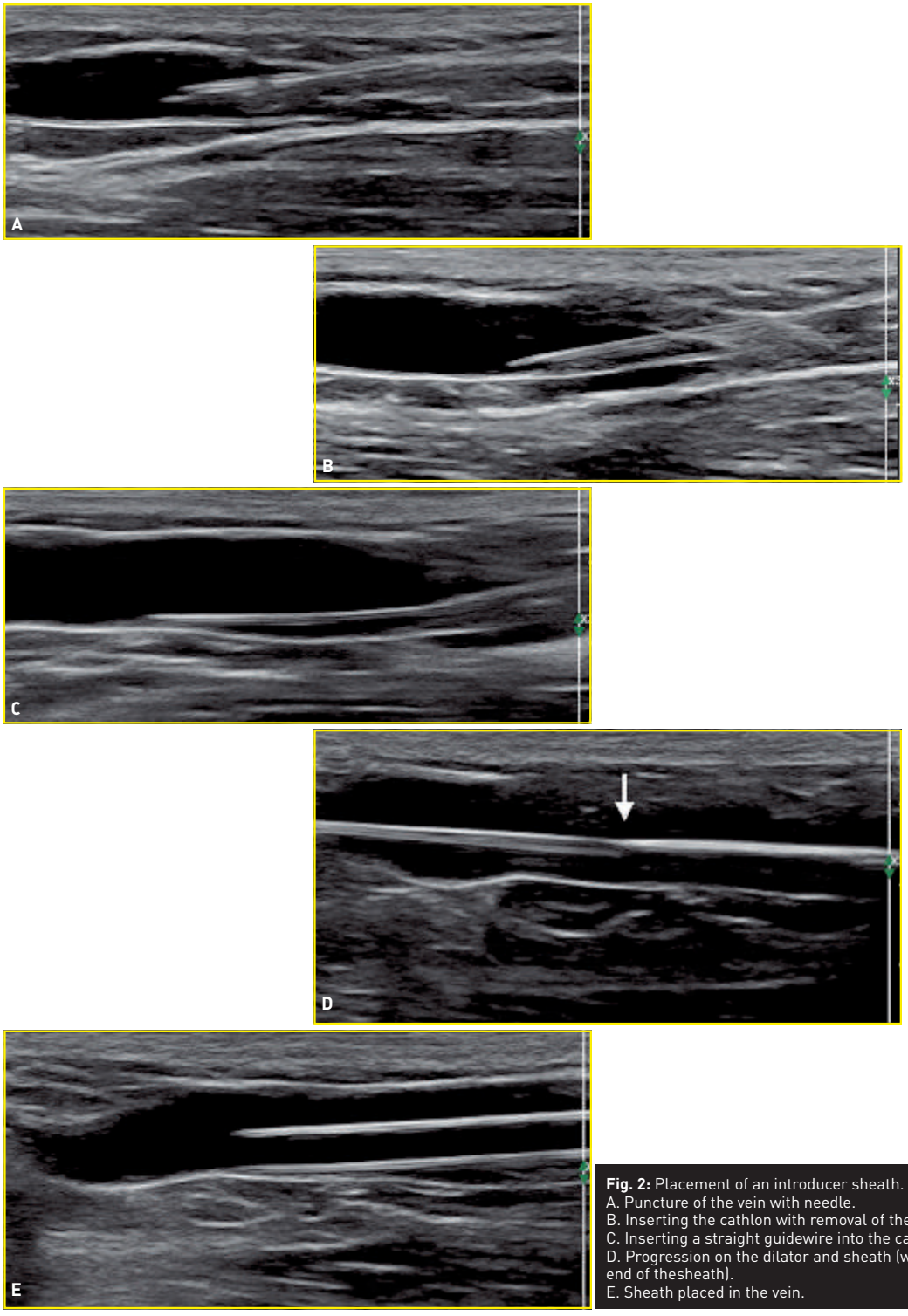

Fig. 2: Placement of an introducer sheath.
A. Puncture of the vein with needle.
B. Inserting the cathlon with removal of the needle.
C. Inserting a straight guidewire into the cathlon.
D. Progression on the dilator and sheath (white arrow: end of thesheath).
E. Sheath placed in the vein.

Aucun article ou résumé dans cette revue ne peut être reproduit sous forme d'imprimé, photocopie, microfilm ou par tout autre procédé sans l'autorisation expresse des auteurs et de l'éditeur. Editions Phlébologiques Françaises
No article or abstract in this journal may be reproduced in the form of print, photocopy, microfilm or any other means without the express permission of authors and the editor. Editions Phlébologiques Françaises

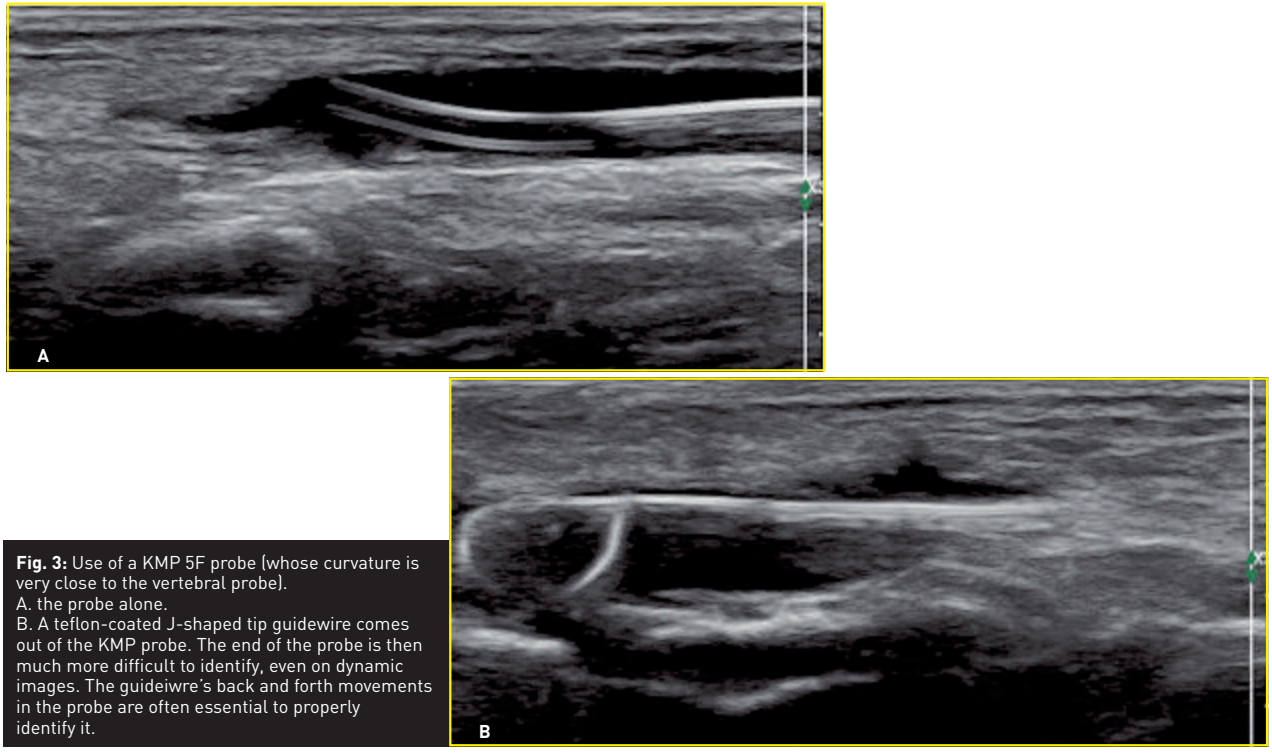

Fig. 3: Use of a KMP 5F probe (whose curvature is very close to the vertebral probe).
A. the probe alone.
B. A teflon-coated J-shaped tip guidewire comes out of the KMP probe. The end of the probe is then much more difficult to identify, even on dynamic images. The guideiwre's back and forth movements in the probe are often essential to properly identify it.

Some difficulties are also likely to arise:
- important sinuosities ;
- stenoses that are difficult to cross (eccentric at the end of an aneurysm or on valves);
- anastomosis difficult to pass, to go into the upstream artery;
- post-dialysis dialysis puncture false-aneurysms.

Navigation is done using 0.035'' guides, the most commonly used being the angled hydrophilic guidewire, which is less traumatic for the vessel walls. A hydrophilic guide can be replaced in a catheter by a metal guide, which is less prone to unintentional exit. Echographically, metal guidewires appear more hyperechoic, thicker than hydrophilic guidewires.

To ensure the progression of the guidewire, a catheter can be used, the end of which can be curved; the first choice for crossing a stenosis is then a 5F vertebral catheter **(Fig. 3)**. Often to cross a straight segment stenosis, the straight tip of the shaft of the angioplasty balloon is sufficient.

For very narrow stenoses, thinner 0.014" guidewires may be used; these guidewires are easy to see on the venous segment, but may be more difficult to visualize in a calcified radial artery, which may encourage a switch to X-Ray guidance. Indeed, radial artery lesions may be underestimated by ultrasound examination and must therefore inspire mistrust.

For the crossing of the anastomosis (in particular radiocephalic, often narrow), an internal mammary 4F catheter will be used instead, in order to push the guidewire in the artery upstream of the anastomosis.

Balloons

Choice of balloon type

Venous angioplasties require "ultra non-compliant" high-pressure balloons with a rupture pressure in the range of 24 to 30 atmospheres (atm) (or bars). They reach the displayed diameter at the so-called "nominal" pressure and maintain this diameter until the rupture pressure. They differ in this respect from compliant balloons whose diameter increases beyond the announced size when the pressure exceeds the nominal. The current trend is to go even higher with the arrival of new very high pressure balloons supporting a pressure of 40 atm.

To date, the value of dilating a stenosis that gave way before reaching 30 atm to 40 atm has not been demonstrated.

Aucun article ou résumé dans cette revue ne peut être reproduit sous forme d'imprimé, photocopie, microfilm ou par tout autre procédé sans l'autorisation expresse des auteurs et de l'éditeur. Editions Phlébologiques Françaises
No article or abstract in this journal may be reproduced in the form of print, photocopy, microfilm or any other means without the express permission of authors and the editor. Editions Phlébologiques Françaises

By way of comparison, the arteries of the lower limbs are most often dilated at nominal pressure, i.e. 8 to 10 atm, rarely at 12 atm.

Finally, although large diameters of balloons are available, recurrent stenosis can sometimes benefit from active balloons, which are more expensive and reimbursed differently depending on the country, whose walls are covered with Paclitaxel, an antimitotic drug that limits myointimal hyperplasia. Again, the clinical benefit of these balloons is not yet strictly demonstrated and will probably depend on the type of the stenosis.

Choice of balloon sizes

The choice of balloon size to dilate venous stenosis involves several parameters.

- The length of time the AVF has been in existence is important, since it is not recommended to dilate a AVF by less than 1 month [13]. The anastomosis may not be completely healed, the risk being the "cataclysmic rupture" of it after balloon inflation.
- A newly created AVF (less than 3 months) and an old AVF (more than 5 years) should be more carefully dilated; the same applies to a AVF that has never been dilated, compared to a AVF that has already been dilated.
- The diameter of the vein immediately before or after the stenosis, without taking into account the measurements of pre- or post-stenotic ectasia, will guide the choice of the balloon diameter. A 1st precautionary angioplasty will be performed at the smallest diameter between the upstream and the immediate downstream.
- Resistant stenosis may be overdilated 1 mm above the diameter and in the case of iterative angioplasty 2 mm above.
- On a vein with a size too irregular to define a reference size, caution should be exercised to dilate to a maximum of 6 mm for a first gesture. It is then the quality of the response to this inflation that will lead to the immediate use of a higher-calibre balloon.

In practice, for veins, 7 mm is the diameter most frequently used in maturation delays in the study by Derderian et al [14]. His team also reported that the group of patients treated with 8 mm was associated with a significant increase in flow a week later.

A diameter of 12 mm can be considered as a maximum, rarely used, for the forearm veins in the case of stenoses located between 2 aneurysmal dilations.

If an angioplasty of the donor artery is required at the same time, a radial artery expands to 4 mm in diameter, a brachial artery to 6 mm in diameter and an axillary to 7 or 8 mm in diameter. Stenting is not recommended on the radial artery and is best above the elbow. [13]

The length of the balloon depends on the length of the stenosis. The balloon during inflation must be able to inflate on either side of the stenosis to anchor itself

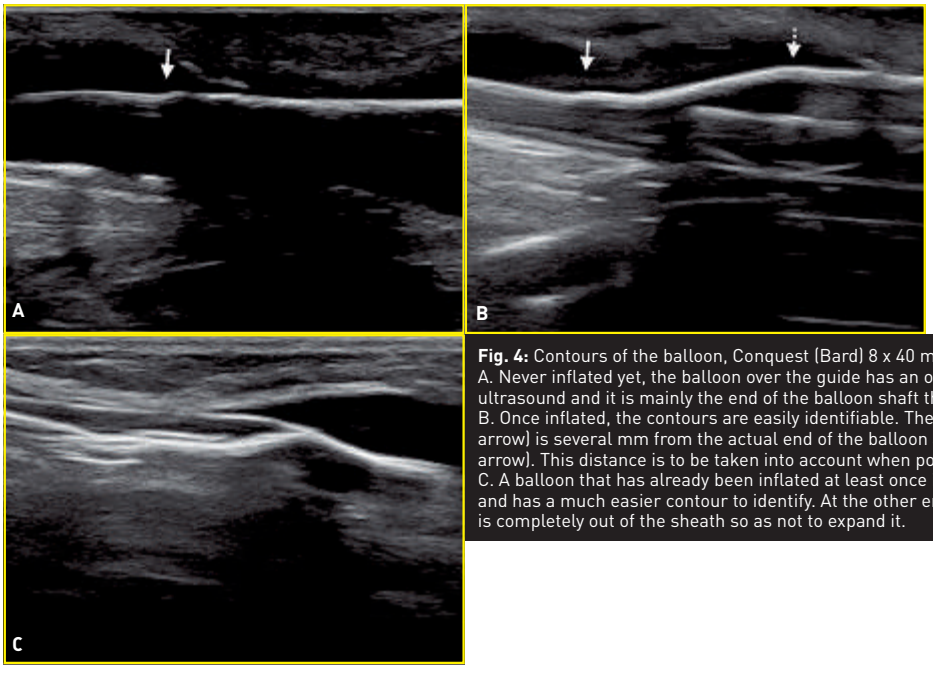

Fig. 4: Contours of the balloon, Conquest (Bard) 8 x 40 mm.
A. Never inflated yet, the balloon over the guide has an outline that is difficult to identify on ultrasound and it is mainly the end of the balloon shaft that is identified (white arrow).
B. Once inflated, the contours are easily identifiable. The end of the balloon probe (white solid arrow) is several mm from the actual end of the balloon at the desired diameter (white dotted arrow). This distance is to be taken into account when positioning the balloon.
C. A balloon that has already been inflated at least once is much less well folded on the probe and has a much easier contour to identify. At the other end of the balloon, check that the balloon is completely out of the sheath so as not to expand it.

Aucun article ou résumé dans cette revue ne peut être reproduit sous forme d'imprimé, photocopie, microfilm ou par tout autre procédé sans l'autorisation expresse des auteurs et de l'éditeur. Editions Phlébologiques Françaises
No article or abstract in this journal may be reproduced in the form of print, photocopy, microfilm or any other means without the express permission of authors and the editor. Editions Phlébologiques Françaises

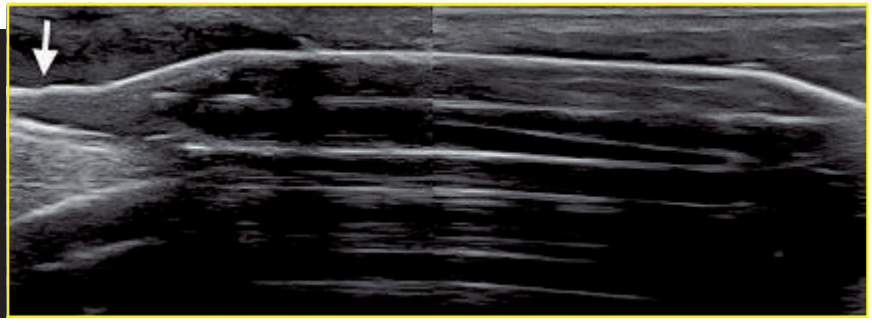

Fig. 5: Conquest balloon (Bard) of 8 x 40 mm over its entire length. Identify the tip of the balloon probe (white arrow) and the balloon cone at each end. Note the repetition echoes behind the balloon throughout its path. The width of the ultrasound probe does not allow to visualize the entire length of the balloon (only 40 mm), here reconstituted with 2 images. In practice, therefore, a dynamic guidance system is required that continuously sweeps the balloon and the vein in longitudinal section to monitor the entire length of the balloon.

without slipping forward or backward, to be able to dilate the stenosis. Balloons 2 cm long, especially ultra non-compliant balls tend to slip, so often a minimum length of 4 cm is very often preferred.

In the case of maturation delays requiring the expansion of long segments, 6 or 8 cm long balloons may be used, which will reduce the number of inflations required to treat the whole lesion.

It should be noted that the duration of inflation is essentially empirical and depends on the schools: some practice short inflations of less than 30 seconds [15], others longer inflations of up to 3 minutes [16].

Positioning the balloon

Before inflation, it is important to check that the angioplasty balloon is correctly positioned **(Fig. 4)**.

It must extend sufficiently beyond each side of the stenosis to allow it to anchor without slipping.

The balloon must also be completely out of the introducer sheath so as not to inflate itself in the sheath.

Particular attention must be paid to anastomosis. There is a risk that the balloon will cover the anastomosis, and into the upstream or downstream artery. It is best to avoid balloons larger than 5 mm protuding into the proximal radial artery. For example, the protusion of a 6 mm balloon into a proximal radial artery of less than 4 mm will lead to a situation of overexpansion that is too great for the artery, with the risk of rupture. However, it can protude into the distal part of the radial artery.

The beginning of inflation is a key time where, as the balloon begins to deploy, its limits are more easily visualized **(Fig. 5)**.

We also see the behaviour of the stenosis on the balloon. If the stenosis imprint on the balloon suddenly disappears as its pressure increases **(hourglass sign, Fig. 6)**, this is a good criterion for success.

It should be noted that in the case of staggered stenoses, they must be treated successively from downstream to upstream [13]. In reverse order, hyperpressure upstream of the balloon, caused by the complete occlusion of the vein, can cause a secondary rupture on a previously dilated site upstream.

Bare and covered stents

The use of stents on the dialysis vein is exceptional, the rule being to perform iterative balloon angioplasties. In principle, a stent is placed in an area that will never be punctured, namely: cephalic vein stick, basilar-brachial junction, prosthetic-venous anastomosis, or venobrachial anastomosis in the context of saphenous or allograft bypass surgery.

The choice is mainly for self-expanding bare stents, which have a radiary force that allows them to remain at the indicated diameter, or failing that, to press firmly against the venous wall. Their positioning is delicate because a number of stents "jump", i. e. move a few mm forward when they are deployed, which requires a readjustment of their position before they are fully deployed. As we begin to deploy them, we must identify the "white triangle", hyperechoic, of the stent that begins to open in order to reposition it as well as possible, if it has advanced [Fig. 7 and 8]. It is preferable to avoid protrusion them into the deep veins, especially the axillary vein, especially in young patients. Indeed, the occlusion of an axillary vein could deprive the patient of another vascular possibility on the same limb with the basilic vein.

Covered stents are used to treat ruptures. It is an emergency equipment that must equip any intervention room. Instead, self-expanding stents should be used. Depending on the diameters and marks, they require larger desilets than the 7F, but it is possible to insert them directly on a guide at the puncture site, without sheath. They can also be used to treat recurrences of intra-stent stenosis [13], see 1st intention in some sites such as cephalic junction or on a prosthetic venous anastomosis in case of bypass surgery.

If they can be placed under ultrasound, they make immediate control difficult, because there is, immediately

Aucun article ou résumé dans cette revue ne peut être reproduit sous forme d'imprimé, photocopie, microfilm ou par tout autre procédé sans l'autorisation expresse des auteurs et de l'éditeur. Editions Phlébologiques Françaises
No article or abstract in this journal may be reproduced in the form of print, photocopy, microfilm or any other means without the express permission of authors and the editor. Editions Phlébologiques Françaises

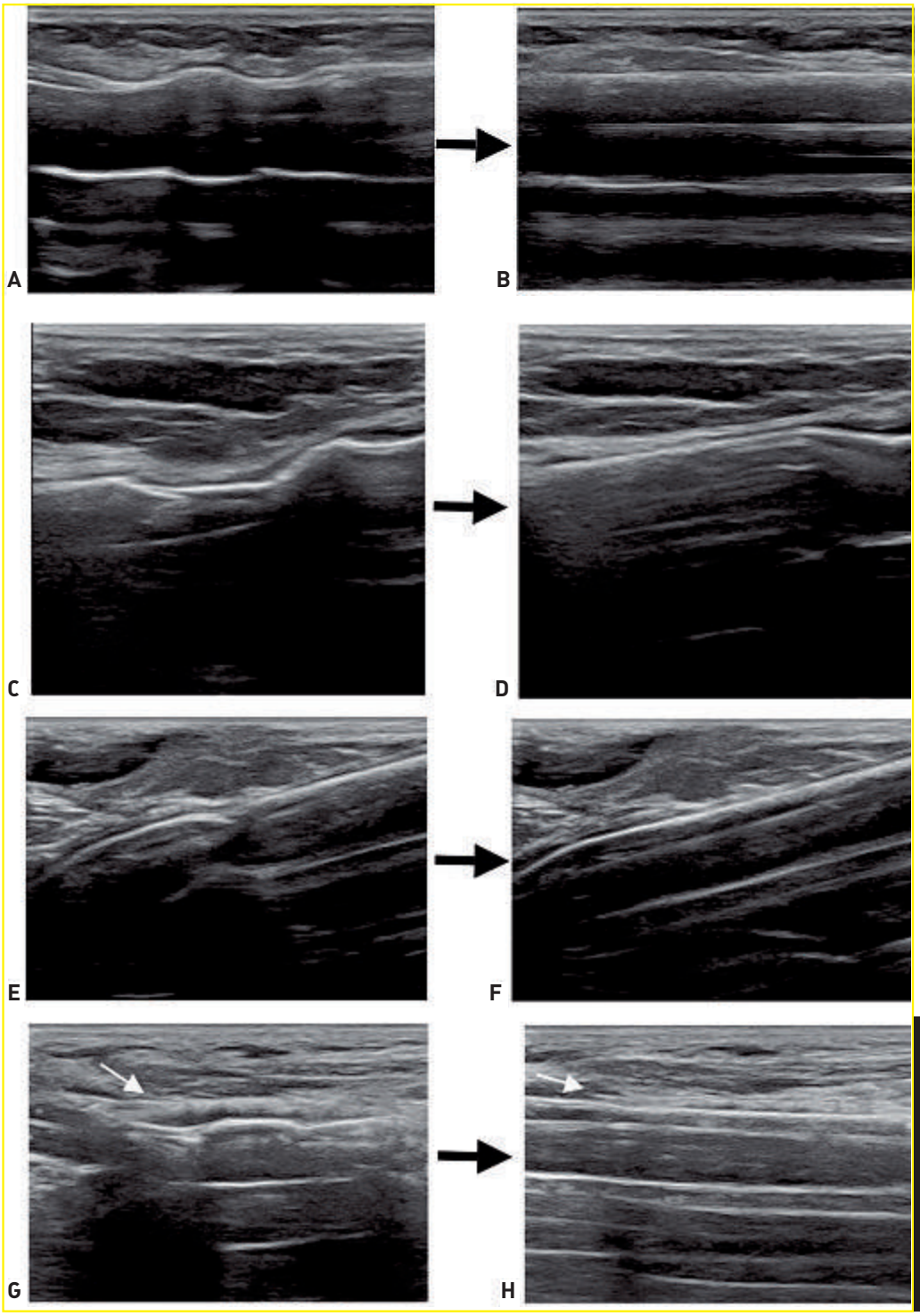

Fig. 6: The hourglass sign appears when the balloon is inflated on either side of the stenosis with the stenosis segment in the middle, which then resists balloon pressure (images A. C. E. and G.). As the pressure increases in the balloon, the stenosis eventually gives way (images B. D. F. and H.) G and H show this hourglass sign on a stenosis at the entrance of a stent (edge of the stent indicated by the white arrow).

Aucun article ou résumé dans cette revue ne peut être reproduit sous forme d'imprimé, photocopie, microfilm ou par tout autre procédé sans l'autorisation expresse des auteurs et de l'éditeur. Editions Phlébologiques Françaises
No article or abstract in this journal may be reproduced in the form of print, photocopy, microfilm or any other means without the express permission of authors and the editor. Editions Phlébologiques Françaises

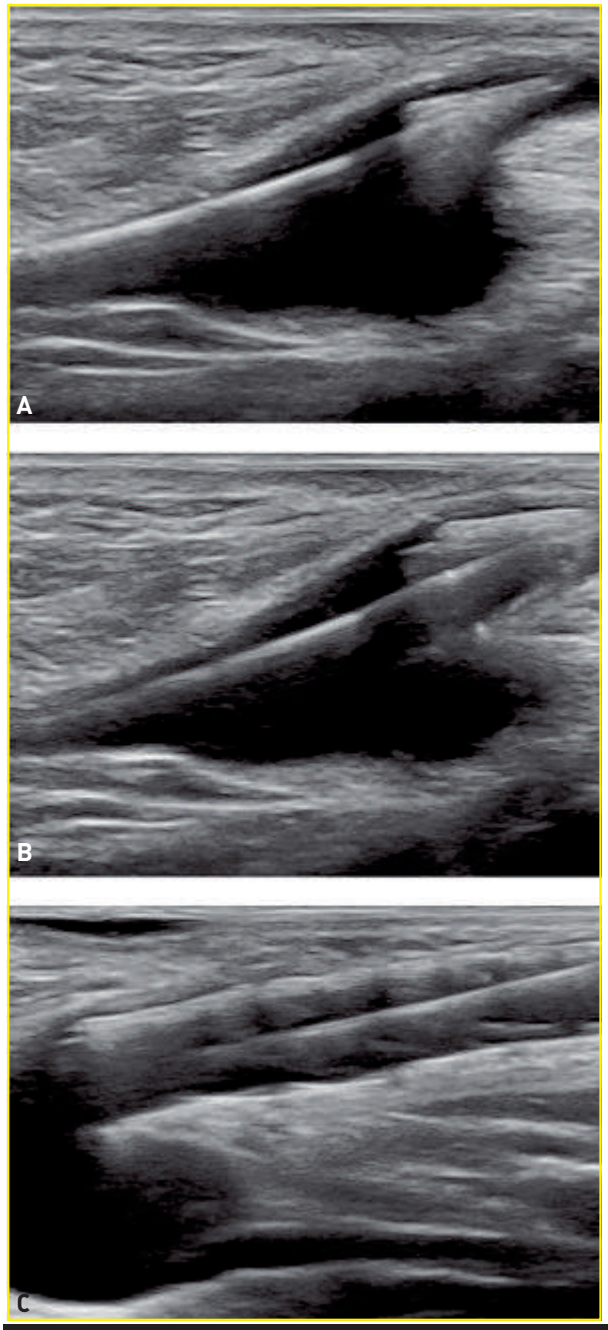

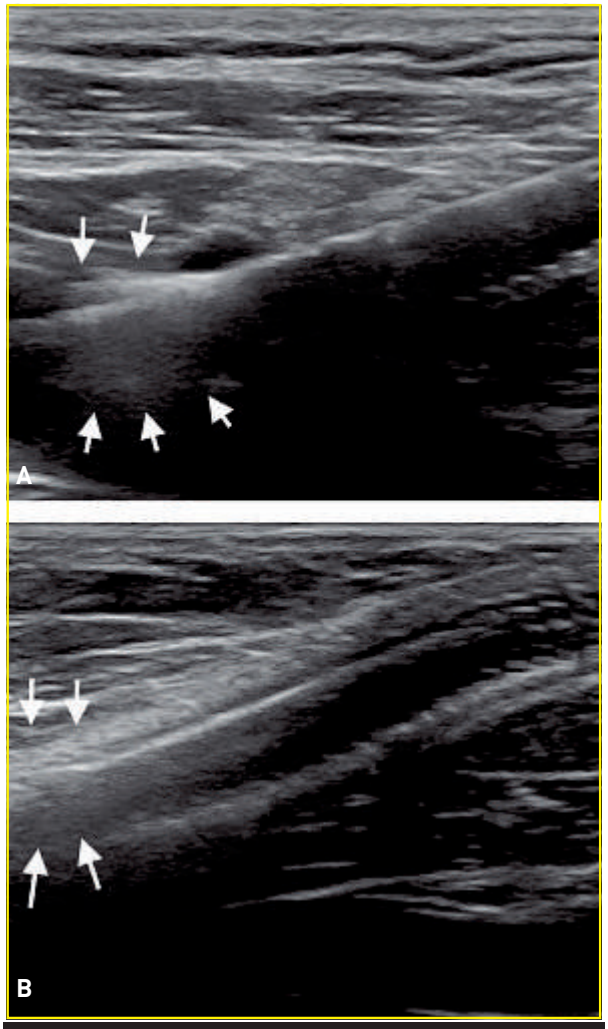

Fig. 8: The white, hyperechoic triangle (delimited by the white arrows) is sometimes difficult to see for a naked stent (here an E-Luminexx (Bard) 8 x 40 mm) (A) and even more so for a Fluency Plus (Bard) covered stent 7 x 40 mm, placed intra-stent (B).

Fig. 7: stenting of the stenosis previously dilated with a single Conquest balloon (Bard) 7 x 40 mm. Here the key point of the gesture is not to protrude the stent into the deep vein.
A. The white, hyperechoic triangle shows that the sheath of the E-Luminexxx (Bard) 8 x 40 mm stent has begun to withdraw and that it is beginning to deploy. At this stage, the stent can still be advanced or, above all, pulled back.
B. The stent starts to press against the venous wall, you can no longer move it forward, it is still possible to pull it back a little.
C. The stent is fully deployed, it still needs a single balloon inflation (this time 8 x 40 mm) to impact it in the venous wall.

Aucun article ou résumé dans cette revue ne peut être reproduit sous forme d'imprimé, photocopie, microfilm ou par tout autre procédé sans l'autorisation expresse des auteurs et de l'éditeur. Editions Phlébologiques Françaises
No article or abstract in this journal may be reproduced in the form of print, photocopy, microfilm or any other means without the express permission of authors and the editor. Editions Phlébologiques Françaises

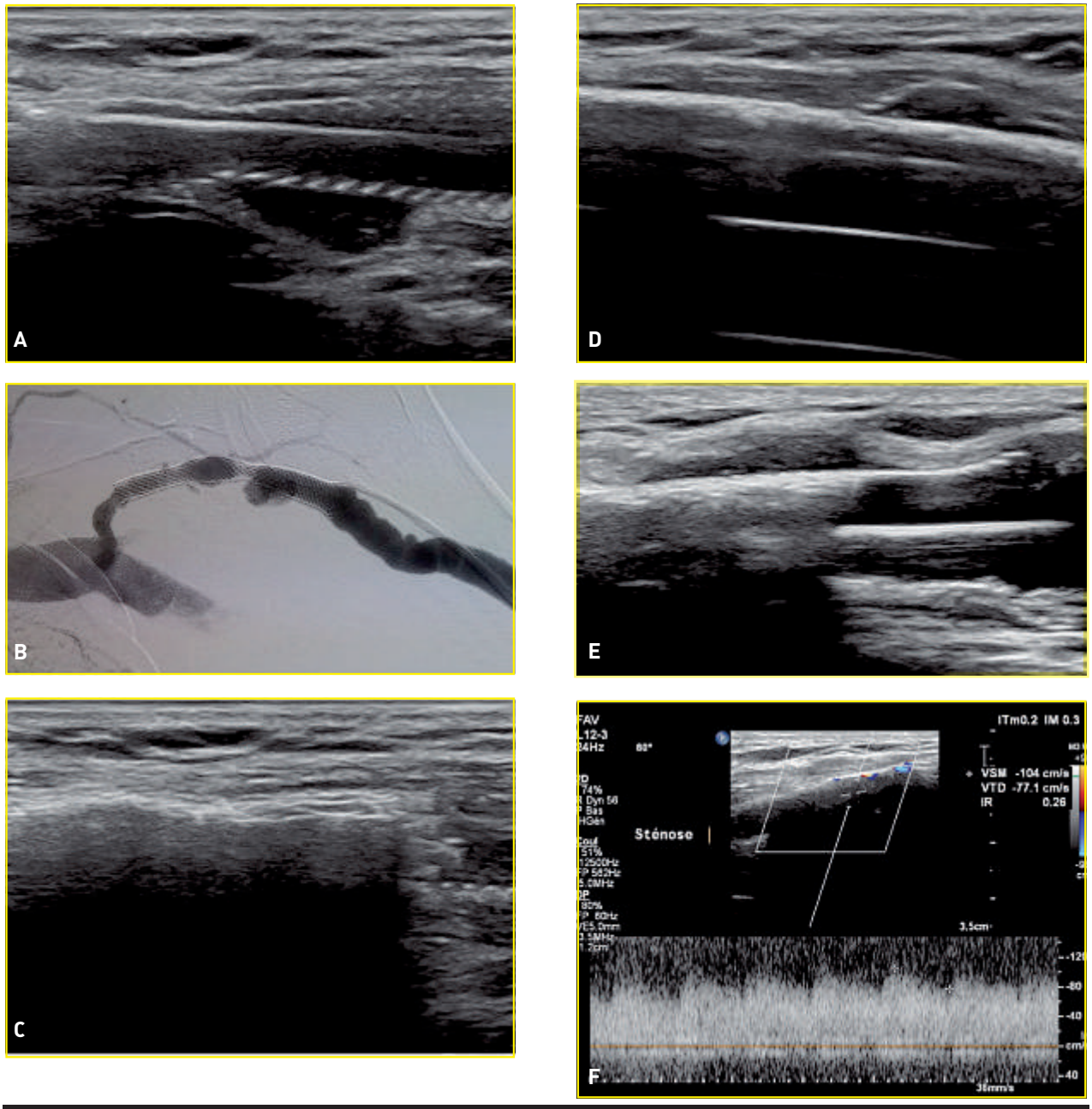

Fig. 9: Brachiocephalic AVF in a 41-year-old patient: recurrence of intrastent stenosis and prestenotic aneurysm at the cephalic vein junction responsible for a venous hyperpressure picture.
A. Ultrasound aspect of tight stenosis and aneurysm.
B. Angiographic control performed in pre-procedure to confirm the lesion.
C. Deployment of the Fluency Plus self-expanding covered stent (Bard) 8 x 40 mm under ultrasound guidance.
D. Remodeling of the covered stent with a single Conquest balloon (Bard) 8 x 40 mm.
E. Echo-doppler control after balloon remodeling: the contour of the stent indicates that the good result of angioplasty.
F. Increasing the pulsed Doppler gain to a high level is essential to record a flow in the newly placed covered stent (No color Doppler filling even at high gain at this stage).

Aucun article ou résumé dans cette revue ne peut être reproduit sous forme d'imprimé, photocopie, microfilm ou par tout autre procédé sans l'autorisation expresse des auteurs et de l'éditeur. Editions Phlébologiques Françaises
No article or abstract in this journal may be reproduced in the form of print, photocopy, microfilm or any other means without the express permission of authors and the editor. Editions Phlébologiques Françaises

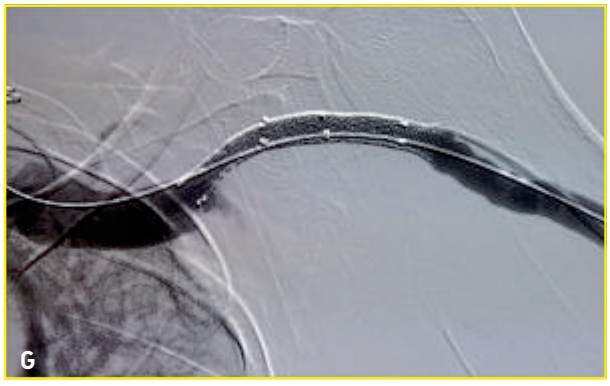

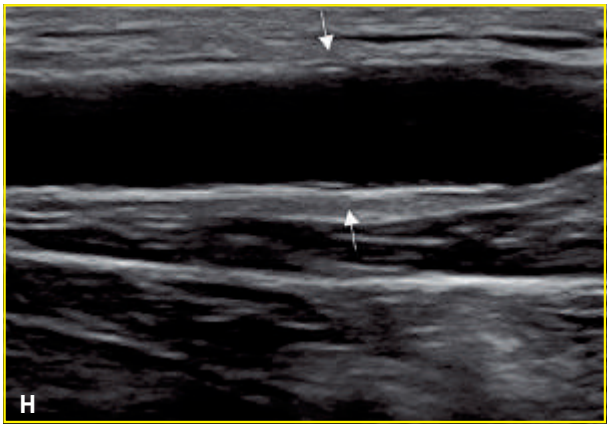

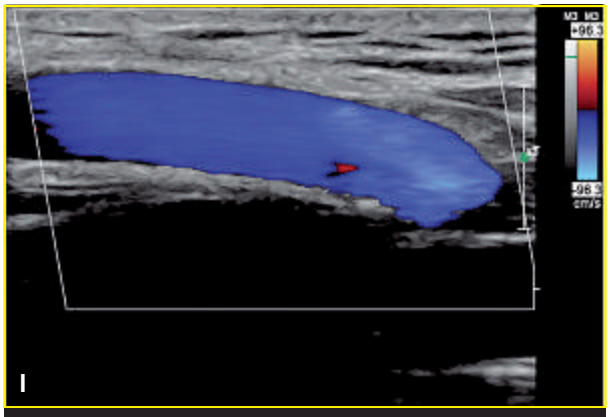

Fig. 9 (continued): Brachiocephalic AVF in a 41-year-old patient: recurrence of intrastent stenosis and prestenotic aneurysm at the cephalic vein junction responsible for a venous hyperpressure picture.
G. angiographic control of the result which confirms the good result on stenosis and exclusion of aneurysm seen on ultrasound.
H. Control at 3 months: the stent is well integrated into the venous wall and there is no longer any interface effect with shadow cone. The end of the stent covered in the bare stent is indicated by the white arrows
I. At 3 months, the easy control with color Doppler shows the absence of aliasing, that could have indicated an early restenosis.

after their installation, an interface effect that causes a shadow cone that is very difficult to penetrate by ultrasound. On the other hand, during the 1-month control, there is no longer any interface effect and the significant shadow cone in covered intrastents disappears **(Fig. 9)**.

End-of-gesture compression

This is really a key point of the procedure that should not be delegated to paramedics, especially in the event of difficult and complicated procedures.

A good compression is done with 1 or 2 fingers; it prevents bleeding but without completely compressing the vein, and therefore, without stopping the circulation in the AVF. Compression occurs until the bleeding stops and lasts an average of 5 to 8 minutes but sometimes longer, especially in patients on anticoagulants and/or anti-aggregants. It is also a time of monitoring where we can verify that the AVF continues to thrill.

Efficacy criteria for angioplasty

The only criterion for angioplasty success found in the literature is residual stenosis <30% diameter reduction, direct extrapolation of arterial angioplasty practices. Obviously, given the irregularities in the size of the venous wall and the difficulty in establishing a reference diameter, this criterion is not very satisfactory.

There are no criteria validated yet on hemodynamic criteria.

Practice and experience teach that:

- **the flow rate is significantly >25% at more than 600 mL/min;**
- **the endoluminal diameter increases;**
- **maximum systolic and telediastolic velocities at the stenosis site decrease;**
- **the resistance index on the brachial artery decreases.**

According to Schwarz et al [17], an AVF with a flow rate of just 600 mL/min. after angioplasty is at risk of recurrence of stenosis or early thrombosis.

These hemodynamic changes are often instantaneous, but not always, especially in cases of wall hematoma on dissection, extravascular compressive hematoma, or vasospasm. The presence of a wall hematoma was not correlated with an increase in flow in the study by DerDerian et al [14], based on ultrasound-guided angioplasties, in the case of delayed maturation. However, it can be seen that in this study, the flow control was performed 1 week later, which may be too early for complete healing of the most important hematomas. Finally, a wall hematoma is considered more predictive of a good response to angioplasty by DerDerian's team.

Aucun article ou résumé dans cette revue ne peut être reproduit sous forme d'imprimé, photocopie, microfilm ou par tout autre procédé sans l'autorisation expresse des auteurs et de l'éditeur. Editions Phlébologiques Françaises
No article or abstract in this journal may be reproduced in the form of print, photocopy, microfilm or any other means without the express permission of authors and the editor. Editions Phlébologiques Françaises

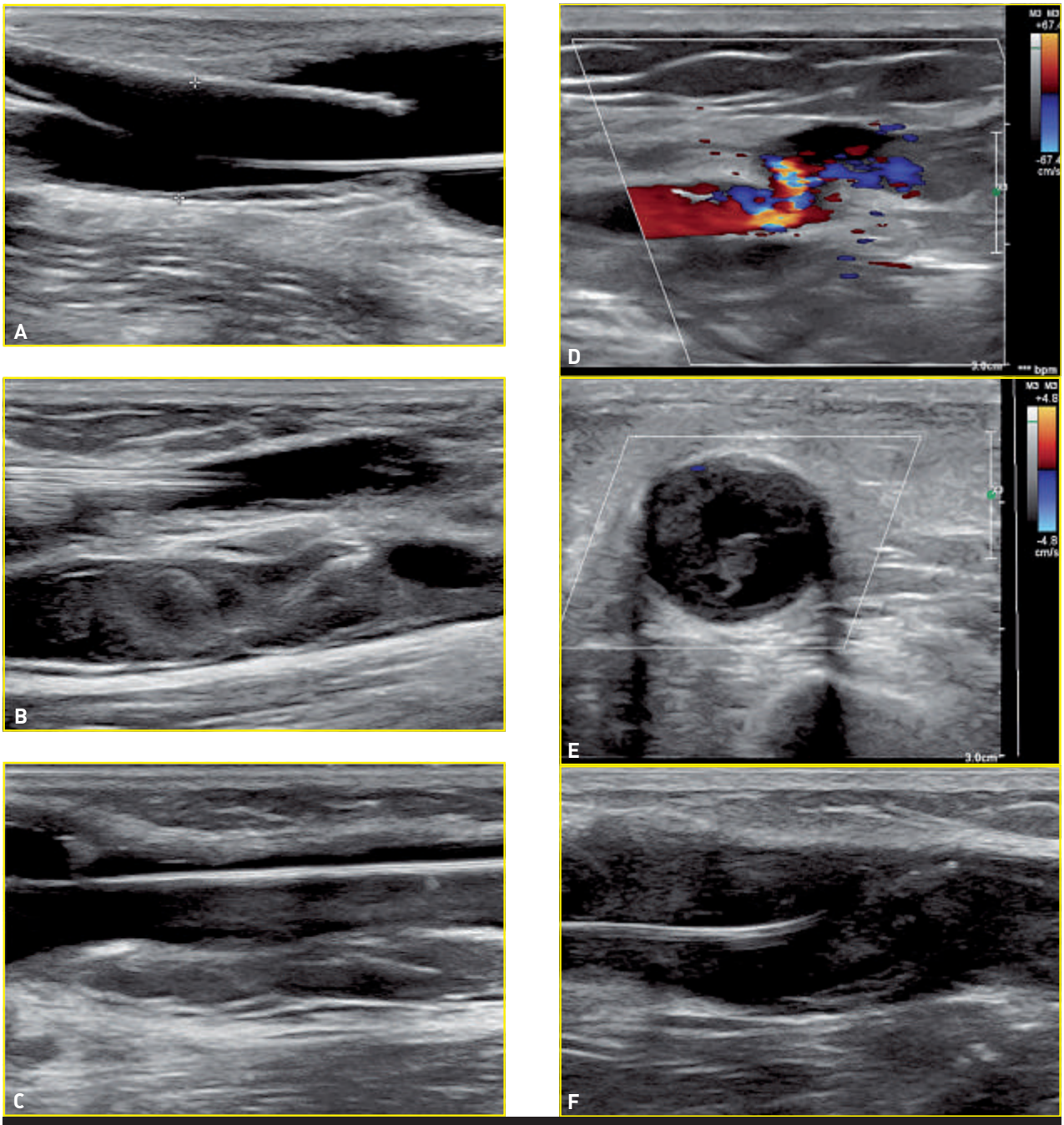

Fig. 10: Complications after angioplasty.
A. Recurrent stenosis at the exit of an 8 mm diameter stent. The teflon guidewire is in place and the edge of the balloon is in the stent, ready for another angioplasty, near the stenosis site.
B. Posterior wall hematoma.
C. Same hematoma as before after a new inflation of the balloon at low pressure which restores a satisfactory circulating lumen.
D. Rupture with an active and rapid leak (high PRF) feeding a false anneurysm
E. Complete, segmental occlusion, paucisymptomatic, from late discovery to 1 month angioplasty.
F. A 5F vertebral probe makes its way on a guide through a complete thrombus, aged 3 months, for recanalization.

Aucun article ou résumé dans cette revue ne peut être reproduit sous forme d'imprimé, photocopie, microfilm ou par tout autre procédé sans l'autorisation expresse des auteurs et de l'éditeur. Editions Phlébologiques Françaises
No article or abstract in this journal may be reproduced in the form of print, photocopy, microfilm or any other means without the express permission of authors and the editor. Editions Phlébologiques Françaises

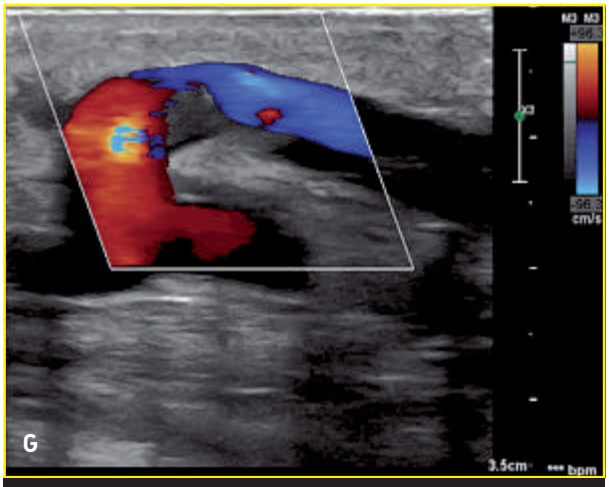

Fig. 10 (continued): Complications after angioplasty.
G. Partial endoluminal thrombus after wall hematoma at D1 of the angioplasty.

Diagnosis and treatment of complications

The wall hematoma (Fig. 10)

The wall hematoma (Fig. 10) must be recognized because it is the most frequent complication: 41% of angioplasty procedures for delayed maturation in the study by Derderian et al in 2014 [18], and even 49% when using large balloons (> 7 mm). According to him, this complication would be completely underestimated by fistulography. It is the result of one or more small ruptures (or dissections) of the dilated wall whose bleeding is endoluminal or intra-parietal. If identified early, it can be treated before it becomes too important because it can be a rare cause of complete AVF thrombosis. It appears as a heterogeneous collection with a hypoechoic dominance in the thickness of the venous wall, or outside it. In case of doubt, the color Doppler shows a color filling defect at its level.

The rupture (Fig. 10)

The rupture (Fig. 10) may occur either by extravasation of blood outside the vein or, if the leak is significant, by circulating false aneurysm. The latter is very easily identifiable in Doppler echo: sign of the "yin-yang" in color Doppler and pendulum flow with systolic peak and holodiastolic reflux in pulsed Doppler. As for the wall hematoma on a small rupture, the most important thing is to identify it quickly, so as to reinflate the balloon at the site concerned, as for the wall hematoma, at 2 to 4 atm for 5 min. If beyond this inflation there is still an active leak, it can be renewed. If 3 inflations of 5 min. cannot ensure watertightness then a covered stent should be used.

The theoretical distinction between wall hematoma and rupture can sometimes appear artificial in practice (Fig. 11).

Vasospasm can be harmful if it is too severe. Contact of the endovascular equipment against the vessel wall can trigger it on the artery or vein. On the artery it can be lifted: by a local injection of nitrated derivative or simply spontaneously in the meantime. Most often, it will be treated by balloon angioplasty, as on the venous side. If the vasospasm becomes complicated by thrombosis, single balloon angioplasty becomes inevitable.

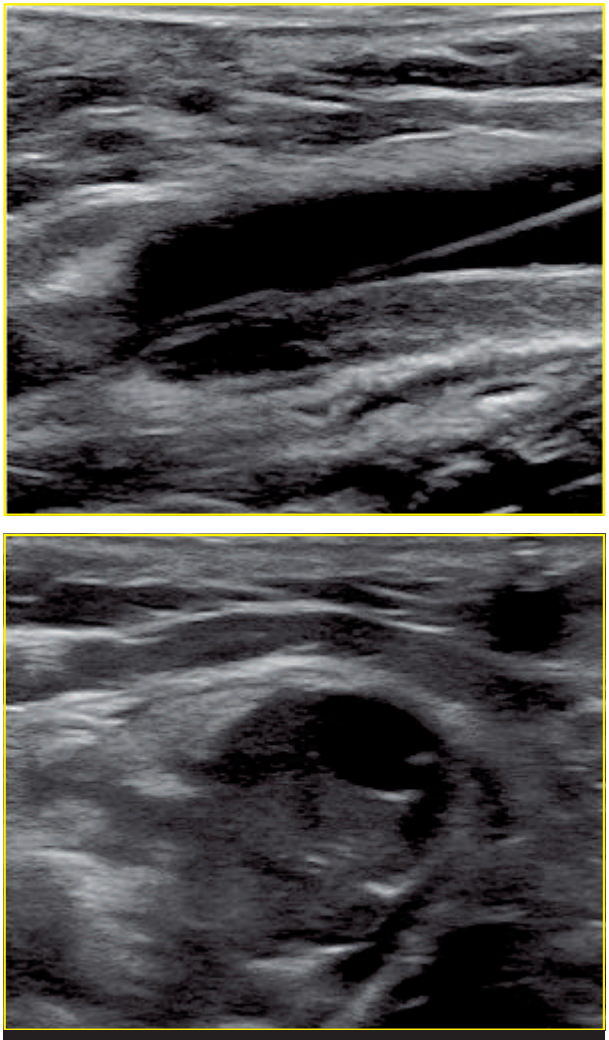

Fig. 11: The wall hematoma (endoluminal hemorrhage), which is quite moderate at first glance, may be much smaller in longitudinal view (A) than in axial view (B), indicating a rupture (extravenous hemorrhage) spontaneously stopped by coagulation.

Aucun article ou résumé dans cette revue ne peut être reproduit sous forme d'imprimé, photocopie, microfilm ou par tout autre procédé sans l'autorisation expresse des auteurs et de l'éditeur. Editions Phlébologiques Françaises
No article or abstract in this journal may be reproduced in the form of print, photocopy, microfilm or any other means without the express permission of authors and the editor. Editions Phlébologiques Françaises

Complete per-procedure vein thrombosis **(Fig. 10)** can complicate different situations: large wall hematoma, large vasospasm, extrinsic compression by a hematoma... An ultrasound-guided unobstruction =recanalization? can be performed [19].

Results

Wakabayashi et al [20] published the largest series of AVF angioplasty procedures under ultrasound. Of the 4869 procedures performed in 7 years, 97.2% were immediately successful and 94.3% were successful at 1 month (94.4% for stenosis and 91.9% for clearance). The reported complication rate is particularly low: 12 cases or 0.2%. The use of scopy was necessary in 55 cases and surgery in 42. 0

Ascher's American team was one of the first to publish on this subject in 2009 [21]. Since then, it has accumulated a large number of patients treated without major complications due to ultrasound guidance [14, 18, 22]. This corresponds to the expected complication rate of <10% for angioplasty of access for dialysis [23].

On the other hand, Gorin's team [24] published a fairly high complication rate with the loss of 4 dialysis accesses over a series of 55 angioplasties. These were non-functional AVFs with delayed maturation.

Advantages and limitations of ultrasound guidance

The practice of angioplasty on the dialysis vein under ultrasound guidance remains an exception in 2019. The use of X-rays with contrast agents is still the dominant practice. However, ultrasound guidance has many advantages and some disadvantages.

Avantages

The absence of the use of iodinated contrast agents makes it possible to ensure the maintenance of dialysis AVF even before the start of dialysis, and without the risk of rushing the patient to dialysis.

For patients with residual renal function, it helps to preserve it. However, it must be acknowledged that conventional radiology has made efforts towards limiting irradiation dose but also the volumes of contrast products injected [25]. The opportunity to avoid X-rays completely is always beneficial for the patient because these angioplasties may have to be repeated several times a year, and this irradiation is combined with that of other examinations prescribed to explore by renal disease or often numerous comorbidities (coronary artery disease, arteriopathy, etc.).

For the practitioner, ultrasound also limits their exposure to X-rays and makes it possible to work more comfortably, without a lead apron. Ultrasound makes it possible to have a nearly complete imaging of the dialysis approach even before the beginning of the procedure, which makes it possible to anticipate the choice of puncture site and equipment.

The exploration of the AVF starts even before the sheath is inserted, which makes it easier to place it directly into the right collateral, or by avoiding certain obstacles for example. Each step of the procedure can be monitored without having to ensure "X-ray economy".

Finally, ultrasound allows a "magnifying glass" image of the approach: of the vascular lumen, but also of the wall of the vessels and perivenous tissues.

Ultrasound-based equipment is significantly less heavy and less expensive than that required for X-rays (in addition to the device, there is also the expensive leaded environment).

A wider dissemination of the gesture is therefore possible. Thus, in the USA, some procedures are already carried out in private practices in the USA [22, 21], but it is also conceivable that they could be developed in dispensaries, far from expensive heavy centres, in economically disadvantaged countries.

Limitations

Calcifications (of the arterial side but also rarely of veins with calcium concretions) are an impassable obstacle to complete visualization of the approach. In particular, mistrust must be maintained for calcified radial arteries.

The arch of the cephalic vein may be difficult to visualize correctly if it is located behind the clavicle (a rare configuration) or if its size is reduced. By extension, the examination of deep veins (subclavian and brachiocephalic venous trunk) is often insufficiently reliable for the diagnosis of stenosis and consequently for their treatment. The team from Wakabayashi [20] describes the treatment of these lesions using a microconvex probe. However, no specific information is given on this subgroup of patients, and the safety of the procedure in this indication is questionable.

Finally, a slow leak on iatrogenic rupture can sometimes be more difficult to visualize in Doppler echo than by opacifying it with contrast agent.

The overall picture can sometimes be lacking to understand the complex drainage of some advanced or complicated AVFs, or to monitor the position of the end of a guidewire away from the area of interest. The overall image obtained by scopy is also a support that can be understood by everyone, useful for communication and multidisciplinary discussion between doctors and surgeons to determine the best therapeutic strategy.

Aucun article ou résumé dans cette revue ne peut être reproduit sous forme d'imprimé, photocopie, microfilm ou par tout autre procédé sans l'autorisation expresse des auteurs et de l'éditeur. Editions Phlébologiques Françaises
No article or abstract in this journal may be reproduced in the form of print, photocopy, microfilm or any other means without the express permission of authors and the editor. Editions Phlébologiques Françaises

Finally, since a hand is required to hold the probe, it becomes imperative to work with an operating aid. Under X-rays, imaging is controlled with pedals allowing the angioplastician to work alone.

Conclusion

Angioplasties of the dialysis vein can, for the vast majority of them, be performed exclusively and entirely under ultrasound guidance.

While the first publications on this subject date back more than 13 years, the use of ultrasound for dialysis AVF angioplasty is still confidential. The safety of ultrasound against X-rays, its lower cost and lighter equipment make it a logical evolution of the procedure.

Nevertheless, today, the safety of the technology is still regularly questioned by its critics. Also new data are needed to definitively remove the technique from this debate.

In a second step, other studies may help to improve its effectiveness, for example, by identifying ultrasound criteria associated with early restenosis.

Thanks to Dr Luc Turmel-Rodrigues for his proofreading and corrections.

Références

[1] Ene-Iordache B., Cattaneo L., Dubini G., Remuzzi A. Effect of anastomosis angle on the localization of disturbed flow in 'side-to-end' fistulae for haemodialysis access, Nephrol Dial Transplant 2013 Apr; 28(4): 997-1005.

[2] Robbin ML., Oser RF., Allon M., Clements MW., Dockery J., Weber TM., Hamrick-Waller KM., Smith JK., Jones BC., Morgan DE., Saddekni S. Hemodialysis access graft stenosis : US detection. Radiology. 1998 Sep; 208(3): 655-61.

[3] Vardza Raju A., Kyin May K., Htet Zaw M., Capistrano Canlas C., Hannah Seah M., Menil Serrano C., Hartman M, Ho P. Reliability of Ultrasound Duplex for Detection of Hemodynamically Significant Stenosis in Hemodialysis Access. Ann Vasc Dis. 2013; 6(1): 57-61.

[4] Fahrtash F., Kairaitis L., Gruenewald S., Spicer T., Sidrak H., Fletcher J., Allen R., Swinnen J. Defining a significant stenosis in an autologous radio-cephalic arteriovenous fistula for hemodialysis. Semin Dial. 2011 Mar-Apr; 24(2): 231-8.

[5] Bay WH., Henry ML., Lazarus JM., Lew NL., Ling J., Lowrie EG. Predicting hemodialysis access failure with color flow Doppler ultrasound. Am J Nephrol. 1998; 18(4): 296-304.

[6] Vascular Access 2006 Work group. Clinical practice guidelines for vascular access. Am J Kidney Dis. 2006 Jul; 48(Suppl 1): S176-247.

[7] Ko SH., Bandyk DF., Hodgkiss-Harlow KD., Barleben A., Lane J 3rd. Estimation of brachial artery volume flow by duplex ultrasound imaging predicts dialysis access maturation. J Vasc Surg. 2015 Jun; 61(6): 1521-7.

[8] Tessitore N., Mansueto G., Lipari G., Bedogna V., Tardivo S., Baggio E., Cenzi D., Carbognin G., Poli A, Lupo A. Endovascular versus surgical preemptive repair of forearm arteriovenous fistula juxta-anastomotic stenosis : analysis of data collected prospectively from 1999 to 2004. Clin J Am Soc Nephrol. 2006 May; 1(3): 448-54.

[9] Turmel L. Radiologie diagnostique et interventionnelle des accès artério-veineux pour hémodialyse Paris : Springer-Verlag France; 2012.

[10] DerDerian T., Hingorani A., Ascher E., Marks N., Jimenez R., Aboian E., Jacob T., Boniscavage P. To BAM or not to BAM?: A closer look at balloon-assisted maturation. Ann Vasc Surg. 2013 Jan; 27(1): 104-9.

[11] Elramah M., Boujelbane L., Yevzlin AS., Wakeen M., Astor BC, Chan MR. Dialysis access venous stenosis: treatment with balloon angioplasty 30-second vs. 1-minute inflation times. 2015 Jan; 19(1): 108-14.

[12] Forauer AR., Hoffer EK., Homa K. Dialysis access venous stenoses : treatment with balloon angioplasty--1- versus 3-minute inflation times. 2008; 249: 375-381.

Aucun article ou résumé dans cette revue ne peut être reproduit sous forme d'imprimé, photocopie, microfilm ou par tout autre procédé sans l'autorisation expresse des auteurs et de l'éditeur. Editions Phlébologiques Françaises
No article or abstract in this journal may be reproduced in the form of print, photocopy, microfilm or any other means without the express permission of authors and the editor. Editions Phlébologiques Françaises

[13] Schwarz C., Mitterbauer C., Boczula M., Maca T., Funovics M., Heinze G., Lorenz M., Kovarik J, Oberbauer R. Flow monitoring : performance characteristics of ultrasound dilution versus color Doppler ultrasound compared with fistulography. Am J Kidney Dis. 2003 Sep; 42(3): 539-45.

[14] DerDerian T., Hingorani A., Boniviscage P., Carollo A., Ascher E. Acute complications after balloon-assisted maturation. Ann Vasc Surg. 2014 Jul; 28(5): 1275-9.

[15] Wakabayashi M., Hanada S., Nakano H., Wakabayashi T. Ultrasound-guided endovascular treatment for vascular access malfunction : results in 4896 cases. 2013 Jul-Sep; 14(3): 225-30.

[16] Ascher E., Hingorani A., Marks N. Duplex-guided balloon angioplasty of failing or nonmaturing arterio-venous fistulae for hemodialysis : a new office-based procedure. 2009 Sep; 50(3): 594-9.

[17] Gallagher JJ., Boniscavage P., Ascher E., Hingorani A., Marks N., Shiferson A., Jung D., Jimenez R., Novak D., Jacob T. Clinical experience with office-based duplex-guided balloon-assisted maturation of arteriovenous fistulas for hemodialysis. 2012 Oct; 26(7): 982-4.

[18] Aruny JE., Lewis CA., Cardella JF., Cole PE., Davis A., Drooz AT. Quality improvement guidelines for percutaneous management of the thrombosed or dysfunctional dialysis access. J Vasc Interv Radiol. 2003 Sep; 14(9 Pt 2): S247-53.

[19] Gorin DR., Perrino L., Potter DM., Ali TZ. Ultrasound-guided angioplasty of autogenous arteriovenous fistulas in the office setting. J Vasc Surg. 2012 Jun; 55(6): 1701-5.

[20] Kian K., Wyatt C., Schon D., Packer J., Vassalotti J., Mishler R. Safety of low-dose radiocontrast for interventional AV fistula salvage in stage 4 chronic kidney disease patients. Kidney Int. 2006 Apr; 69(8): 1444-9.