

Chapter 10

Echo Skin Marking of varicose veins before traditional surgery

Jean-Jérôme Gueux

Abstract

Even if classic open varicose vein surgery is no longer the gold standard for treating varicose veins in the lower limbs, careful marking is the key to a good result.

We will explain why its good practice is still necessary and how to perform it using a vascular Doppler ultrasound probe.

Introduction

Endovenous chemical, thermal or other ablative techniques and techniques without local anesthesia or tumescence (glue, MOCA...) have gradually replaced conventional open surgery (COS) for varicose veins often referred to as "crossectomy-stripping" that is to say: ligation of the sapheno-femoral junction (SFJ) + the sapheno-popliteal junction (SPJ) + stripping +/- phlebectomies +/- ligation of perforating veins.

Even if it is difficult to say today what is the best method of treating varicose veins, the COS is no longer recommended as a first-line treatment by the various international consensus and guidelines, NICE [1] and others.

Nevertheless, this technique is still used by some operators and may be useful or necessary in some cases: varicose vein size, patient request, unavailability of other methods, budget restrictions.

In these cases, the surgical procedure is easier and more effective [2], if the surgical marking is well conducted, accurate and informative

As with open vascular surgery procedures, the crossectomy stripping technique should not be lost, even if fewer and fewer surgeons regularly perform it.

In fact, the COS – when amended to become the "open mini-invasive surgery" – is credited with short – and

long-term results comparable to laser and radiofrequency [3].

The skin echo-marking, which has long been a major specificity of vascular physicians [4], must not therefore disappear from their technical know-how.

Here we describe some principles and give technical tips.

The place of echo skin marking

The echo skin marking will always be preceded by a first consultation with interrogation, clinical examination and complete venous Doppler ultrasound review (superficial, perforating, deep including ilio-caval), with paper or electronic mapping.

It will also be preceded by a preliminary interview with the practitioner in charge of the surgical procedure, during which the method will be presented and the patient's informed consent will be obtained.

In practice, the marking must be done in the morning or the day before the intervention, before the disinfecting shower.

The vascular doctor performing the marking must have a good knowledge of the surgeon performing the procedure (and his habits) and vice versa, the information provided must be useful and understandable, it is preferable that both agree on this point!

Echo Skin Marking of varicose veins before traditional surgery

Echo-tagging replaces manual marking in the pre-anaesthesia room or worse, in the corridor, by simple inspection and palpation.

Only the elements relevant to the procedure will be reported on the skin:

- It will therefore be necessary to locate and mark only those pathological veins whose removal or surgical treatment is necessary and requested;
- Smaller varicose veins intended for subsequent complementary treatment (sclerotherapy, Muller) will not be marked;
- A fortiori, because of the risk of error, normal veins should not be depicted.

This shows that collaboration between vascular physician and vascular surgeon must be as strategic as it is technical/tactical and that a relationship of trust is necessary.

Echo skin marking is also used prior to Muller's phlebectomy and ASVAL (Ambulatory Selective Varices Ablation under Local anesthesia). In these cases, it is usually carried out by the operator himself.

Echo-tagging can also be used to document the case, whether for forensic or didactic reasons, or to secure a delicate thermal (or other) endovenous ablation procedure.

Echo skin marking is finally an excellent way to avoid a side error.

What to mark?

In the very first place, the need to identify and clearly mark the precise location of the incontinent junctions for which ligation is planned should be noted, paying attention to the anatomical variants, particularly frequent at the sapheno-popliteal level.

If necessary, if the skin marking cannot be precise enough, a precise diagram or written description of the junction (height, face, common trunks, etc.) should be added. (Fig. 1, 2, 3, 4)

Incontinent intra-fascial trunks should then be identified by noting eventually: (Fig. 2, 3, 4)

- Their diameters;
- The diameters of their pseudo-aneurysmal ectasias [because they can be an obstacle to the passage of the stripper]; their possible bayonet trajectories;
- Their true and false duplications;
- The crossing through the saphenous fascia must be clearly indicated on the marking;

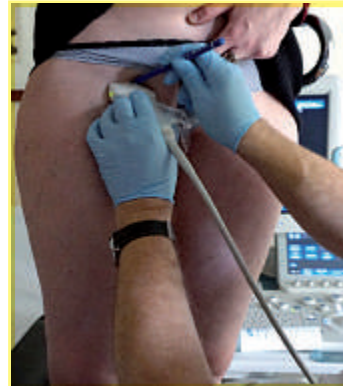

Fig. 1: Localization of the sapheno-femoral junction (SFJ).

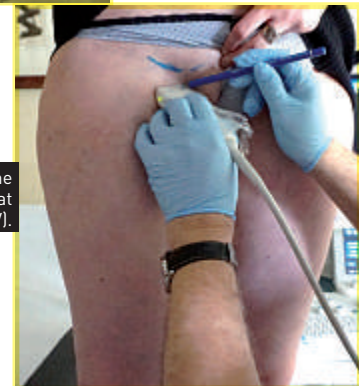

Fig. 2: Localization of the pre-terminal great saphenous vein (GSV).

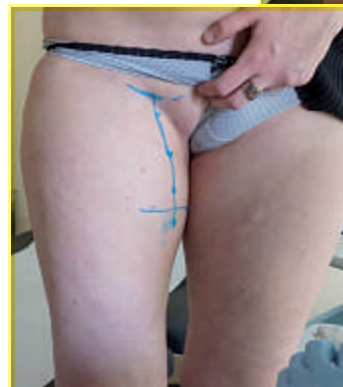

Fig. 3: Localization of the location of the crossing of the cribriform fascia by the GSV stock.

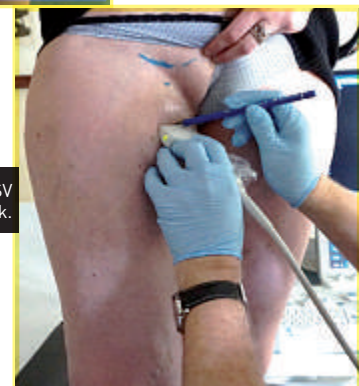


Fig. 4: Marking of the GSV trunk.

- For this reason, a different color marker can be used for intra- and extra-facial trunks;
- If the saphenous trunk is also insufficient under the butt end of the extra-fascial tributary, it should be marked precisely and with a different color, if both are to be treated.

The main extra-fascial tributaries (those whose removal is desired will then be marked):

- With their sinuosities; (Fig. 5)
- Their confluences with each other and with the trunks; etc...
- These are usually the most complicated to score.

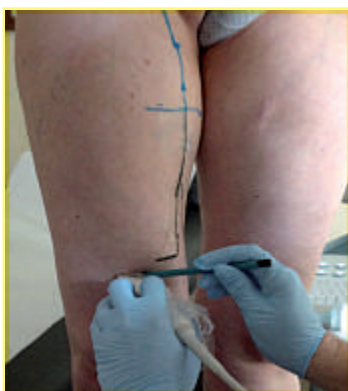

Fig. 5: Marking of veins sinuosities.

The marking of the perforating veins:

- Is of particular importance because they are often a source of recurrence and are difficult to find intraoperatively (indeed, in a limb, unlike in a hollow organ, the sonographer sees everything, while the surgeon only sees what he has opened and dissected);
- Perforators are often difficult to locate, and even more, so to transfer to the skin due to a sometimes long, recurrent, winding path;
- It is necessary to specify where they enter the surface plane and their path to the superficial vein they feed;
- Ideally, a millimeter incision should be made to allow them to be caught on the hook;
- Of course, not all perforators should be removed, and their pathogenicity should be estimated before proposing them for excision, a point that arises from the Doppler ultrasound examination and left to the discretion of the vascular physician;
- In the femoral canal, almost all incompetent perforators are pathogenic, as well as in the popliteal fossa;
- It is much less obvious in the lower third of the medial leg face (e. g. with regard to the Cockett's perforating veins: leak or re-entry or both?).

How to test competence and measure diameters?

This is no difference between the maneuvers performed during the echo Doppler venous examination of the lower limbs and the mapping. The patient stands on a phlebological stepladder and will remain so for the duration of the marking.

In rare cases of tissue flaccidity (after significant weight loss) it may be useful to check that there is no major change in the vein/skin relationship between standing and lying down.

Muscle mass compression/relaxation and Valsalva (or even the Paraná maneuver) are used to demonstrate color Doppler reflux and measure its duration in pulsed Doppler in case of doubt.

Thrombosed and/or partially re-permeabilized veins will be indicated with a different graphic code.

The diameters are measured and transferred to the skin if they are of interest for the surgeon.

Personally, in order to avoid some of the measurement error due to the pressure of the probe, we take a *diagonal gauge* as shown below. (Fig. 6)

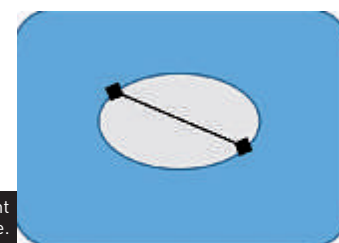


Fig. 6: Measurement of the diagonal gauge.

How to locate the vein and mark it on the skin?

The main practical problem is the incompatibility between indelible markers (volatile solvent) and ultrasound gel (aqueous solvent). The use of K permanganate in saturated solution does not allow us any precision or colour code, we have abandoned it for a long time.

We use a *primary marking* technique with *water-soluble coloured pencils* (also called *watercolour pencils*, various brands offer some) which draw very well on the skin in the ultrasound gel, *reinforced in a second step by a trace by indelible colored markers* (preferably dark, the black lasts several days).

It is necessary to carry out a stamping drying operation (not wiping) with paper tissues in between. The technique

Echo Skin Marking of varicose veins before traditional surgery

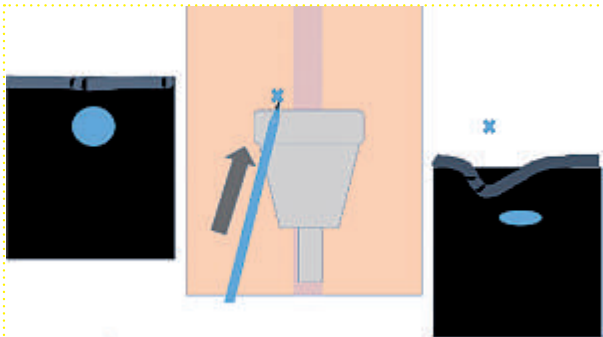


Fig. 7: Since the pencil is in contact with the probe and the skin, the pressure of the pencil tip results in lateral deflection, so the axis of the vein has not been found.

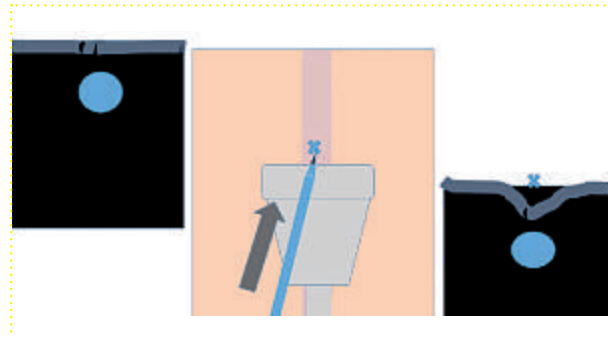


Fig. 8: The pressure of the pencil tip causes a symmetrical and centered deflection on the vein: the axis of the vein has therefore been found and it can be marked on the skin.

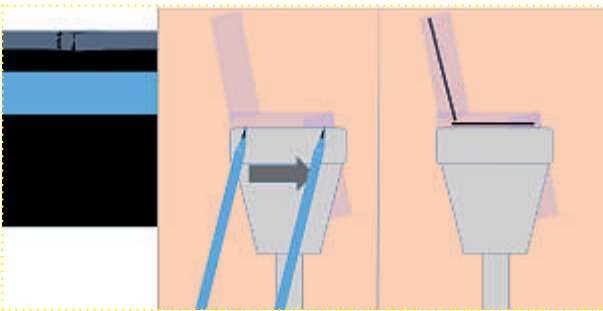


Fig. 8 bis: In cross-section (of the limb) the longitudinal vision (of the vein) allows - with a slight parallax correction - to draw a bayonet path, as well as for the sinuities.

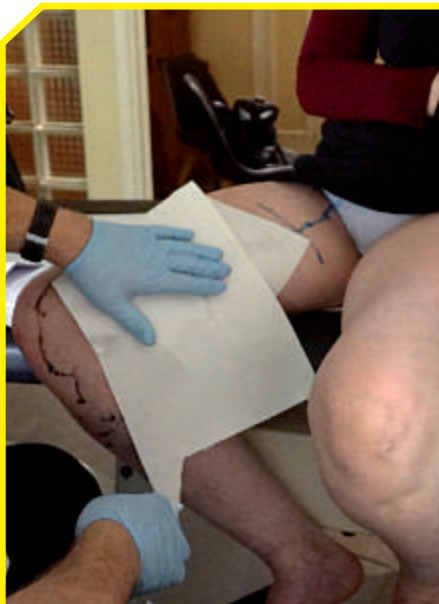

Fig. 9: Wiping the ultrasound gel.

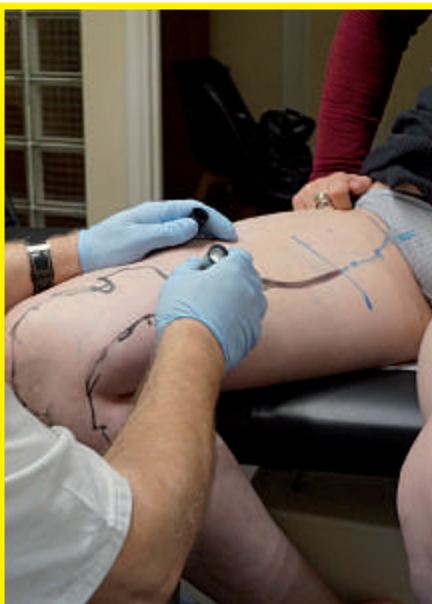


Fig. 10: Overmarking with a felt pen.

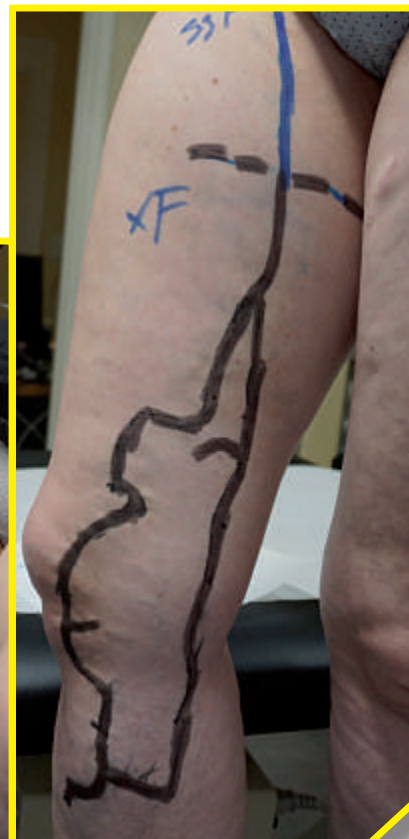

Fig. 11: Final phase of the echo-marking.

is illustrated in the photos of a marking of the great saphenous vein.

The use of pencils makes it possible to locate the axis of the veins with millimeter accuracy.

In cross-section (of the vein), with the pencil resting on the probe, a slight push is made, a clear movement is visible in real time on the screen. If it is lateral, the pencil is moved so that a pressure on the pencil tip causes a symmetrical crushing in front of the vein, the axis of the vein is directly indicated on the skin. **(Fig. 7 and 8)**

It is more difficult to report bayonet trajectories and sinuosities **(Fig. 8 bis)**, especially since the varicose veins are in 3D but the ultrasound image is in 2D in depth and it is necessary to draw a 2D surface marking.

When all the varicose veins and venous trunks to be removed have been noted in pencil, the area to be marked is gently stamped with absorbent paper (it is easier and faster if you have been parsimonious

with the ultrasound gel); it is then easy to redraw with a wide felt pen, the same, with additional information such as diameters, crossing fascias, etc.

The remaining pencil drawings can then be removed, otherwise they will leave during the preoperative shower. A photograph is then taken and added to the file. **(Fig. 9, 10, 11)**

In conclusion

The echo skin marking of varicose veins before traditional surgery is no longer a daily procedure for vascular doctors. However, it must be done perfectly because it is the only surgeon's guide. It indicates which veins should be removed and where to find them.

References

- [1] Varicose veins: diagnosis and management, NICE guidelines [CG168] Published date: July 2013.
- [2] Ikponmwosa A., Bhasin N., Weston MJ., Berridge DC., Scott DJ. Outcome following saphenopopliteal surgery: a prospective observational study. *Phlebology* 2010 Aug; 25(4):174-8.
- [3] Rasmussen L., Lawaetz M., Serup J., Bjoern L., Vennits B., Blemings A., Eklof B. Randomized clinical trial comparing endovenous laser ablation, radiofrequency ablation, foam sclerotherapy, and surgical stripping for great saphenous varicose veins with 3-year follow-up. *J Vasc Surg Venous Lymphat Disord* 2013 Oct; 1(4):349-56.
- [4] The vascular doctor's letter, *SFMD ed.* 2011; 16: pp. 17-49.