

# Chapter 21

## In which cases ultrasonic methods are they insufficient in the evaluation of venous disease of the lower limbs?

Oscar Maleti

### Abstract

Until the 1980s, radiological methods (phlebography) and volumetric methods (plethysmography) represented the techniques for investigating venous pathology of the lower limbs. Ultrasound diagnosis has replaced the methods mentioned above, although they provide additional information.

The information provided by ultrasonic techniques is both morphological and hemodynamic. These techniques are:

- non-invasive;
- of fast execution;
- reproducible.

All these elements make the Colour-coded Duplex Ultrasound or more simply Duplex Ultrasound (DU) an essential instrument in phlebology, especially since phlebography is invasive and plethysmography is complex to perform.

Duplex Ultrasound allows the evaluation of the superficial and deep venous systems depending of the inferior vena cava, characterized by slow velocities, low resistances, high volume flows and the presence of valves.

DU is used to measure spontaneous and induced flows [1-3] and to provide important information about the permeability, the vein size and the wall morphology.

It represents an improvement over the continuous Doppler, which did not allow a precise identification of the refluxes, their anatomical location or their quantification [4].

However, the DU has limitations, either related to the method or to the practical conduct of the examination. The DU provides us with morphological and hemodynamic information.

We will highlight these main limitations in the assessment of the disease of lower limb vein compared to other investigations. (Fig. 1)

### Informations morphologiques

DU gives us informations on

- permeability;
- the morphology of the venous wall;
- and on the morphology of the valve system.

Permeability is an essential element in acute and chronic pathology that can be assessed directly or indirectly.

The DU allows direct exploration of the venous wall and can identify:

- a parietal thickening;
- endoluminal fibrosis;
- a double channel; [5]
- and the presence of aneurysmal dilation.

The possibilities of evaluation vary according to the equipment used and the technical level of the explorer,

| VENOUS OBSTRUCTION |                 |                  |                  |                    |                  |                |
|--------------------|-----------------|------------------|------------------|--------------------|------------------|----------------|
|                    | SUPRA INGUINAL  |                  |                  | INFRA INGUINAL     |                  |                |
|                    | Identification  | Localisation     | Entity           | Identification     | Localisation     | Entity         |
| Duplex Ultrasound  | AP +++<br>CP +- | AP +-<br>CP +-   | AP +-<br>CP +-   | AP +++<br>CP +++   | AP +++<br>CP +++ | AP +-<br>CP +- |
| Air Rethysmography | AP +++<br>CP +- | AP +-<br>CP -    | AP +++<br>CP +-  | AP +-<br>CP +-     | AP -<br>CP -     | AP +-<br>CP +- |
| Venography         | AP +++<br>CP +- | AP +++<br>CP +++ | AP +-<br>CP +-   | AP +-<br>CP +-     | AP +-<br>CP +-   | AP +-<br>CP +- |
| IVUS               | AP /<br>CP +++  | AP /<br>CP +++   | AP /<br>CP +++   | /                  | /                | /              |
| REFLUX             |                 |                  | VALVE MORPHOLOGY |                    |                  |                |
|                    | Presence        | Extension        | Entity           |                    |                  |                |
| Duplex Ultrasound  | +++             | +++              | +-               | Duplex Ultrasound  | +-               |                |
| Air Rethysmography | +++             | -                | +++              | Air Rethysmography | /                |                |
| Venography         | +++             | +-               | +-               | Venography         | +-               |                |
| IVUS               | /               | /                | /                | IVUS               | /                |                |

Abbreviations : AP= acute phase ; CP= chronic phase.

Fig. 1: Comparison between Duplex Ultrasound and other investigations.

but the information on the flows provided is greater than that given by explorations using a contrast agent.

The main obstacle is provided by the exploration of abdominal veins which are not always accessible for direct exploration.

Unfortunately, the morphology of the valve system is only possible with a high-definition device [6], the standard equipment does not provide the various information necessary to place an indication for valve reconstructive venous surgery.

### Hemodynamic information

As far as hemodynamics is concerned, the DU provides us with exclusive information that cannot be substituted by other investigations because it allows us to clearly identify speed changes without modifying the system and without introducing artifacts.

#### The DU gives us information on:

- the direction of the flow;
- the modifications according to the subject's position;
- and as a result of the flow variations after compression manoeuvres.

- the DU gives us precise information on the flow of veins accessible for direct exploration, which is superior to that provided by other methods including phlebography.

DU is essential in the diagnosis of venous thrombosis. [7, 8]

It allows to accurately evaluate the progressive recanalization of thrombosed veins.

Investigation of the common femoral vein can provide indirect information on ilio-caval obstruction.

Deep vein obstruction is easily identified in acute phase thrombosis, but DU exploration is less effective in chronic obstructions.

In these cases: in the presence of a collateral network, the alteration of femoral velocity sometimes makes it difficult to identify the presence of a downstream obstruction, even when using a hyperhaemia test.

The information provided by:

- phlebography
- IVUS
- magnetic resonance;
- scanner

allow a better determination of the degree of obstruction and its extension [9].

## In which cases ultrasonic methods are they insufficient in the evaluation of venous disease of the lower limbs?

### Identification of reflux is essential in varicose veins and in evaluation chronic venous insufficiency (CVI)

DU allows incompetent veins to be identified qualitatively [10].

Various parameters have been studied to try to correlate the characteristics of reflux, the alteration of the duration of the peak velocity with the clinical severity class, but the result is far from satisfactory.

Severe VCI is better correlated with increased peak velocity [11] than with duration of reflux for both the superficial and deep venous systems [12].  
The lack of correlation between clinical severity and the information provided by DU methods [13, 14] is undoubtedly one of the limitations of this review in establishing an accurate balance sheet.

The hemodynamic explanation of the difficulty of quantifying refluxes by ultrasonic methods is due to the fact that during the manoeuvres used, the main parameters (vein diameter, intravenous pressure, downstream volume, etc.) are constantly changing.

### Evaluation of the veino-muscular pump

DU is not an investigation usually used to evaluate the effectiveness of the venom muscle pump.

To properly evaluate the effectiveness of the muscle pump, respecting the daily reality, it is essential to make the patient walk on a rigid floor, preferably with his own shoes.

This avoids the more constraining treadmill test.

To this end, a wireless air plethysmography is used, which allows patients to walk around without any problems.

### Role of Doppler echo in therapeutic indications according to clinical class (Fig. 2)

#### CEAP class C0s

DU with routinely used probes frequency explores only deep veins, saphenous veins and their accessories, but not tributaries beyond those of the second order that may be responsible for the patient's symptomatology. To explore these tributaries a high frequency probe (18 Mhtz) is mandatory.

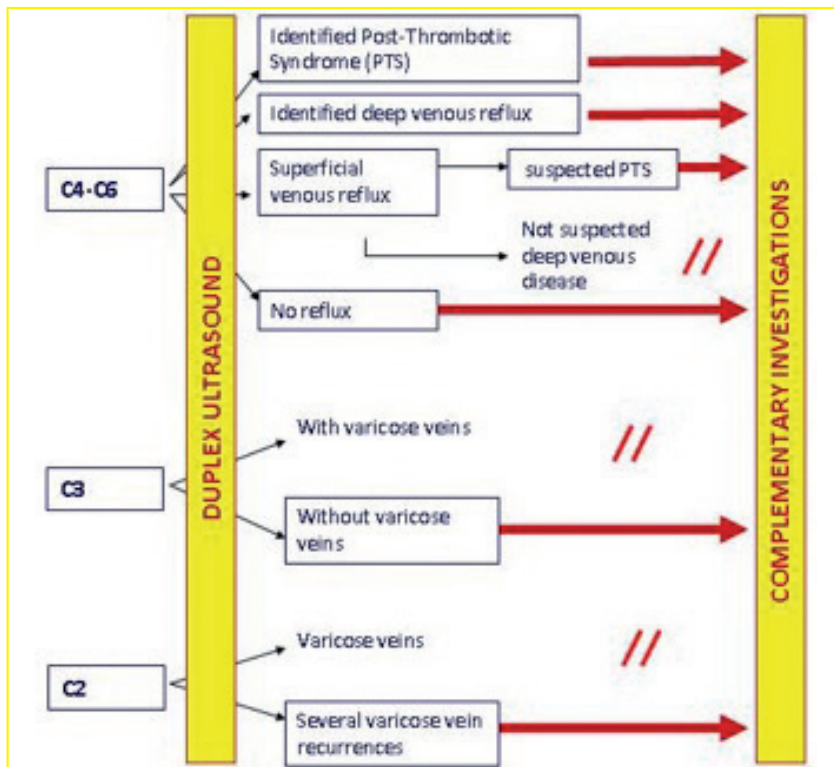


Fig. 2: Role of ED in therapeutic indications according to clinical class.

However, in negative ED can be correlated with incompetence of the tributaries who are at the root of the patient's symptomatology.

#### **CEAP class C 1**

DU is the only investigation that can identify the presence of possible refluxes feeding reticular veins and telangiectasias that may be responsible for a failure of sclerotherapy treatment if they are not treated.

#### **CEAP class C2**

DU is a necessary and sufficient investigation in non-PREVAIT varicose veins [15], as it allows to eliminate or authenticate a deep venous system (DVS) anomaly.

However, in the presence of recurrence of varicose veins and more particularly if it is iterative, DU is insufficient and further investigations should be carried out to identify possible non-thrombotic deep vein obstruction [16]) or the presence of pelvic venous reflux, or transient deep venous reflux.

#### **CEAP class C3**

In the presence of major varicose veins associated with edema, DU may be considered sufficient, but in cases where small varicose veins are associated with edema, in the absence of altered gait and other general factors, further investigation is required to detect obstruction of the deep venous system.

#### **CEAP classes C4-6**

The IVC may be related to superficial venous insufficiency associated or not with deep venous insufficiency and/or perforating venous insufficiency.

When a deep reflux is present, even if it is not axial or in the suspect of an ilio-cave obstructive lesion, further investigations are necessary [17].

The same is true when anamnestic information suggests a post-thrombotic etiology, although the DU does not allow us to identify it.

#### **ED in pelvic congestion syndrome**

Trans-vaginal DU is used to identify pelvic varices and determine whether they result from compression or reflux, but it is not used to determine the compressed veins or the site of the reflux.

Trans parietal DU makes it possible to visualize compression of the left renal vein or compression of the iliac veins, and in a number of cases to identify reflux of the ovarian veins, but not that of the tributaries of the

internal iliac vein in addition it does not allow to determine the etiology, primary or secondary. Selective phlebography is the essential investigation that allows diagnosis and therapy to follow one another.

#### **DU in angiodysplasia and arteriovenous malformations**

ED makes it possible to identify arteriovenous fistulas and the existence of associated deep venous reflux, but in cases where therapeutic treatment is required, further investigation (arteriography, phlebography, magnetic resonance, CT) is necessary.

#### **The treatment of deep venous insufficiency is based on a protocol (Fig. 3) where the DU is always complemented by additional investigations**

The protocol is used to select patients for treatment, guide the choice of technique and post-operative follow-up.

#### **Doppler ultrasound and evaluation of varicose vein treatment results**

The outcome of varicose vein treatment with the DU examination cannot be satisfactorily assessed.

Reading the randomized controlled studies found that the clinical course after treatment of varicose veins in the lower limbs was not perfectly correlated with the abolition of reflux [18-21].

While the most common endpoint remains the elimination of DU reflux, many studies have considered the assessment of symptoms identified by the practitioner (Physician Reported Outcomes) or reported by the patient (Patient Reported Outcomes Measures = PROMs).

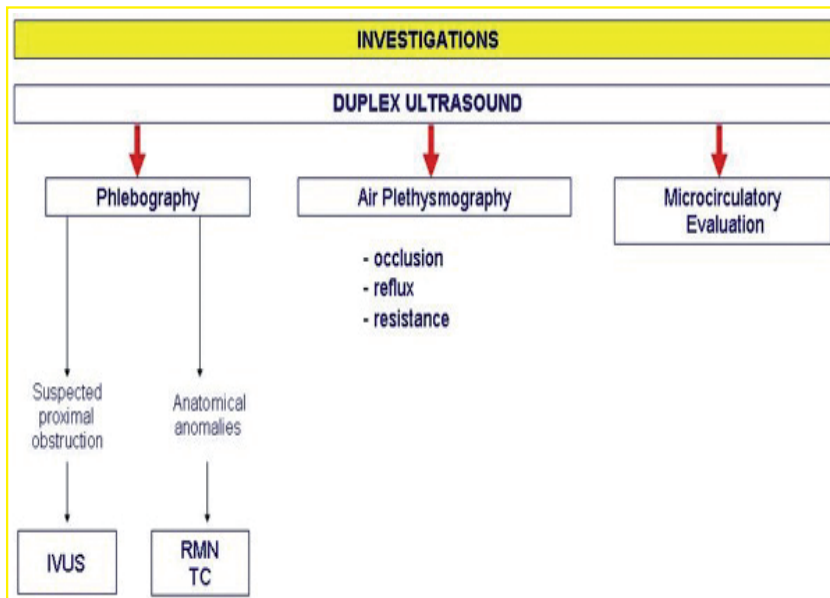
Moreover, to date, there is no better complementary instrumental examination than the ED in this indication.

In the short term, where the problem of recurrences (PREVAIT) does not yet arise, clinical results follow quite well the achievement of the primary objective (occlusion, exeresis, reflux suppression).

However, whether in the medium, long or very long term, when recurrences of all types are observed, it is surprising to note how clinical improvement is not strictly associated with a hemodynamically satisfactory result, particularly with D.

This poor correlation explains why many authors evaluate the results using Quality of Life (QoL) scales.

## In which cases ultrasonic methods are they insufficient in the evaluation of venous disease of the lower limbs?



**Fig. 3:** Preliminary investigation protocol to surgical treatment in the deep venous system.

### Conclusions

DU is the most commonly used method for morphological and hemodynamic testing in venous disease of the lower limbs.

It is sufficient for a simple varicose vein disease assessment, but in most cases it requires additional investigations to determine therapeutic indications for DVI, especially if a deep venous pathology is associated.

### References

- [1] Labropoulos N., Leon LR Jr. Duplex evaluation of venous insufficiency. *Semin Vasc Surg* 2005; 18: 5.
- [2] Labropoulos N., Tiongson J., Pryor L., et al. Definition of venous reflux in lower-extremity veins. *J Vasc Surg* 2003; 38: 793.
- [3] Lensing AW., Prandoni P., Brandjes D., et al. Detection of deep-vein thrombosis by real-time B-mode ultrasonography. *N Engl J Med* 1989; 320: 342.
- [4] Tong Y., Royle J. An anatomic source of false venous reflux with continuous wave Doppler. *J Dermatol Surg Oncol* 1994; 20(10): 676-8.
- [5] Maleti O., Lugli M., Perrin M. Syndrome post-thrombotique. *EMC - Cardiologie* 2013; 8(2): 1-12 [Article 11-740-A-10].
- [6] Lurie F., Kistner RL., Eklof B., Kessler D. Mechanism of venous valve closure and role of the valve in circulation. A new concept. *J Vasc Surg* 2003; 38: 955-61.
- [7] De Oliveira A., França GJ., Vidal EA., et al. Duplex scan in patients with clinical suspicion of deep venous thrombosis. *Cardiovasc Ultrasound* 2008; 6: 53.
- [8] Kayilioğlu SI., Köksoy C., Alaçayır I. Diagnostic value of the femoral vein flow pattern for the detection of an ilio caval venous obstruction. *J Vasc Surg: Venous and Lym Dis* 2016; 4: 2-8.

- [9] Killewich LA., Bedford GR., Beach KW., Strandness DE Jr. Diagnosis of deep venous thrombosis. A prospective study comparing duplex scanning to contrast venography. *Circulation* 1989;79: 810.
- [10] Lurie F., Comerota A., Eklof B et al. Multicenter assessment of venous reflux by duplex ultrasound. *J Vasc Surg* 2012; 55: 437.
- [11] Yamaki T., Nozaki M., Sasaki K. Quantitative assessment of superficial venous insufficiency using duplex ultrasound and air plethysmography. *Dermatol Surg* 2000; 26(7): 644-8.
- [12] Yamaki T., Nozaki M., Sakurai H., Takeuchi M., Kono T., Soejima K. Quantification of venous reflux parameters using duplex scanning and air plethysmography. *Phlebology* 2007; 22(1): 20-8.
- [13] Bradbury A., Evans CJ., Allan P., Lee AJ., Ruckley CV., Fowkes FG. The relationship between lower limb symptoms and superficial and deep venous reflux on duplex ultrasonography: the Edinburgh Vein Study. *J Vasc Surg* 2000; 32(5): 921-31.
- [14] Danielsson G., Norgren L., Jungbeck C., Peterson K. Global venous function correlates better than duplex derived reflux to clinical class in the evaluation of chronic venous disease. *Int Angiol* 2003; 22(2): 177-81.
- [15] Perrin M. Presence of varices after operative treatment : a review. *Phlebology* 2014; 21(3): 158-68.
- [16] Raju S., Neglen P. High prevalence of nonthrombotic iliac vein lesions in chronic disease: a permissive role in pathogenicity. *J Vasc Surg* 2006:136-44.
- [17] Neglen P., Hollis KC., Olivier J., Raju S. Stenting of the venous outflow in chronic venous disease : long-term stent-related outcome, clinical and hemodynamic results. *J Vasc Surg* 2007; 46: 979-90.
- [18] Rass K., Frings N., Glowack P., Hamsch C., Gräber S., Vogt T., Tilgen W. Comparable Effectiveness of Endovenous Laser Ablation and High Ligation With Stripping of the Great Saphenous Vein. *Arch Dermatol.* 2012; 148: 49-58.
- [19] Flessenkämpfer I., Hartmann M., Stenger D., Roll S. Endovenous laser ablation with and without high ligation compared with high ligation and stripping in the treatment of great saphenous varicose veins: initial results of a multicentre randomized controlled trial. *Phlebology.* 2013; 28: 16-23.
- [20] Roopram AD., Lind MY., Van Brussel JP., Terloux-Punt LC., Birnie E., De Smet AEA., et al. Endovenous laser ablation versus conventional surgery in the treatment of small saphenous vein incompetence. *J Vasc Surg : Venous and Lym Dis.* 2013; 1: 357-363.
- [21] Nandhra S., El-Sheika J., Carradice D., Wallace T., Souroullas P., Samuel N., et al. A Randomized Clinical Trial of Endovenous Laser Ablation Versus Conventional Surgery for Small Saphenous Varicose Veins. *J Vasc Surg.* 2015; 61: 741-746.