

Chapter 6

The Duplex ultrasonography investigation of varicose veins, the therapeutic strategy

Jean-Luc Gérard

Abstract

Exploring varicose veins is an important part of the work of the vascular medicine specialist. However, for a long time, he remained confined to the role of sonographer. The "gold standard" for the treatment of advanced varicose veins, has most often relied solely on surgical removal.

Today the chemical and thermal ablation of varicose veins has enabled the doctor to propose and implement other alternatives to surgical management. The better knowledge of phlebology and the standardization of these new techniques have gradually spread to all doctors involved in venous disease in different countries. Rigorous performance of the Doppler ultrasonography examination is essential and knowledge of the entire therapeutic range is mandatory.

Introduction

The Duplex ultrasonography or known more commonly duplex ultrasound (DUS) examination has become indispensable to assess the veins for the management of chronic venous disease (CVD) of the lower limbs.

It combines a morphological study (echography) of the veins with a hemodynamic study (pulsed Doppler).

It allows a detailed examination of the veins:

- their route,
- their ending,
- the direction of the flow,
- tributary and accessory veins,
- the perforators.

The DUS, although it has allowed to relearn the anatomy of the veins, is however very operator and technical dependent.

Although the anatomy of the superficial veins of the lower limb is relatively simple, some portions are constant, but others can be highly variable.

This is why this examination must be complete, looking for all leak points and all path variations. The most common variations must be known.

The reflux is not static but dynamic! We need to test the flow direction of all the veins, the presence or absence of venous back flow. This is known as competent (physiological flow) or incompetent (venous reflux) vein.

A rigorous initial Doppler assessment is important, as the final findings have a significant impact on treatment options. Failure to identify and treat all sources of reflux can result in unsatisfactory hemodynamic and esthetic results as well as rapid varicose recurrence.

In order to speak the same language, the new anatomical terminology of superficial veins should be used by all (Table 1).

Echo-doppler assessment

Examination of superficial veins should not be carried out without first checking the deep veins.

It is performed in supine position for femoral and iliac veins up to and including the vena cava, and then sitting at the edge of the examination bed for the sural and popliteal veins. During this complete examination of the deep veins, early signs of atherosclerosis will also be checked in the arteries.

The vascular physician is not a technician and during the examination he will ask about medical history, possible personal arterial risk factors (tobacco, cholesterol, diabetes, hypertension) and venous events but also family history risk factors with a notion of arterial disease (myocardial infarction, arteritis of the lower limbs, stroke, diabetes) and, venous disease (varices, venous thrombosis, pulmonary embolism, inherited thrombophilia).

Table 1: Old terms and new terms in the *Terminologia Anatomica*.

| Old terms | New terms | Abbreviations |
|--|--|---------------|
| Internal or long saphenous vein, v. saphena magna | Great Saphenous Vein | GSV |
| External or short saphenous Vein, v. saphena parva | Small Saphenous Vein | SSV |
| Anterior saphenous vein | Anterior Accessory Saphenous Vein of the thigh | AASV |
| Posterior saphenous vein | Posterior Accessory Saphenous Vein of the thigh | PASV |
| Giacomini vein | Giacomini anastomosis or large inter-saphenous anastomosis or cranial extension of SSV | G |
| Leonardo's Vein | Posterior tributary of the leg | PTL |
| Pudic vein | Pudendal vein | |
| Internal gastrocnemius vein, | Medial gastrocnemius vein | MGV |
| The crosse of the internal saphenous vein | Sapheno-femoral junction | SFJ |
| The crosse of the external saphenous vein | Sapheno-popliteal junction | SPJ |
| Ostial valve (from SFJ or SPJ) | Terminal valve | TV |
| Pre-ostial valve (from SFJ or SPJ) | Pre-terminal valve | PTV |
| Crural | Femoral | |
| External | Lateral | |
| Internal | Medial | |
| Superior | Cranial | |
| Inferior | Caudal | |
| Branch, collateral | Tributary vein | |
| Varicosities | Telangiectasias | |

Heredity is an important vascular risk factor, especially when there is early arterial disease in the family. Patients should be well informed about the rationale for treating varicose veins, particularly with regard to the chronological delay between the appearance of varicose veins and arterial disease [1].

| Venous Doppler Echo

Ultrasound machines are nowadays all efficient with the indispensable condition of a good adjustment of the different parameters of ultrasound and Doppler according to each type of examination (artery, deep or superficial vein...).

The choice of probes is important and those used for superficial veins are at least 10 MHz but preferably 14 MHz or better 18 MHz.

The Duplex ultrasound thus makes it possible to analyze varicose veins, to study the vein walls, their diameter, their path and the direction of the blood flow through them. This examination also makes it possible to detect a possible anomaly in the shape of these veins: plicature, duplication, aneurysm.

By assembling all the morphological and functional information provided by this examination, an exhaustive report with true diagrammatic representation of the venous networks can be established, on a premade datasheet or on computer, representing the superficial venous network, both anterior and posterior.

Some have proposed 3-sided schematics, others a detailed diagram of the leg completely flat. Some have a large number of graphic codes that can complicate reading. This mapping must be accurate, unambiguous and readable by all, in order to leave the choice for all therapeutic options.

It must make it possible to understand the almost exact path of the varicose veins (saphenous veins and tributaries) with the origin of the reflux(s), their diameter, the direction of flow indicated by an upward or downward arrow. However, the therapist must be able to do himself the echography-doppler of the superficial veins in order to identify all the particularities of the superficial veins, duplication and possible difficulties (tortuosity, aneurysm, synechiaes...) that he could encounter during a surgical, chemical or thermal ablation procedure. An accurate description of the deep and superficial veins is established,

The Duplex ultrasonography investigation of varicose veins, the therapeutic strategy

including the reason for the examination, personal or family history of venous thrombosis. At the level of the lower limb is proximal the veins located above the knee and distal when they are below the knee (normally below the popliteal vein). Since the blood flow is in the vein from distal to the heart, in some countries by convention, for the lower limb, the side of the vein nearer to the foot is called the upstream side and the downstream side nearer to the heart. The CEAP [34] classification is to be specified:

CLINICAL CLASSIFICATION: C

- C0: no visible or palpable signs of venous disease
- C1: telangiectasia - reticular veins
- C2: varicose vein
- C2r: recurrent varicose vein
- C3: edema
- C4a: pigmentation or eczema
- C4b: lipodermatosclerosis or white atrophy
- C4c: corona phlebectatica
- C5: healed ulcer
- C6: active ulcer
- C6r: recurrent active ulcer
- C(S): Symptomatic patient (pain, heaviness, skin irritation, muscle cramps or other symptoms due to venous disease)
- C(A): asymptomatic patient

ETIOLOGICAL CLASSIFICATION: E

- Ec: Congenital there is a reflux from birth (congenital avaluulation). The interrogation will find in the family history (father, mother, grandfather...) the same signs or symptoms (varicose veins or leg ulcer appeared very early)
- Ep: Primary or primitive, the most frequent, the cause of varicose veins has not been determined
- Es: Secondary after venous thrombosis (post-thrombotic)
- EsI Secondary - intravenous
- EsE Secondary - extravenuous
- En: No venous etiology identified. E(n) cannot be used for C2 (varicose veins), but only for C0s (telangiectasias) whose aetiology is not determined.

ANATOMICAL CLASSIFICATION: A

- As: superficial veins
- As1 (Tel-Ret): Telangiectasia-reticular veins
- As2(GSVa): GSV above the knee
- As3(GSVb): GSV below the knee
- As4(SSV-AASV): SSV- anterior accessory saphenous vein
- As5(NSV): non saphenous vein
- Ap: perforating veins
- Ad: deep vein
- An: no venous location identified

CLASSIFICATION PHYSIOPATHOLOGIQUE:

- Pr: reflux
- Po: obstruction
- Pro: reflux and obstruction
- Pn: no identifiable venous pathophysiology

Venous reflux

It can be highlighted by 3 means: compression-release (squeezing test), Valsalva maneuver and Parana maneuver.

Compression- Release

It is a reliable method of assessing reflux. The patient is in a standing position, and reflux can be sought with the color Doppler, which allows testing several veins at the same time, or pulsed Doppler with the vein in cross-section, which is done in common practice.

However, international recommendations advocate that the vein be placed in a longitudinal section, with the Doppler color box steered 60 degrees with an angular correction, the color being optional.

To have a favourable Doppler angle in longitudinal section, consider steering the Doppler box and tilting it in the direction of the lower obliquity of the vessel. Remember to angle the probe manually in cross-section.

With compression of the muscles, carried out at a distance from the area examined, there is an increase in flow in the vein as the blood is pushed in the physiological direction of the flow, from the bottom to the top.

As soon as the pressure is released, if the valves are competent, there is no or minimal backflow (**Fig. 1a, 1b**).

With incompetent valves, the blood flows back from the top to the bottom in a more or less prolonged manner.

The Valsalva maneuver (thoracic hyperpressure with closed epiglottis):

It is a suitable method for testing the valves of the sapheno-femoral junction. Sometimes it is more difficult to perform for some patients, who need to be given very explicit indications ("inflate your lungs, block your breathing and push as if you were going to have a bowel movement") or blow through a small tube (cathlon).

In the case of valvular incontinence, there is a frank and prolonged reversal of venous flow during the entire phase of thoracic hyperpressure.

In 1997, the **Paraná maneuver** was described by Claude Franceschi [35], taking its name from the city of Paraná (Argentina), where it was conceived.

This maneuver consists of gently pulling or pushing the patient backwards or forwards, holding by the waist with one hand, the patient upright, and holding with the other hand, the probe in contact with the skin in front of the vein to be examined.

This maneuver triggers a proprioceptive reflex, allowing isometric contraction of the leg muscles to maintain balance, followed by muscle relaxation. This maneuver assesses the deep and superficial physiologic venous flows particularly caused by the calf muscular pump.

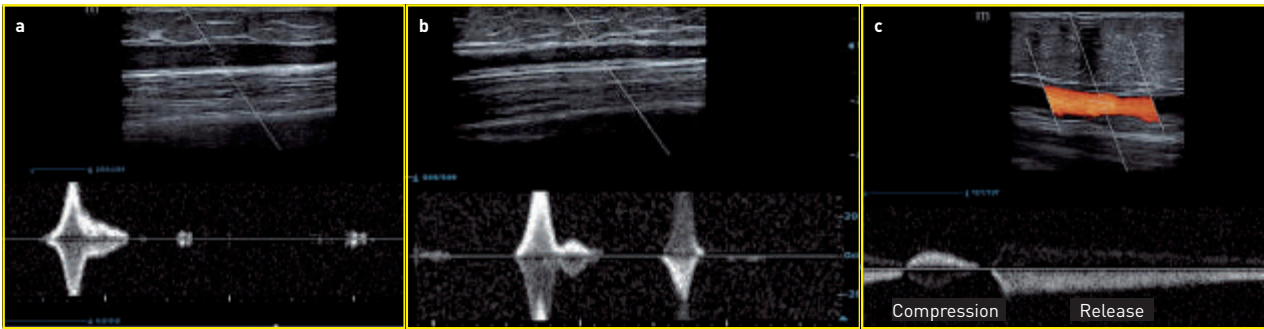


Fig. 1. a: After compression, no reflux. **b:** After compression, minimal reflux, the valve closing time. **c:** After compression, reflux of more than 0.5 seconds.

This maneuver by using duplex ultrasonography is very useful for studying deep venous flow and detecting valvular incompetence, mainly popliteal and perforating

veins, the limitation of the squeezing test being given by a large calf circumference, which cannot be easily compressed by a small hand.

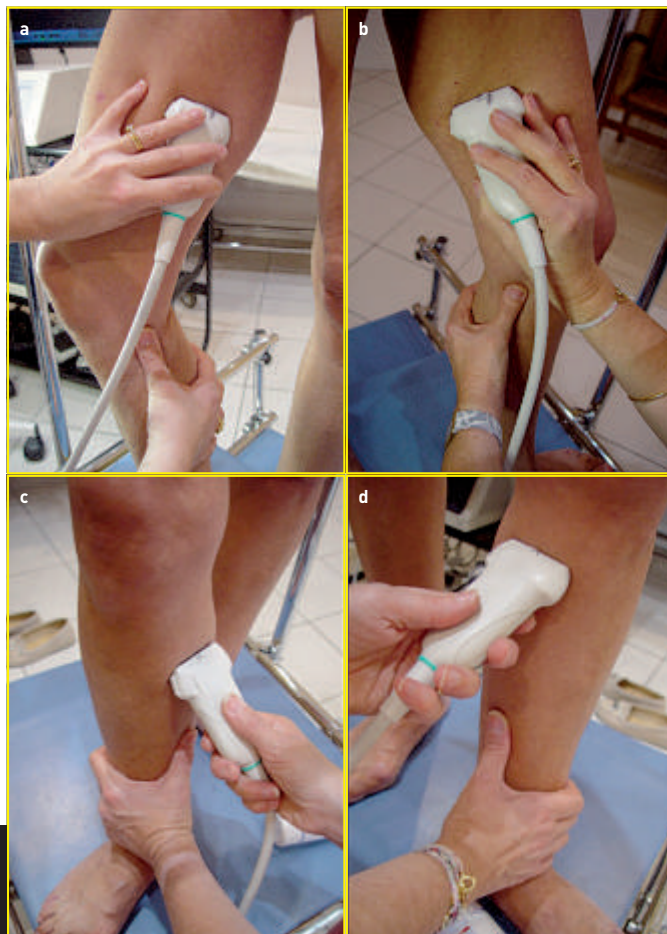

Fig. 2a, b, c, d: The thumb that will compress is in a vertical position and in the path of the vein to be tested. The probe is tilted.

The Duplex ultrasonography investigation of varicose veins, the therapeutic strategy

Venous reflux is the flow opposite to the physiological centripetal flow of blood in the veins, and can be divided into physiological and pathological reflux.

Physiological reflux, when the retrograde backflow lasts the fraction of a second it takes the cusps of the valves to join.

Labropoulos [2] showed that the time of pathological reflux is variable according to the veins: the reflux must be greater than 1 second for the common femoral, femoral and popliteal veins; for superficial veins, deep femoral vein, sural and muscular veins of the calf, it is 0.5 second (**Fig. 1c**) and for perforating veins it is 0.35 second.

You have to be persistent and curious to find the source(s) or cause of the reflux.

Reflux may be partial at the level of the trunk of the great saphenous vein (GSV).

There is no a priori incompetence of the GSV trunk without reason. The starting point may be a perforator, even a modest one, a perineal vein, an anterior accessory saphenous vein of the thigh (AASV) or a posterior accessory saphenous vein of the thigh (PASV). The examination is very operator and technical dependent. The venous reflux is not static but dynamic!

Examination of superficial veins

It is always performed with the patient standing, for convenience rather on a phlebology stepladder, from the front, for the veins of the anterior face of the limb, the knee slightly bent, the foot turned outwards; from the back, both knees slightly bent, the feet in neutral position without rotation, for the veins of the posterior face.

The ultrasound probe is held with one hand usually with the first 3 fingers, thumb below and index and ring fingers above for thigh veins (inverted for leg veins), or thumb on the inner edge of the probe and the 2nd and 3rd finger on the outer edge when the probe is in the right hand, the other fingers resting on the skin.

In order to optimize and obtain the maximum Doppler signal, the probe must be angled manually as much as possible (with an angle between 30 and 60°) while maintaining contact with the skin. The pressure-release is done with the thumb ± the thenar eminence of the second hand, the last 4 fingers just serving as support to form a clamp.

The thumb must always be positioned on the path of the vein to be examined at least 10 cm (maximum 20 cm) below the probe, and must be in a vertical position (**Fig. 2 a, b, c, d**). It is illusory to want to test the competence of a vein if the compression is done outside the path of the vein to be tested, the Doppler signal will be of poor quality.

Similarly, if compression is performed with the last 4 fingers or with just the thenar and hypothenar eminence, the pressure will be insufficient to mobilize the blood column. The quality of the Doppler signal depends on its 3 parameters: thumb on the path of the vein and in vertical position, inclined cranially the probe (in cross-section).

The respect of these parameters is all the more true when the patient is obese or muscular, and when the size of the examiner's hand is small and therefore its strength limited. The thumb pressure is applied firmly, quickly and without abruptness. The release is slower, without precipitation.

For right-handed people when examining GSV on the right thigh, the hand holding the probe is ideally the left hand so that the right thumb that will exert the most force is in the vertical position.

Depending on the vein to be examined in the thigh or leg, on the right or left side, the hand probe should be changed so that the contralateral thumb is in the most vertical position to exert maximum pressure.

Siphon effect test

In a patient examined standing, after the compression-decompression maneuver to test for reflux in the GSV, at the time of release, a finger compression of the tributary vein is performed, in which the incompetent saphenous trunk is emptied.

The test is considered positive if this manual compression of the tributary vein abolishes reflux in the GSV.

The same, during the Valsalva, the finger compression of the tributary cancels the truncal reflux of the GSV.

This "reflux elimination test" [3] (**Fig. 3**) was mentioned very early on (1993) by French phlebologists and was used as the basis for the CHIVA treatment (CHIVA III, in the **C**onservative **H**emodynamic treatment of **V**enous **I**nsufficiency in **A**mbulatory), then called "reversibility

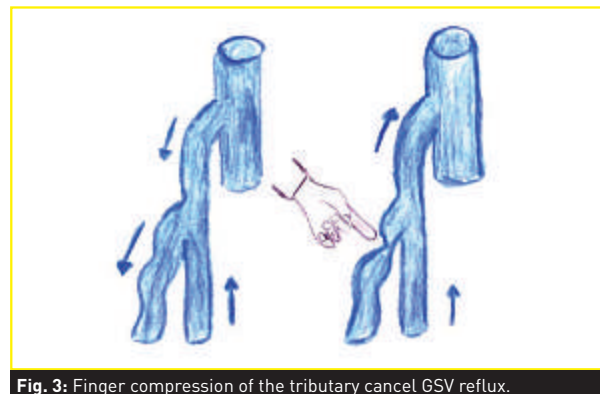


Fig. 3: Finger compression of the tributary cancel GSV reflux.

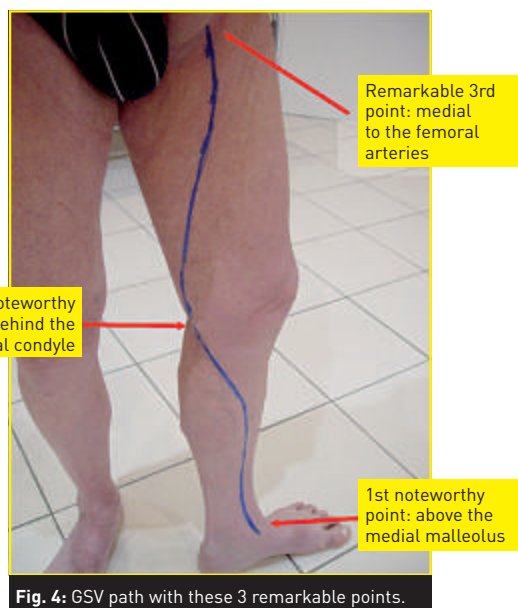


Fig. 4: GSV path with these 3 remarkable points.

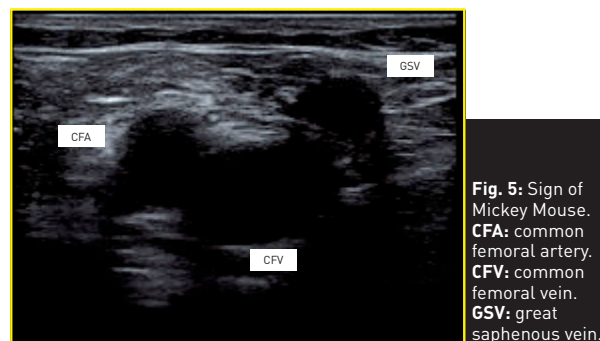


Fig. 5: Sign of Mickey Mouse. CFA: common femoral artery. CFV: common femoral vein. GSV: great saphenous vein.

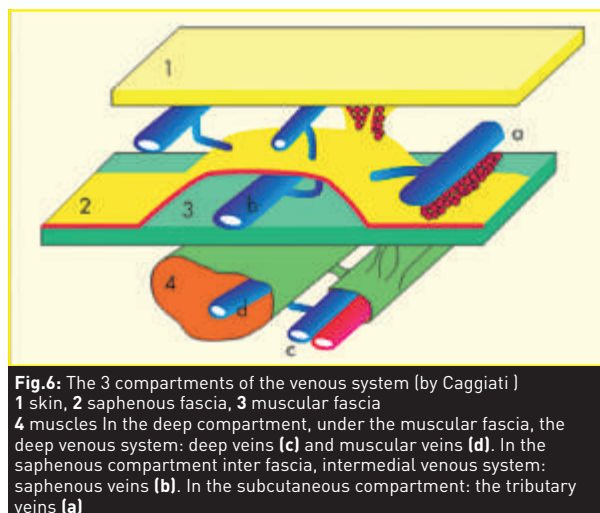


Fig.6: The 3 compartments of the venous system (by Caggiati)
1 skin, 2 saphenous fascia, 3 muscular fascia
4 muscles In the deep compartment, under the muscular fascia, the deep venous system: deep veins (c) and muscular veins (d). In the saphenous compartment inter fascia, intermedial venous system: saphenous veins (b). In the subcutaneous compartment: the tributary veins (a)

test” for the ASVAL method (Selective Varicose Vein Removal under Local Anaesthesia) [4].

Ablation or disconnecting venous anastomosis at the end of the tributary by removing the drainage pathways (siphon effect) would allow to spare healthy segments and particularly the trunk of the GSV to be preserved. Removal of these incompetent tributaries alone may be sufficient to preserve the venous capital while relieving the symptoms of venous insufficiency.

The great saphenous vein (GSV) (As2 and/or 3 in CEAP)

Route

The great saphenous vein (Fig. 4) is the continuation of the medial marginal vein of the foot. It passes anterior to the medial malleolus: this is a perfectly constant landmark.

In its leg portion, the vein rises vertically along the posterior edge of the tibia, in the angle between this edge and the calf muscles.

It arcuately embraces the medial tuberosity of the tibia and the medial condyle of the femur, between it and the anterior edge of the sartorius.

It then passes behind the medial condyle of the femur. Second landmark, it is easily palpated at this level under the relief of the medial condyle which it bypasses.

In its femoral portion, it becomes anterior and rises parallel to the deep vessels, and joins the groin region by into the common femoral vein on its anteromedial side.

It ends 4 cm outside the pubic tubercle, 4 cm below the femoral arch (which is not palpable) describing a junction through which it perforates the fascia cribriformis. Third landmark, it is located 1 cm medial to femoral arterial pulsation.

In cross-section, some have described the Mickey Mouse sign (Fig. 5) with the common femoral artery, the common femoral vein and the GSV.

Therapeutic consequence: knowledge of the path of the GSV is indispensable during the ultrasound examination.

It avoids looking for this vein anywhere other than its most common route. For the surgeon, all variations of the GSV route other than the modal form are essential to inform to avoid false routes of the stripper.

The Duplex ultrasonography investigation of varicose veins, the therapeutic strategy

Venous compartment

Caggiati [5] proposed a consensus nomenclature, characterizing the venous system in 3 compartments separated by the skin, the saphenous fascia, and the muscular fascia.

The saphenous trunks (GSV, small saphenous vein (SSV), anterior accessory saphenous vein (AASV) in the upper 1/3 of the thigh, posterior accessory saphenous vein (PASV) in its lower 2/3) are located between the 2 layers of the fascia in the saphenous compartment (ultrasound sign of the eye described by Bailly in 1995 [6] or Egyptian eye specified by Lemasle in 1996 [7, 8] (**Fig. 7**).

The tributary veins (non-saphenous vein) are found under the skin in the subcutaneous compartment. Therefore, by definition the GSV is always located in its saphenous compartment and veins outside this compartment cannot be called GSV. Except in very thin and/or very athletic subjects, GSV is not visible on clinical examination (**Fig. 8**).

There are, however, segmental hypoplasia or agenesis of GSV. If a trunk (real or sometimes millimetric) is visualized in the saphenous compartment (**Fig. 9**), it corresponds to the true GSV, and the subcutaneous vein is not the GSV (whatever its size), but a AASV in a very anterior position, or an anterior suprafascial tributary.

By excess of language when there is no visible saphenous vein in the saphenous compartment (agenesis of the GSV), we can speak of a GSV suprafascial (**Fig. 10**).

The GSV may be duplicated (in whole or in part) in its saphenous compartment, with two saphenous veins, one of which may be competent and the other not (**Fig. 11**), or both incompetent.

Anatomical variations are very numerous, and the ultrasound study, carried out in cross-section, allows the path and situation of superficial veins to be better followed.

The GSV is first followed in its compartment from the malleolus to the groin, then the other veins.

These accessory saphenous veins (inter-fascial) are described anteriorly or posteriorly depending on their location in relation to the trunk of the GSV (anteriorly or posteriorly to the GSV).

Similarly, avoiding the term branch for the tributary (supra-fascial), we will speak of an anterior or posterior tributary vein (in relation to the GSV) of the thigh or leg. However, this supra-fascial vein can often reach (or leave) the saphenous compartment at a variable level in the thigh or leg.

The angle that the GSV makes with this supra fascial tributary can be a closed angle ($\pm 30^\circ$), or an open angle ($> 45^\circ$, sometimes bayonet).

All the anatomical variations that can help the therapist are important to describe. The consequences are not the


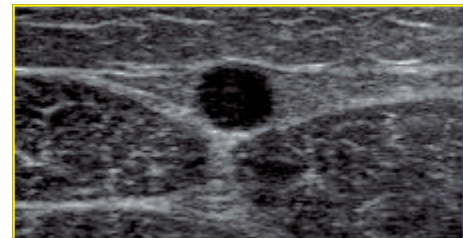


Fig. 7: Egyptian eye sign.

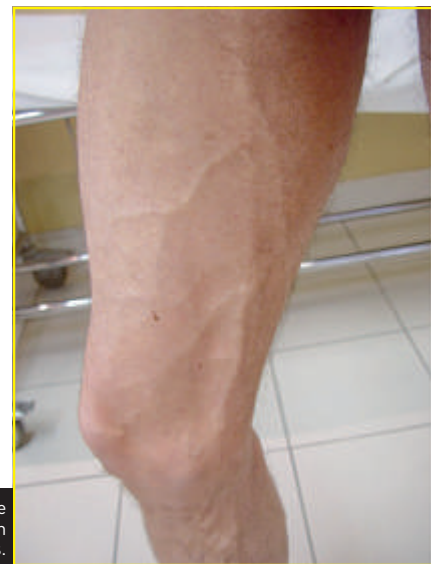

Fig. 8: GSV is visible in sporty and thin patients.

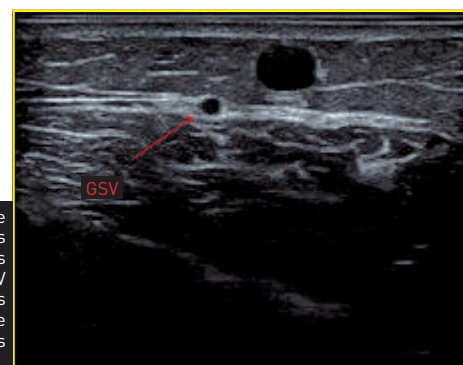


Fig. 9: The subcutaneous vein, dilated, is not the GSV because it is situated outside the saphenous compartment.

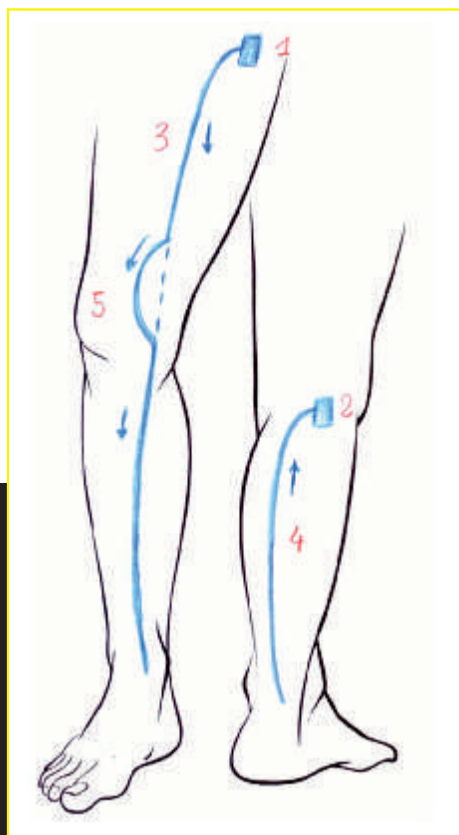

Fig. 10: Partial agenesis of GSV at the femoral level.
 1. SFJ.
 2. SPJ.
 3. incompetent GSV trunk.
 4. trunk of the competent SSV.
 5. anterior tributary vein of thigh, called by simplification of language GSV suprafascial.

same: a stripper or a fiber/catheter will be more difficult to pass if the angle is very open, requiring an additional incision or a double insertion.

The sapheno-femoral junction (SFJ), the "crosse or saphenous arch"

It is of great anatomical fixity: at the level of the femoral triangle (Scarpa triangle), the common femoral vein

located medial to the artery most often receives anteromedial GSV.

This junction, on the other hand, receives tributary suprafascial veins with a descending course: superficial circumflex iliac vein and abdominal subcutaneous vein (superficial epigastric), and with a transverse course; genital veins (lateral and dorsal pudendal or clitoral). These veins have a gravitational flow.

This junction also receives 2 accessory saphenous veins with an ascending course: the anterior accessory saphenous vein of the thigh (AASV) and the posterior accessory saphenous vein of the thigh (PASV). These veins have antigravity flow and are possibly valvular.

These 5 veins theoretically form the normal type of a venous star (Fig. 12).

This arrangement is infrequent (18.4%) [9] and, in fact, the mode of ending of these tributaries and accessory veins is highly variable.

Not all of them are always present and either they join the SFJ in isolation or they group together to form common trunks that join the GSV or the AASV.

Due to the large number of combinations, it is not possible to define termination types.

Mühlberger [9] (Fig. 13) carried out a study on the cadaver dissection of the last 25 cm of the 217-member GSV.

It considers as a major tributary flowing into the last centimeters of the GSV:

- the lateral pudendal vein, present in 90% of cases
- the superficial circumflex iliac vein, found in 83% of cases
- the superficial epigastric vein, present in 78% of cases.
- Anterior and posterior accessory saphenous veins of the GSV were less frequently observed in 51% and 68% of cases, respectively.

The junction has a terminal and pre-terminal valve.

The last valve may be located just at the sapheno-femoral junction, thus in an ostial position.

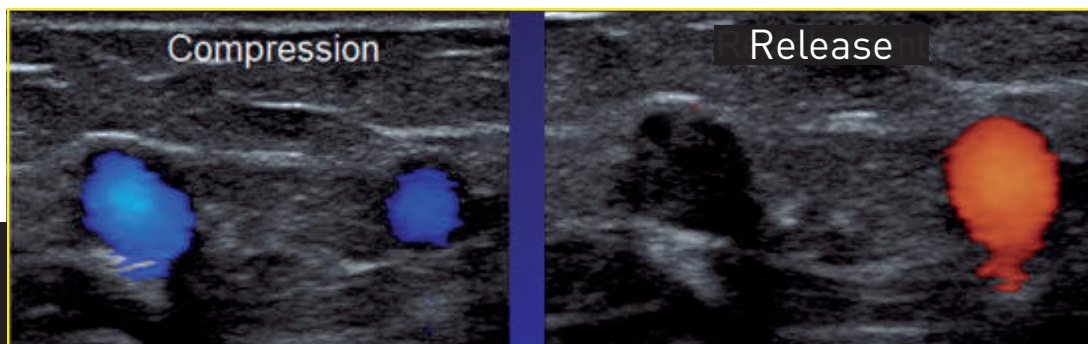


Fig. 11: 2 saphenous veins in the saphenous compartment. One is incompetent.

The Duplex ultrasonography investigation of varicose veins, the therapeutic strategy

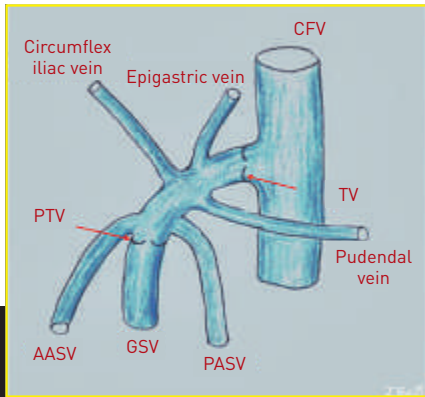


Fig. 12:
 Star-shaped arrangement found

However, if the terminal valve is defined as being located between the GSV termination in the common femoral vein and the tributary vein closest to the ostium, it is found in only 70% of cases.

If we define the pre-terminal valve as the most distal valve of the SFJ, located upstream of the first tributary vein of the GSV termination, it is found in only 85% of cases.

PASV is not always present (less than 70%) and its termination, when it exists, is very often at a distance from the SFJ, just over 7 cm on average from the ostium of the GSV.

This vein should then be considered more as a posterior tributary of the thigh than as an accessory saphenous vein.

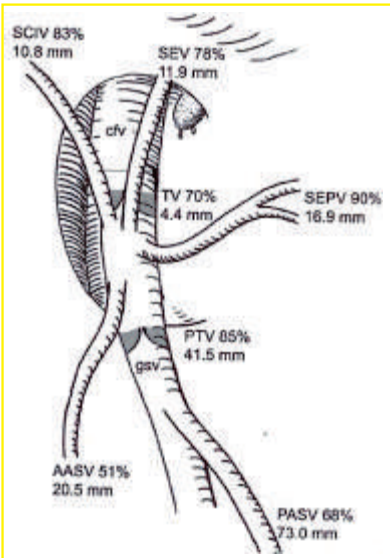


Fig. 13: The different afferent veins of the JSF with their percentage of presence.
SCIV: superficial circumflex iliac vein.
SEV: superficial epigastric vein.
CFV: common femoral vein.
TV: Terminal valve.
SEPV: superficial external pudendal vein.
PTV: pre-terminal valve.
GSV: great saphenous vein.
AASV: anterior saphenous vein accessory of the thigh.
PASV: accessory posterior saphenous vein of the thigh.

High bifurcation of the common femoral artery

The SFJ is normally located above the bifurcation of the common femoral artery, the femoral pulse identifies the arterial axis which is lateral to the venous axis.

In the case of a high arterial bifurcation, the deep femoral artery (DFA) located medially may obscure the SFJ [10] (**Fig. 14**) or be located in a clamp formed externally by the deep femoral artery (DFA) and internally by the (superficial) femoral artery (SFA) (**Fig. 15**).

These are important elements to specify in case of surgery, in order to avoid an arterial wound during dissection, or worse confuse artery and vein.

Terminal and pre-terminal valve competence

Either both valves are incompetent, or only one is incompetent, or both are competent and several types are possible [7, 8]:

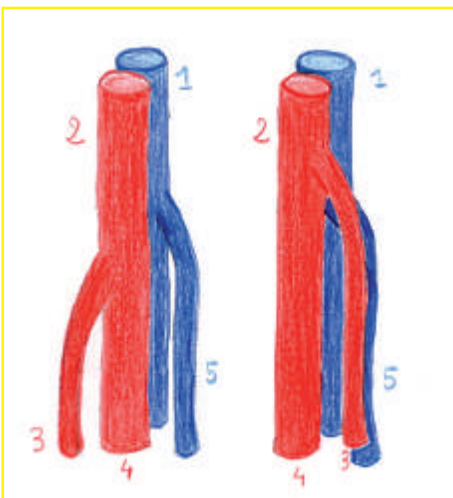


Fig. 14 : Perrin [10]
 Left usual arrangement of the femoral vessels and the sapheno-femoral junction. Right: Upper bifurcation of the common femoral artery. The origin of the deep femoral artery, whose initial abnormal medial course masks the sapheno-femoral junction.
 1. Common femoral vein;
 2. Common femoral artery;
 3. Deep femoral artery;
 4. Superficial femoral artery;


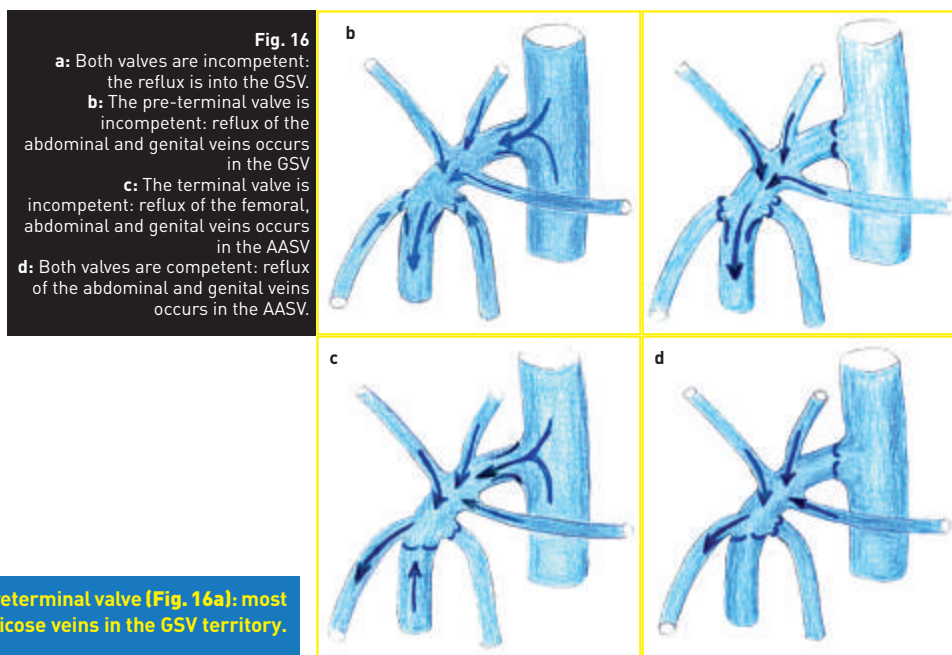


Fig. 15: Drawing (Guillotine): the GSV is located in a clamp of the femoral division.



- Incompetent terminal and preterminal valve (**Fig. 16a**): most frequent mode in case of varicose veins in the GSV territory. There is a reflux in Valsalva.
- Competent and incompetent preterminal valve (**Fig. 16b**): drainage of tributary (abdominal or genital) or accessory veins (AASV or PASV) is done in the GSV.
- Incompetent and competent preterminal valve (**Fig. 16c**): reflux is to the AASV. There is reflux in Valsalva in the AASV but not in the GSV. Terminal incompetence of the GSV does not necessarily spread over the trunk of the GSV, sometimes only PASV or only AASV is involved, sometimes all 3 are incompetent to varying degrees.
- Competent terminal and pre-terminal valve (**Fig. 16d**): drainage of tributary (abdominal or genital) or accessory (PASV) veins is done in the AASV.
- There is no reflux in Valsalva in GSV, but there is another possibility: incompetence in GSV is due to perineal varicose veins or to a paradoxical reflux of the Giacomini vein, which can lead to a variable level of reflux in the thigh. There is a possible reflux in Valsalva through the perineal veins in the AASV or in the GSV.

Therapeutic Consequences:

- The widened "crossectomy" (flush ligation of the SFJ and all its tributary or accessory veins), this sacred dogma of vascular surgeons, is being questioned.
- The sapheno-femoral junction can often be spared, when the terminal valve is competent.
- It would not be heresy to preserve the tributary veins draining the abdomen and pelvis.
- Ligation may be performed either below the incompetence of the GSV or at the level of the AASV or PASV if the latter is incompetent.

In chemical and thermal ablation, the status of these valves is of little importance.

The sclerotherapy will be carried out, under ultrasound guidance, in the incompetent vein at a distance of about 10 cm below its termination.

Occlusion is then regularly observed up to the level of the junction between the incompetent vein and a competent vein.

In thermal ablation, the protocols of the various laser or radiofrequency manufacturers recommend, for the radiofrequency, positioning the tip of the catheter consistently and precisely 2 cm below the ostium at the GSV, and for the laser in this inter-valvular space at the SFJ, below the tributary veins between 0.5 and 2 cm from the ostium.

Consequently, tributary veins located more than 2 cm from the ostium, in particular, PASV or a posterior tributary vein of the thigh, will be ignored during thermal ablation procedure.

They will therefore have to be monitored in the aftermath of the intervention as they could be a source of recurrency. Finally, there is another valve to explore: the femoral valve located in the common femoral above the sapheno-femoral junction.

For Capelli [11, 12], when this femoral valve does not exist or is incompetent and the terminal and preterminal valves are also incompetent, then there is a formal indication for a surgical ligation of the SFJ. However,

The Duplex ultrasonography investigation of varicose veins, the therapeutic strategy

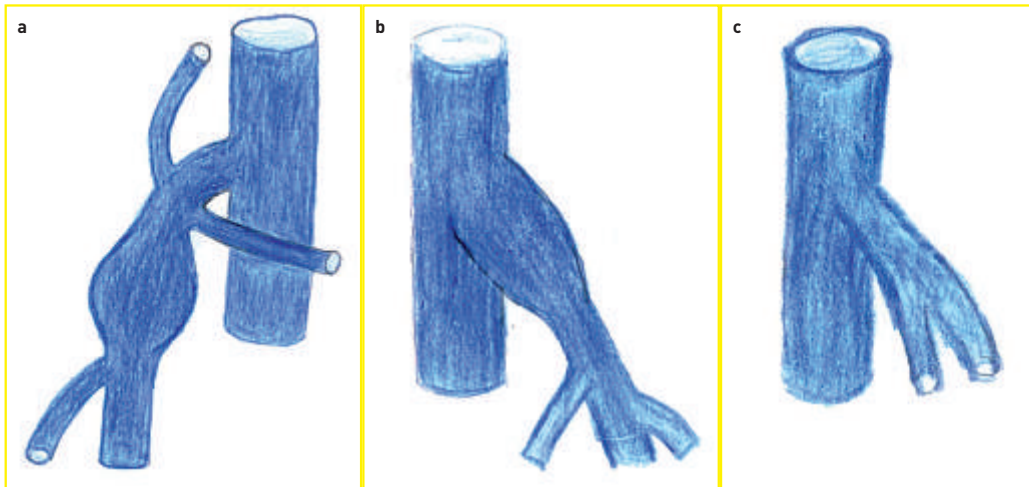


Fig. 17a, b, c: SFJ:
a: dilated,
b: aneurysmal,
c: duplicated (from left to right). Atlas photos of the anatomy of superficial veins of the lower limbs.

during chemical or thermal ablation, no particular recurrence was specially noted regardless of the status of these 3 valves, and therefore, this assertion by Capelli is not confirmed.

On the other hand, the termination of the GSV will have to be carefully analyzed.

It can be:

- very dilated [Fig. 17 a], but with tributary veins in its ostial juxta portion and there is no contraindication to thermal ablation,
- or very aneurysmal [Fig. 17b] without tributary veins or small caliber veins at this level (and this could be the only reserve for thermal ablation because tumescent anesthesia will not allow complete spasming of this junction with the risk of undertreatment or venous thrombosis: heat- induced thrombosis, EHIT, described by Kabnick [13]).

Its junction may be double (Fig. 17c), with a single saphenous vein, or with two saphenous veins, one of which may be competent and the other not.

Relationship to arteries

Superficial and deep lateral pudendal artery

They cross anteriorly the femoral vein below and above the "junction" of the great saphenous vein.

During thermal treatments, the high temperature of the laser fiber or radiofrequency catheter could cause perforations of the vein, and possibly a wound in one of these arteries with a risk of arteriovenous fistula.

This possibility has already been described [15], and tumescent anesthesia around GSV should push away the artery from the vein.

However, care must also be taken not to injure the artery with the needle when administering tumescent anaesthesia.

Relationship with nerves

The saphenous nerve cannot be correctly identified, and the thermal ablation should stop above the line between the upper 1/3 and middle 1/3 of the leg (Fig. 18).

On the other hand, according to the theory of angio-directing nerves highlighted by Prof. Gillot [16]

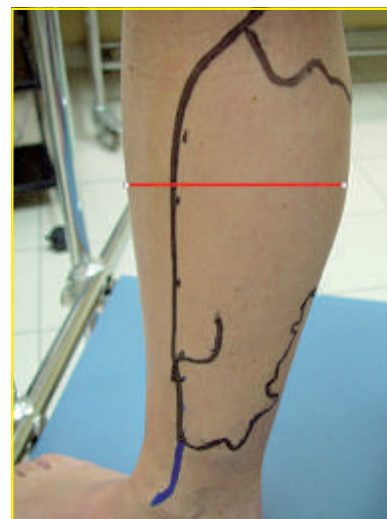


Fig 18: Below this red line thermal treatment may cause saphenous nerve damage.

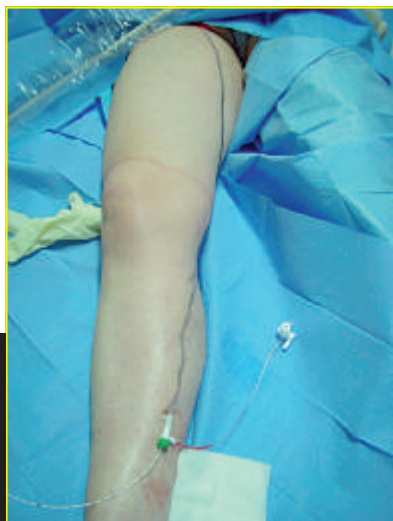

Fig. 19: Catheterization below the middle third of the leg when possible, thermal treatment of a tributary vein (non saphenous) is safe because it is not accompanied by a nerve.

(embryogenesis of veins follows nerve development), nerves are satellites of veins that are in the axis of the body i.e. deep veins, GSV and SSV. Therefore, tributary veins do not have a satellite nerve.

Consequently, a thermal treatment below this line even very distally is possible by catheterization of an anterior or posterior tributary leg vein (**Fig. 19**).

Vein measurement

The venous wall, like that of the arteries, is composed of three tunics concentric from the inside to the outside: intima, media and adventitia.

The measurement of a vein is done in cross-section by measuring the intima-intima distance.

The number given by the ultrasound scanner is most often an integer with a comma. This is an average

diameter, and should therefore be rounded either to the nearest unit or to half (e.g. 5.3 mm is rounded to either 5 mm or 5.5 mm).

The diameter of a saphenous trunk is often measured (mentioning its maximum size) at the sapheno-femoral or popliteal junction.

An average size, apart from a dilatation at the level of the valves, the trunk of the thigh, the leg is also to be indicated to guide the therapy.

Similarly, a significant, isolated ectasia may be reported. However, the wall can be very thick, even calcified, as a result of thrombosis or sclerotherapy or in elderly patients.

The diameter of the vein is important to consider: it can decide the best therapeutic approach to adopt. Up to minus 6mm foam sclerotherapy is reasonable.

The endovenous heat treatment option can be offered for GSV trunk diameters from 5 mm to more, without any real upper limit.

It should be noted that, according to the HAS (French recommendations), surgery is preferable above 12 mm in diameter of the GSV trunk.

However, these HAS recommendations were established in 2008, and experience shows that almost all veins, regardless of size, can be treated by thermal methods. There is no size limitation as long as the vein can be spasmed during the tumescent anaesthesia and sufficient energy is applied.

Indeed, in the case of thermal ablation, the energy must be adapted according to the diameter of the vein, and then the adventitia-adventitia measurement can be justified (**Fig. 20**). More over in the follow-up after chemical or thermal ablation the only measurement possible of the treated vein will be the external diameter and then measurement adventitia-adventitia could be more suitable.

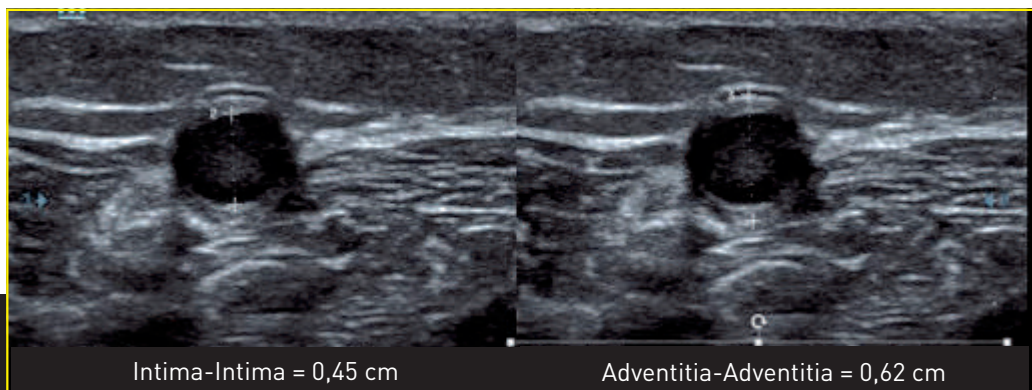


Fig. 20: Difference in vein size when measuring between intima-intima and adventitia-adventitia.

Intima-Intima = 0,45 cm

Adventitia-Adventitia = 0,62 cm

The Duplex ultrasonography investigation of varicose veins, the therapeutic strategy

| Vein irregularities

In the same way, the echography identifies partial or complete post-thrombotic or post-sclerotherapy obliterations, synechiae or tortuous vessels that would impede the progression of a stripper or fiber/catheter (**Fig. 21**).

| Should tributaries be treated at the same time as trunk removal (chemical or thermal ablation) [17]?

In sclerotherapy, the chronology of actions has not been debated for a long time. Indeed, according to the Tournay school (from top to bottom), it is customary to first treat the trunk, then during the post-therapy check-up, sclerotherapy completes the treatment on the tributaries only if necessary, as these have generally collapsed well or disappeared.

Regarding thermal ablation, the debate is still very heated.

The reasons against performing a phlebectomy at the same time as the thermal removal of the trunk are to unnecessarily treat tributary veins that may spontaneously reduce after the thermal treatment, thus avoiding the side effects of this additional procedure (haematoma, pain, inflammation, nerve damage, deep vein thrombosis, etc.), as well as the lengthy procedure time which can cause deep vein thrombosis and additional costs.

Some publications are in favor of performing phlebectomy at the same time as the endovenous procedure [18, 19].

And some are rather in favor of postponing phlebectomies [20]: they show that there are no differences in quality of life at 6 weeks according to the Aberdeen questionnaire, between patients who have had endovenous laser ablation without phlebectomy and those who have had surgery with phlebectomy at the same time.

However, the most important point is the access site.

The thermal procedure is well documented in the literature about catheterization, tumescent anesthesia, positioning of the tip of the laser fiber, the procedure performed entirely under ultrasound control, but there is little information about the ideal access point.

It is usual to start the procedure at the lowest part of the GSV or SSV incompetence. In fact, the important point is to define where to start the endovenous procedure.

Catheterization should be done at the lower part of the GSV incompetence below the knee, but through the tributary vein.

The aim is to disconnect the competent part of the GSV from the incompetent part [21] (**Fig. 22**).

If the catheterization is performed at the lower part of the incompetent GSV, but above the tributary, then after the treatment, the blood will flow from the competent part of the GSV to the incompetent tributary vein, and consequently a phlebectomy of the latter will be necessary.

However, if the GSV is accessed from the incompetent tributary vein, phlebectomy can be avoided. In order to avoid phlebectomy, the access point in the GSV is therefore essential.

Sometimes the tributary vein is very sinuous, but with hydrophilic guides it is often possible to pass through the different curves and treat it at the same time. If several veins are incompetent with straight pathways, then double or triple introductions are required to treat all of them, in addition to GSV. If the tributary paths are rather sinuous, then veno-venous shunts must be disconnected by inserting themselves underneath them (**Fig. 23**).

Finally, if a phlebectomy is necessary afterwards, this procedure is less traumatic if the vein is of reduced calibre, but in most cases, if necessary, complementary sclerotherapy under ultrasound guidance is sufficient in the majority of cases.

| The anterior accessory saphenous vein of the thigh (AASV) (As5 in CEAP) (Fig. 24).

The AASV joins the GSV close to the SFJ running on the anterior side of the thigh. It has a rectilinear path in its saphenous compartment (eye sign) to the upper 1/3 of the anterior aspect of the thigh, then has a supra fascial path anterolateral to the anterior aspect of the knee and/or the lateral aspect of the thigh.

A distinction must be made between the AASV, part of whose course is in the saphenous compartment, and an

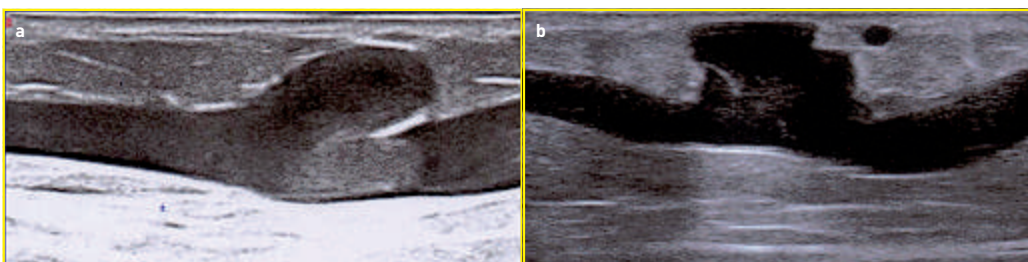


Fig. 21a, b: Dead-end.

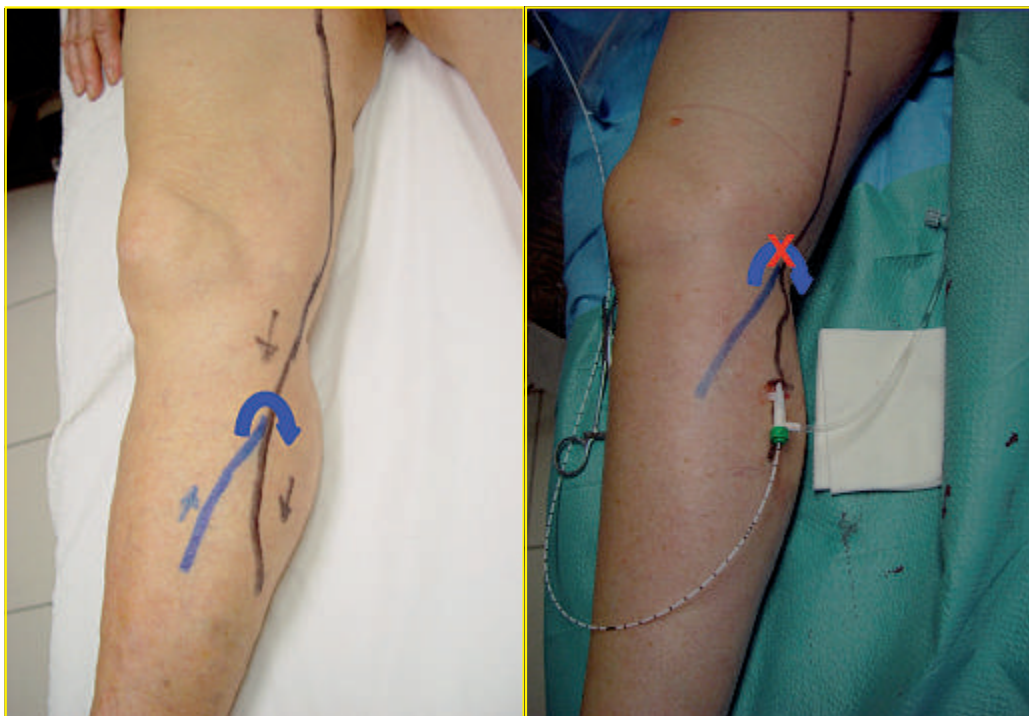


Fig. 22: Photo on the right: introduction into the GSV through the tributary vein.

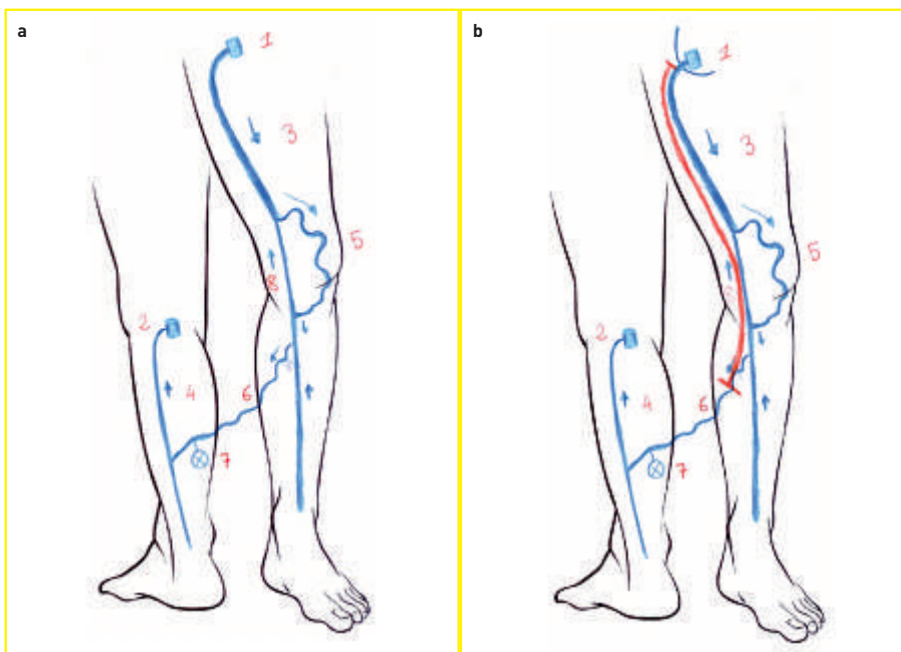


Fig. 23a, b: Veno venous shunt (drawing on the left) and example of catheterization (drawing on the right) by laser fiber (red line).
1. SFJ.
2. SPJ.
3. Incompetent GSV trunk.
4. Trunk of the competent SSV.
5. incompetent anterior tributary vein of thigh performing a veno-venous shunt.
6. incompetent posterior tributary vein of leg joining SSV.
7. Gastrocnemius perforator (a cross in a circle).
8. The GSV in the lower third of the thigh is competent.
Catheterization begins in the posterior tributary vein [6] and then proceeds up through the femoral GSV, the competent [8] and incompetent [3] part, to the SFJ.

The Duplex ultrasonography investigation of varicose veins, the therapeutic strategy

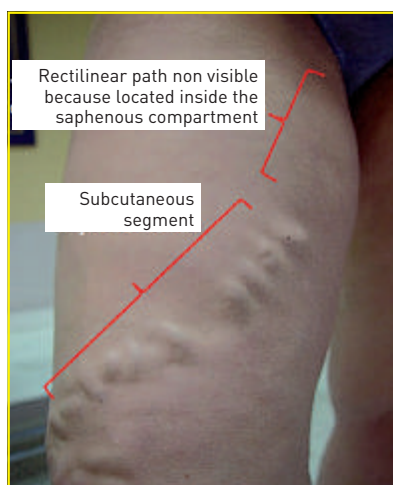


Fig. 24: Anterior accessory saphenous vein of the thigh (AASV) with its saphenous path.

anterior tributary vein of the thigh, whose course is suprafascial in its entirety and which terminates in the GSV at a distance from the SFJ.

When the incompetence concerns only this vein, it must be treated in isolation while preserving the SFJ. If a surgical option is chosen, the AASV will be tied flush to the level of its ending in the GSV.

Its inter-fascial path is more or less short, and is completely accessible to a treatment, adapted according to its diameter, by chemical or thermal ablation.

In the middle and lower 1/3 of the thigh in addition to the fascial segment, it often has a sinuous subcutaneous path that may warrant an isolated outpatient phlebectomy, but may also require chemical removal after occluding the inter-fascial segment.

When both the GSV and the AASV are incompetent, if the diameter of the AASV is sufficient to insert a fiber or catheter, they must be treated at the same time during thermal ablation.

If the AASV is incompetent and its diameter small, foam sclerotherapy will close it.

If it is neglected after the treatment of GSV, there is a risk that varicose veins in the territory of the AASV will rapidly worsen.

The posterior accessory saphenous vein of the thigh (PASV). (As5 in CEAP)

Is an anastomotic vein communicating the termination of the SSV with the termination of the GSV. It first has a rectilinear path in the axis of the limb, located in the saphenous compartment, then perforates the fascia, and becoming subcutaneous describes an arc to join the GSV

at its termination or sometimes at a variable level lower in the thigh.

It is most often referred to, for ease of reference as the Giacomini vein.

In fact, this anastomosis should be divided into 2 parts: the inter-fascial, axial part should be called the post-axial extension of the SSV (accompanied by its nerve, the posterior femoral cutaneous (formerly small sciatic) and the suprafascial part, called the Giacomini vein or better Giacomini anastomosis, which is not accompanied by a nerve.

In case of incompetence, several cases are possible: transmission of reflux from GSV to SSV through Giacomini's anastomosis (**Fig. 25**) or transmission of reflux from SSV to GSV through Giacomini's vein, which could be called paradoxical reflux (**Fig. 26**).

Paradoxical, because the direction of flow in the Giacomini vein is from bottom to top, and overloads the GSV, which becomes incompetent from this level.

Treatment by sclerotherapy under ultrasound guidance is easy, and this vein (if its diameter is large), is also quite accessible to thermal treatment, as it is usually a straight path.

The small saphenous vein (SSV) (As4 in CEAP)

GSV incompetence is the most frequent cause of varicose veins, and small saphenous vein (SSV) incompetence is identified in 20% of cases of patients with varicose vein.

However, because the termination of SSV is at a variable level, as well as its immediate proximity to nerves and arteries, its treatment is more delicate than for GSV.

Its origin and path are constant, on the other hand, its termination is very variable and even complex. At the level of the foot, it follows the lateral marginal vein, passes below the lateral and behind the lateral malleolus, rises along the edge of the Achilles tendon then crosses it, perforates the aponeurosis to become medial and vertical, located in the axis of the lower limb between the 2 gastrocnemius muscles.

The small saphenous vein, like the GSV, is located in the aponeurotic compartment (eye sign in cross section) throughout its path.

Finding the trunk of the SSV on echography is simple: just place the middle of the ultrasound probe on the posterior surface of the calf, just in the midline of the limb.

Several termination patterns have been proposed and according to P. Lemasle [22] (**Fig. 27**).

5 types can be identified:

– Its ends in the popliteal vein in a single junction at variable heights:

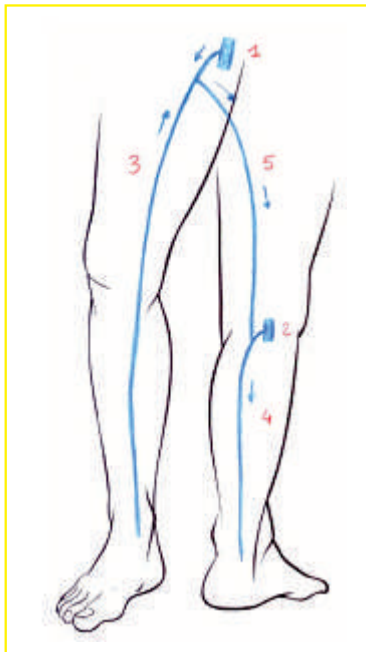


Fig. 25: Schematic diagram on the left. Transmission of SSV
 1. Incompetent SFJ.
 2. SPJ.
 3. Competent GSV trunk.
 4. Incompetent SSV trunk.
 5. Reflux of the Giacomini in its inter-fascial path.

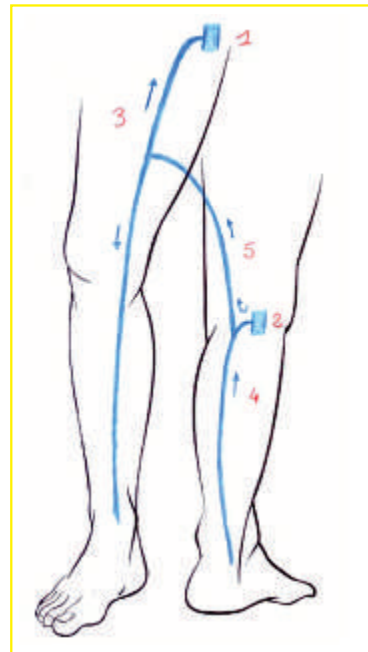


Fig. 26: Schematic on the right. Paradoxical reflux: transmission of reflux from the SPJ to the trunk of the GSV.
 1. SFJ.
 2. SPJ.
 3. Competent GSV trunk.
 4. Trunk of the competent SSV.
 5. Pathological ascending flow in its suprafascial path.

A: most often about 2 cm above (proximal) the knee crease (83%),
B: a high junction but still drained in the popliteal vein (6%).

- Sometimes there is no SPJ, and the examination reveals three main types of termination:
C: a long variety (5%), in which the SSV crosses the popliteal fossa to form the first segment of the Giacomini vein. The SSV may also terminate in the superficial

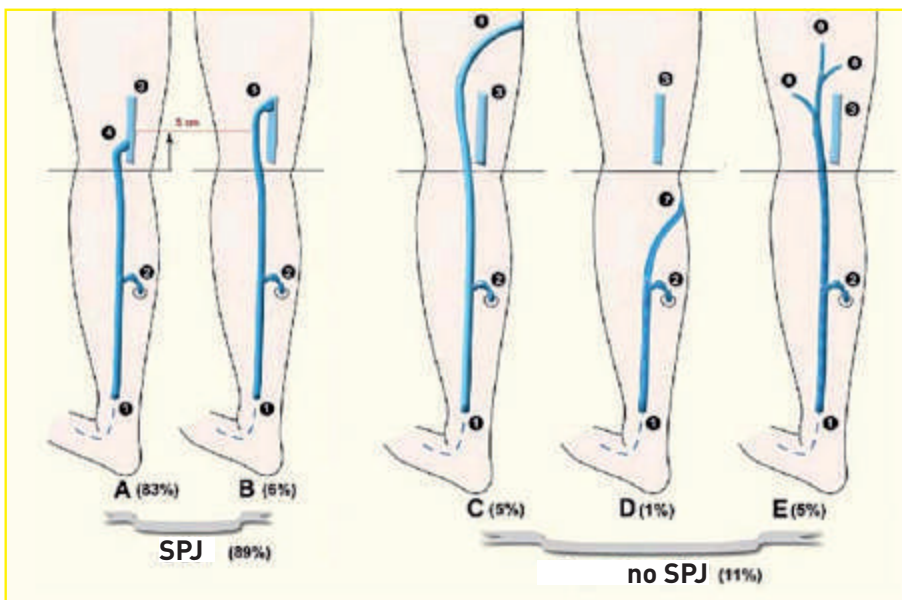


Fig. 27: Different anatomical types of SSV termination. P. Lemasle [22]
A: with modal junction (83%);
B: high junction (6%);
C: Giacomini without popliteal junction (5%);
D: Termination below the popliteal crease (1%);
E: Termination in a dorsal or cranial extension which is exhausted in the deep thigh muscle masses (5%).

The Duplex ultrasonography investigation of varicose veins, the therapeutic strategy

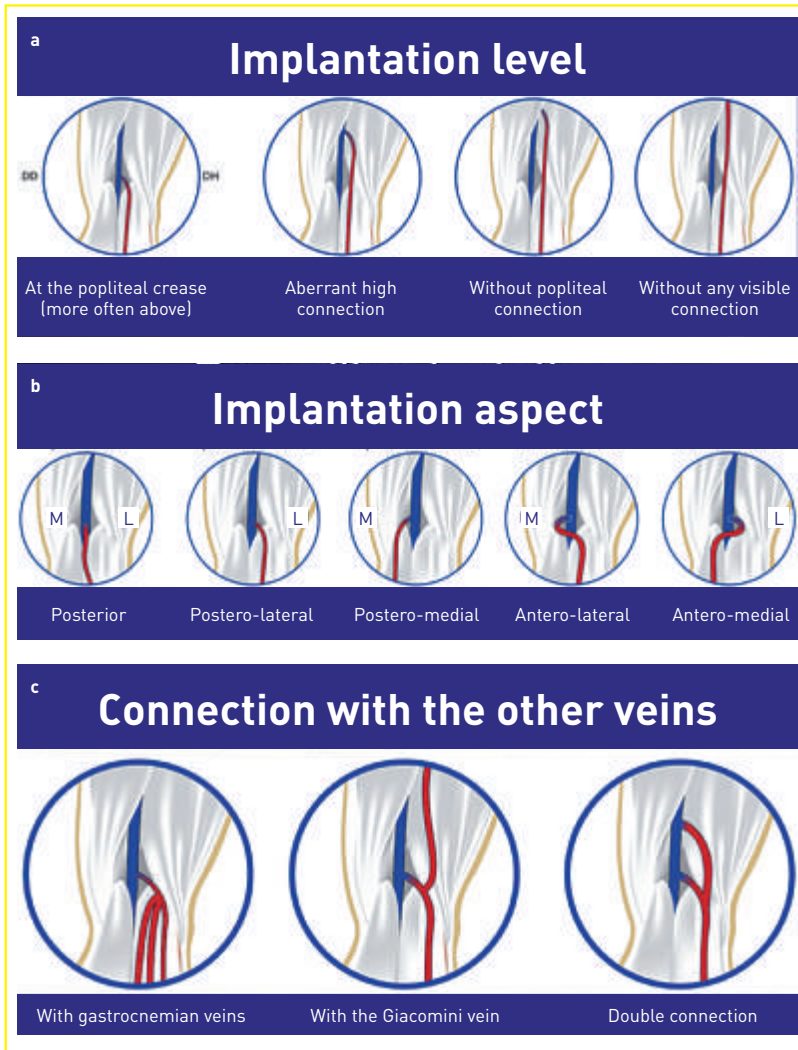


Fig. 28a, b, c: Implantation level; implantation aspect, connection with other veins.

femoral vein (more than 7 cm from the popliteal crease, this is no longer the popliteal vein), or in the deep femoral vein.

D: a short variety (1%), in which the short saphenous vein does not reach the popliteal fossa to terminate either in the medial gastrocnemius perforator or in an intersaphenous arch below the knee crease.

E: a complex termination of plexiform or river delta type (5%). The SSV terminates above the knee crease, via a network not systematized draining into the thigh muscle vein network.

The termination of the SSV in the popliteal fossa must be specified: its implantation level, its implantation face and possible connections with other veins (**Fig. 28a, b, c**).

Just for anatomical reminder, the popliteal fossa is a lozenge-shaped space, located on the posterior surface of the knee, delimited above and medially by the semitendinosus and semimembranosus muscle, and laterally by the biceps femoris muscle, and below by the lateral and medial head of the gastrocnemius muscle.

Therapeutic consequence, when the SSV ends just above the knee crease in the axis of the limb, without connection with other veins, surgery is simple.

On the other hand, when the SSV has a high termination (Lemasle's BCDE type), the risk is a rather traumatizing and unsightly surgery.

In the case of a connection between the SSV and the medial gastrocnemius veins (Gillet type B and C [23]), the

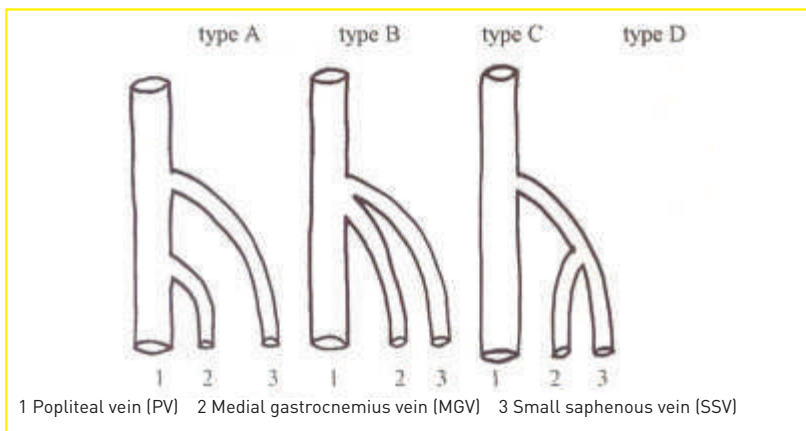


Fig. 29: Anatomical relationship between SSV and MG (gastrocnemius vein). J.L. Gillet [23].
Type A: Separate connection of the SSV and MG.
Type B: joint connection of SSV and MG.
Type C: common trunk SSV-MG.
Type D: other anatomical provisions corresponding to Lemasle's BCDE anatomical types.

competent medial gastrocnemius vein (MGV) must be spared and only the SSV must be ligated, which is sometimes difficult in surgery (**Fig. 29**).

Treatment with sclerotherapy is very simple, and does not take into account how the SSV is terminated and its possible connections with other veins.

The positioning of the tip of the fiber during thermal ablation will be at the highest point of the incompetence of the SSV, and below the termination of a competent vein (MGV or Giacomini vein).

Relationship to arteries

The SSV is accompanied throughout its path by numerous arterioles. Their distribution is highly variable and there is no preferential location rule.

On the other hand, it is very easy to detect them on ultrasound by decreasing the color Doppler speeds (PRF).

Surgery and thermal methods do not entail any particular risk at the arterial level. However, a few rare cases of arteriovenous fistula in the popliteal fossa have been described after laser or radiofrequency ablation, but probably due to perforation of the SSV by the fiber or catheter.

However, before sclerotherapy, a color Doppler check of the absence of arterioles before each puncture, must be mandatory.

Ligating an arteriole (during surgery) or burning an arteriole (by laser or radiofrequency) does not have the same potentially catastrophic consequences as injecting sclerosing agents into an artery. With the help of a pastel




Fig. 30: Pastel pencil to delineate 2 areas, after checking that there are no arterioles in the puncture area.

The Duplex ultrasonography investigation of varicose veins, the therapeutic strategy

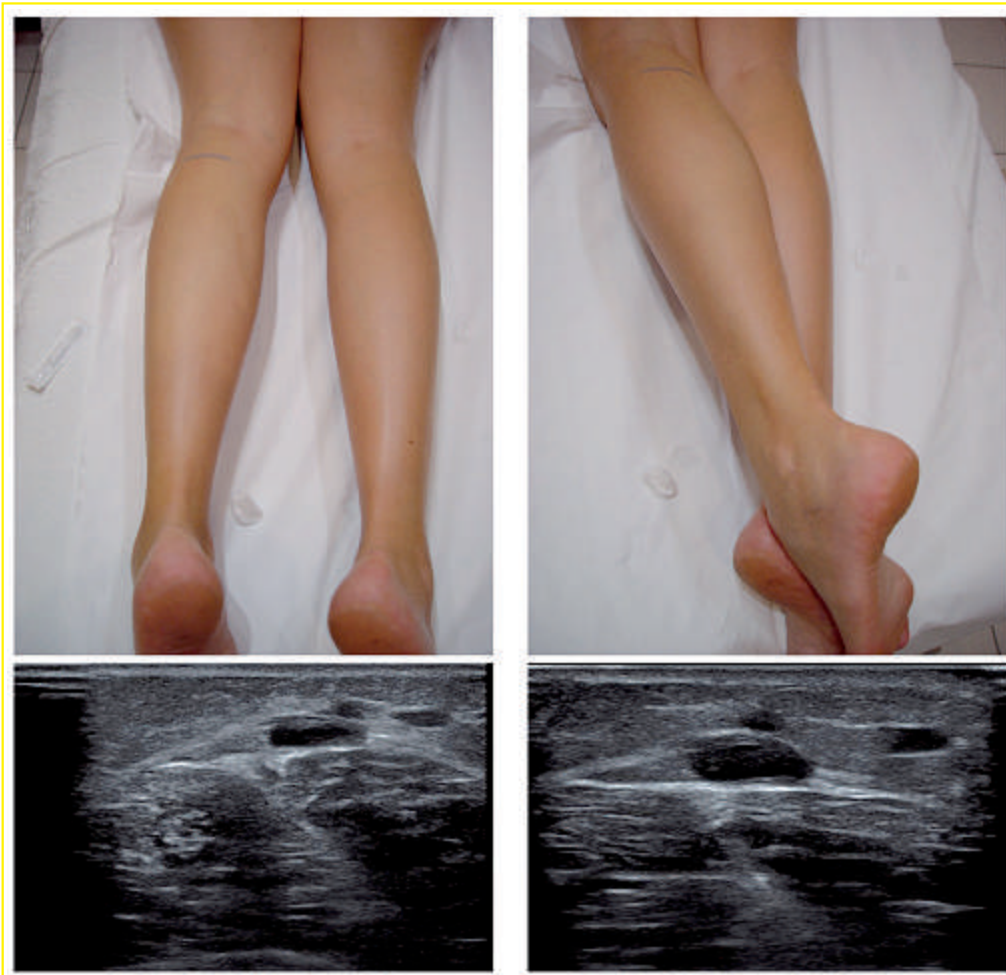


Fig. 31: Placing the instep foot of the leg on the Achilles tendon of the other leg relaxes the muscles and thus allows a better view of the SSV to be injected.

pencil (which writes in the gel) a safe puncture area can be determined.

After checking that there is no artery in the area to be punctured, simply draw a line with the pastel pencil underneath the ultrasound probe (**Fig. 30**).

Thus, two zones will be delimited: an examination zone and the ultrasound probe will be placed just above the line, and a zone below which will be the puncture zone, which can be disinfected. Thanks to this small means, we will avoid searching, just before the injection for the vein that we had identified before the preparation of the foam.

In a standing position, knees stretched out or in a prone position on the examination bed, the fascia is pulled by the gastrocnemius and hamstring muscles, resulting in compression of the vein.

In order to have a better view of the SSV, these muscles should be relaxed by asking the patient to slightly bend the knees during the examination in the standing position and while lying down, in order before injecting or puncturing the vein, to place the instep of the leg to be treated on the contralateral Achilles tendon (**Fig. 31**).

| Relationship with nerves

Paresthesias after SSV surgery are feared by surgeons. Neurological risks can be either sensitive to paresthesias or motor to steppage type.

The nerves involved are the sciatic nerve, which divides into the anterior tibial nerve and the common fibular nerve, at a variable level above the femoral condyles most often between 3.5 and 5.5 cm above the knee crease, but may have a very high division in the thigh.

This division is always lateralized (external face) most often at about 3.5 cm from the axis of the limb (**Fig. 32**). The medial sural nerve originates from the anterior tibial nerve, and the lateral sural nerve from the fibular nerve. These 2 nerves meet most often (in more than 75% of cases) at the bottom of the calf muscle, and the

innervation of these 2 sensory nerves are the lateral surface of the leg and foot, with a maximum area of hypoesthesia, ellipsoid, below the lateral malleolus. Today, high-frequency probes (at least 14 MHz) can detect all nerves [24, 25]. In the popliteal fossa, the anterior tibial nerve and the fibular nerve are still visible

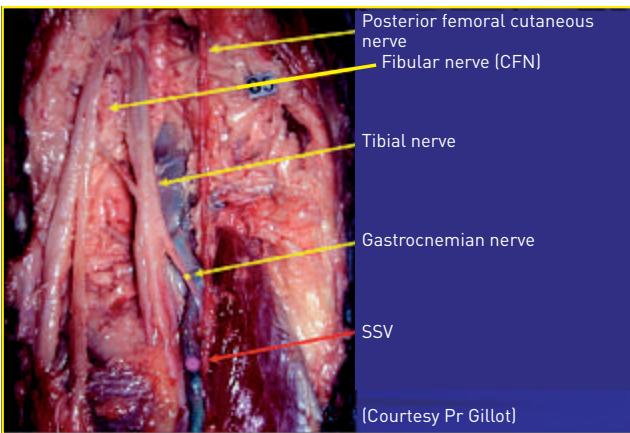


Fig. 32: Anatomical view (Pr Gillot): The posterior femoral-cutaneous nerve of the thigh is exactly in the midline with the limb. Division of the sciatic nerve is usually lateralized 3.5 cm from this axis.

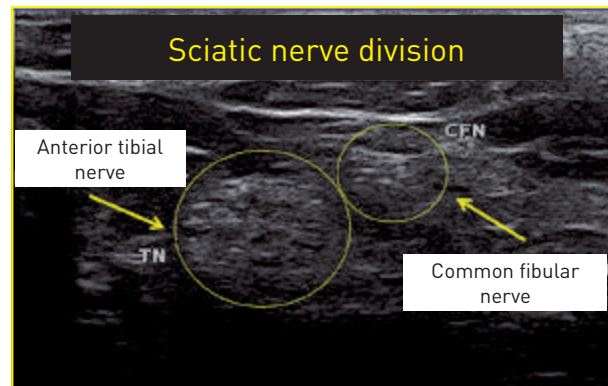
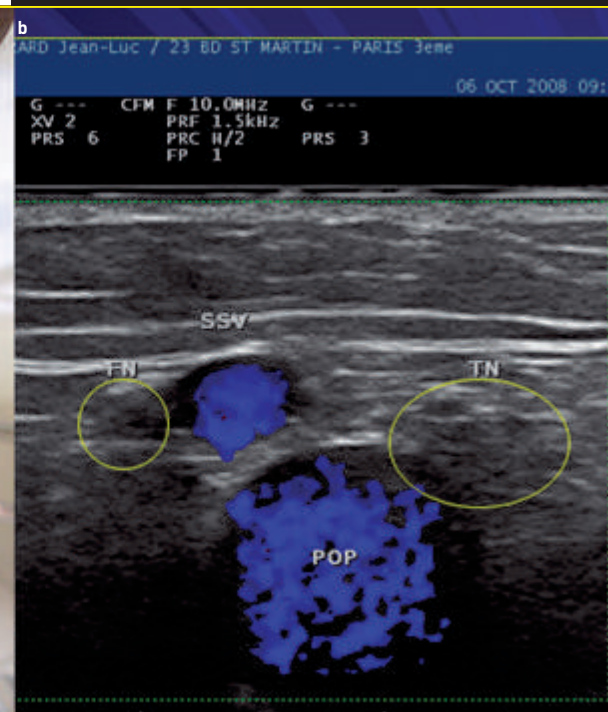
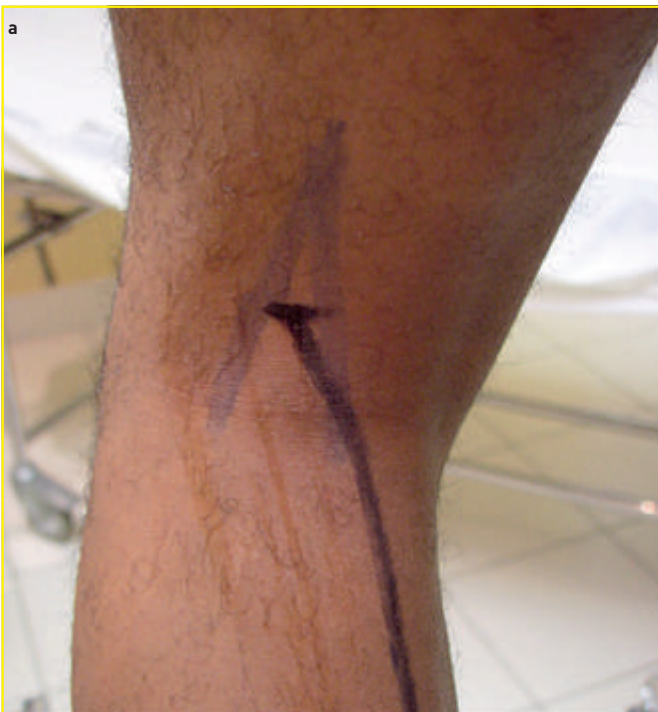

Fig. 33: Honeycomb image of nerves.

Fig. 34 ab: Example of SSV termination, top located and lateralized.
a: mapping the SSV termination (black felt pen) and mapping the sciatic nerve division (blue felt pen).
b: ultrasound image



The Duplex ultrasonography investigation of varicose veins, the therapeutic strategy

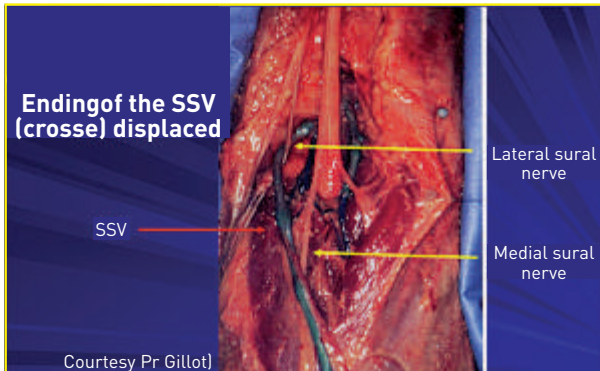


Fig. 35: Termination of lateralized SSV by hooking the sural nerve.

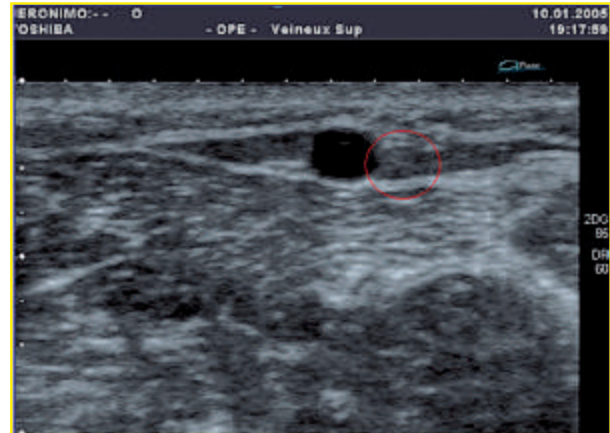


Fig. 37: SSV and sural nerve (in red circle) in the saphenous compartment (J.L. Gérard. Controversies Congress. January 2005).

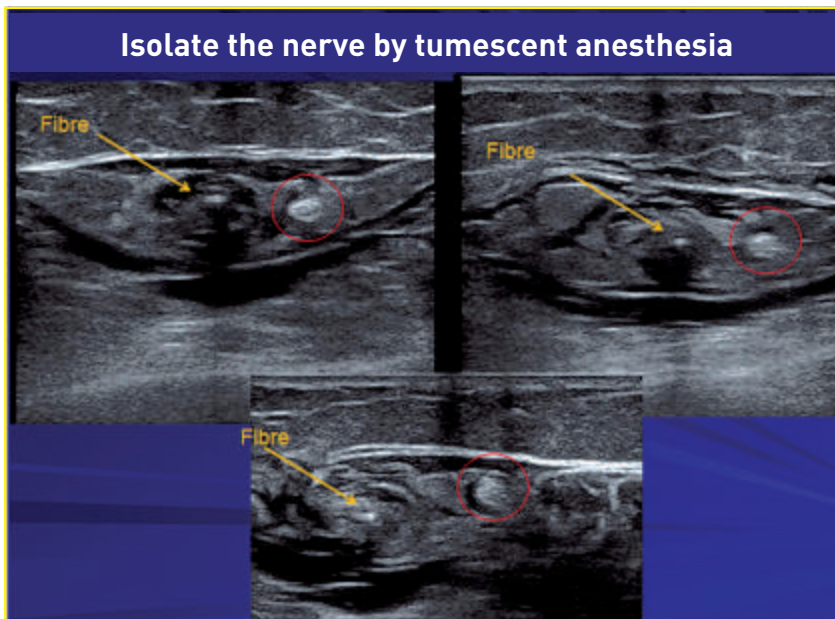


Fig. 36: During tumescent anesthesia, the nerve is isolated and pushed away from the vein.

on ultrasound with this characteristic honeycomb cross-sectional image (Fig. 33).

Due to the numerous variations in SSV terminations, preoperative mapping of this vein is widely accepted, but at the same time mapping the anterior tibial nerve, fibular nerve and sural nerves should also be systematic (Fig. 34).

In the treatment of SSV by endovenous laser ablation, there are 15 specific studies [26] that found a paresthesia rate between 1.6% and 11% for an average rate of 4%.

The identification of these nerves should further reduce this already very low rate.

At the popliteal fossa

When the termination is in the axis of the limb, usually just above the popliteal crease, the risk of nerve damage is low.

On the other hand, the higher the SSV termination (or a perforator) is located and lateralized, the greater the risk of nerve damage.

There is always a branch of the nerve, most often the fibular (**Fig. 35**), which hooks and pulls the vein into a lateral position.

In this case, vein and nerve mapping is strongly recommended.

Local tumescent anaesthesia (LTA) during endovenous laser treatment allows the vein separate the nerve, or better still, by pushing away the nerve itself from the vein by means of tumescence (**Fig. 36**).

Similarly, despite the ultrasound check, during LTA, the mapping of the nerves will prevent direct puncture and therefore nerve damage by the needle.

From the popliteal fossa to the bottom of the calf muscle, the sural nerve (most often the lateral sural nerve) may closely accompany the SSV at a variable level in the saphenous compartment of the vein (**Fig. 37**).

Fortunately, this is rare, but mapping the nerve and isolating it during tumescence should prevent paresthesia (numbness) around the lateral malleolus.

At the ankle

The nerve is always in contact and sometimes wrapped around the vein (**Fig. 38**).

Treatment of the distal part of the SSV should be avoided by endovenous thermal methods.

Perforating veins (perforators) or transfascial veins

The eponymous designation of perforators should also be abandoned and it is preferable to designate perforators according to their anatomical ratio, which allows for a common language (Table 2).

By perforating the deep fascia, a perforator is a communication between a superficial vein and a deep

Table 2: Old and new terms in the Terminologia Anatomica.

| | |
|--------------------------------------|---|
| DODD perforator | Femoral Canal Perforator (Hunterian) |
| HACH perforator | Posterolateral thigh perforator |
| Internal or external twin perforator | Medial or lateral gastrocnemius perforator |
| GILLOT's perforator | Dorsal gastrocnemius perforator |
| BOYD perforator | Paratibial perforator of the upper 1/3 of the leg |
| SHERMAN perforator | Paratibial perforator of the mid 1/3 of the leg |
| COCKETT perforator | Medial posterior tibial leg perforator perforator |
| MAY perforator | Inter-gastrocnemius perforator |
| BASSI perforator | Para-arachilles perforator |

vein, the flow of superficial veins physiologically draining towards the deep network.

For some, it is distinguished only from direct or indirect perforators and in some other countries, they will define in addition centered or non-centered perforators.

These perforators are referred to as centered perforators when they drain the saphenous trunk, and as non-centered perforators when they drain a tributary or accessory vein.

Perforators can be direct when they connect the superficial veins directly with the deep veins, and indirect when they attach the superficial veins with the deep veins via muscular veins.

Perforators can be complex, multi-branched.

They may have several points of emergence at the muscle fascia and join together above it in a single trunk, or they may have a single emergence with several trunks above the muscle fascia.

A perforator can thus communicate with 2 (or more) superficial veins, or a superficial vein can communicate with 2 (or more) deep veins.

The complexity of this connection between superficial and deep veins reflects the difficulty of perforating vein surgery.

A distinction must be made between incompetent perforators and reentry (or inflow) perforators, which allow blood from an incompetent varicose vein (saphenous or non-saphenous veins) to physiologically reach the deep venous system (**Fig. 39**).

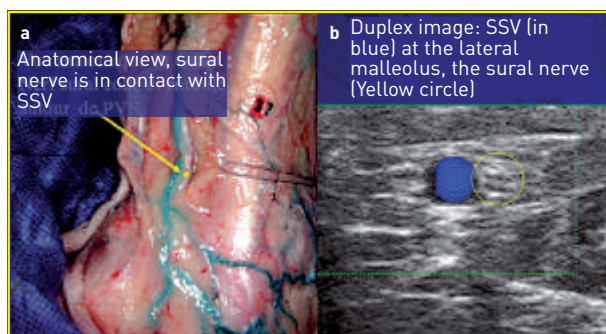
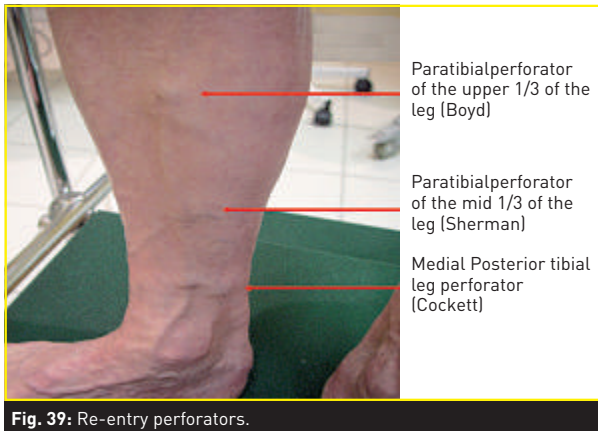


Fig. 38ab: Close relationship of the SSV and the sural nerve to the lateral malleolus.
a: anatomical view of the sural nerve (yellow arrow) and SSV.
b: ultrasound image of the SSV and the sural nerve (in yellow circle).

The Duplex ultrasonography investigation of varicose veins, the therapeutic strategy



The dilatation of the incompetent saphenous vein will gradually generate an increase in the reentry flow and, as a result, the progressive dilatation of the perforator.

Although some authors have found a correlation between the diameter of the dilated perforator and its incompetence by proposing a diameter greater than 3.5 mm, competence should be analysed by studying the direction of the flow at the Duplex.

Treating these re-entry perforators would be a mistake: the ablation (surgical, chemical or thermal) of the incompetent saphenous vein reduces the number of perforators recorded before the operation.

Incompetent perforators may be isolated, sometimes after muscle trauma, after orthopaedic surgery, or appear as part of a post-thrombotic syndrome with reflux through the leg perforators.

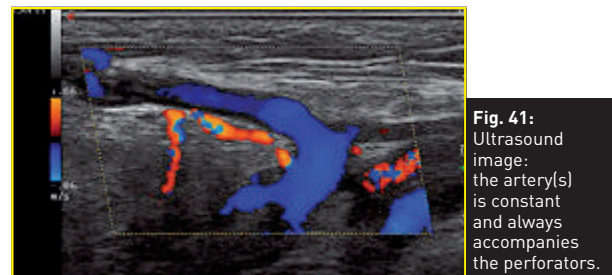
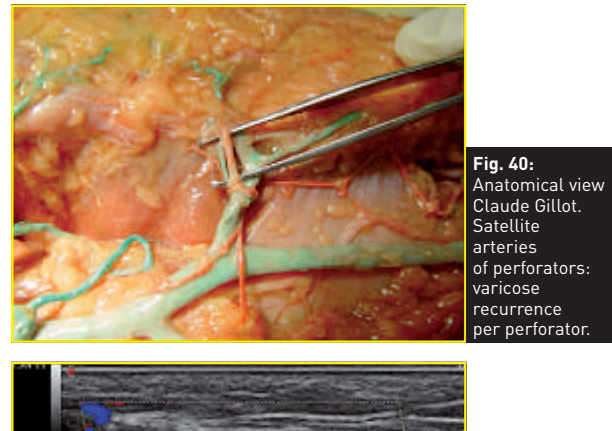
On clinical examination, the discovery of a scar from previous orthopaedic surgery should suggest the possibility of minimal unnoticed deep vein thrombosis, and a search for an incompetent perforator that could be a source of varicose veins.

Relationship to the arteries

All perforators are always accompanied by arterioles, during the crossing of the muscle fascia, some of which are wrapped around the vein (**Figs. 40, 41**) and even beyond until immediate subcutaneous area.

As with SSV, during sclerotherapy, a color Doppler check for the absence of arterioles before each puncture must be mandatory.

You may be surprised how long these arterioles are. The same pastel pencil as the one described for the SSV will be used to delimit a puncture zone, free of arteries.



Treatment of perforators

By surgical removal:

It is more traumatic with a risk of recurrence, especially in the case of indirect or multi-pedicular perforators.

By chemical ablation:

It is ideal for small-calibre perforators, but carries several risks: risk of arterial injection, risk of deep vein thrombosis in the event of post-thrombotic syndrome or large-diameter perforators, and risk of ineffectiveness in patients on anticoagulation treatment or in the event of incompetent of very large-calibre perforators.

The injection must be made in the varicose veins, at a distance from the emergence of the perforator of the muscle fascia. The injection should never be made into the perforator itself.

By thermal ablation:

The advantages of this method are:

- the absence of vascular problems at first in the most obese patients,
- no risk of infection due to ultrasound guided puncture,
- no contraindications in patients on anticoagulation treatment,
- no risk of arterial injury,
- less risk of deep vein thrombosis as no intravenous injection is required,
- and finally, greater efficiency for large diameter perforators.

Delicate and meticulous in execution, it should however be reserved for very large calibre perforators.

We'll distinguish:

- **Incompetent centered perforators: most often of the thigh, source of incompetence of the underlying (upstream) saphenous trunk.**
- **And incompetent non-centered perforators: independent of the saphenous trunk (most often in the leg) and which may appear after varicose vein surgery.**
- **For centered perforators, the end of the fiber/catheter is positioned in the saphenous trunk, immediately underlying the perforator's endpoint, and in the same way as for a SFJ or SPJ (which are in fact the first perforators) the energy at this level is increased (most often doubling).**
- **For non-centered perforators, position the fiber/catheter in the perforator just above its emergence from the muscle fascia.**

A special case, the popliteal fossa perforator:

It can be completely isolated without incompetence of SSV

or GSV, and without any relation to varicose recurrence after surgery.

Always located 2 to 3 cm above the knee crease on the lateral aspect of the popliteal vein, most often unrelated to the SSV, and which exploration of the SSV alone does not always reveal.

When exploring the SSV, the entire popliteal fossa should also be systematically explored for a possible popliteal perforator on its lateral area, and for a possible independent perforator on its upper part, located well above the SSV termination.

According to the theory put forward by Prof. Gillot, this perforator could have originated from a compression of the popliteal vein during the crossing of the Hunter's canal (adductor canal). The narrowness of the canal in some patients may compress the vein, resulting in deep upstream venous hyperpressure.

The perforator would act as a safety valve. This theory could also explain the more frequent varicose recurrences in the popliteal fossa.

Pelvic leak points

They are systematically looked for, in case of atypical varicose veins or perineal veins, in case of symptoms of pelvic congestion, or early varicose recurrence.

Incompetence of perineal veins does not necessarily spread over the GSV trunk, sometimes to the SSV via the PASV (**Fig. 42ab**), or only the AASV is involved, sometimes all 3 are incompetent to varying degrees.

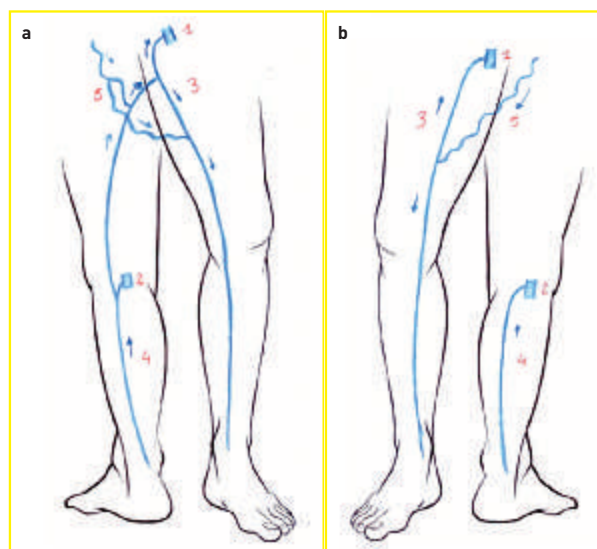


Fig. 42ab: Example of varicose veins of the thigh and leg with perineal starting point.

1. Competent saphenofemoral junction.
2. The small saphenous vein is competent.
3. The trunk of the great saphenous vein.
4. The trunk of the small saphenous vein remains competent.
5. Incompetent perineal veins transmit reflux to the suprafascial collateral of the thigh; Giacomini's vein transmits reflux from the perineal veins to the great saphenous vein.

Foam sclerotherapy can easily treat these varicose veins, which are often small in size and sinuous.

If this fails, pelvic embolization may be considered.

Vicarious veins

When a superficial vein compensates a deep vein obstruction, it is called a vicarious vein.

The superficial veins involved are essentially the GSV, by compensation in case of obstruction of the femoral (superficial) vein, but with permeability of the common femoral vein. The suprapubic veins are one of the main pathways of diversion (natural Palma) in case of iliac thrombosis and the abdominal subcutaneous veins in case of ilio caval obstruction (**Fig. 43**).

A vicarious superficial vein, even a dilated one, is not a varicose vein. Its flow is permanent, rhythmed by the breathing and there is no reflux.

But when the deep network, previously thrombosed, recanalizes, this same superficial vein can lose its vicarious function, it can then thrombose or become varicose.

This vicariance can be confirmed by a stress test, the venous equivalent of the stress test in the arterial Duplex, which will accentuate this phenomenon.

The Duplex ultrasonography investigation of varicose veins, the therapeutic strategy

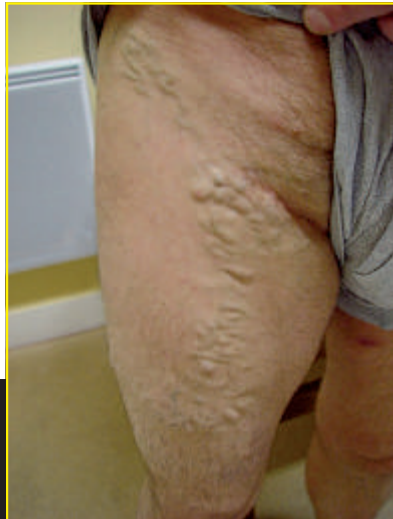

Fig. 43: Development of flank varicose veins and abdominal subcutaneous veins during iliocaval occlusion.

Carried out in a standing position, after 10 flexion-extensions of the knees, if the GSV is vicarious, a significant spontaneous flow of physiological centripetal direction will be objectified at the level of the GSV.

Therapeutic consequence: the removal of vicarious GSV would be a mistake, as it would remove part of the deep venous return with the risk of increasing the edema of the legs.

In case of recanalization of the deep veins, GSV can be treated if it becomes incompetent, and suprapubic varicose veins, if they become symptomatic and cause real discomfort.

Varicose recurrence

After surgery, the recurrence rate at 5 years is estimated to be between 25 and 50% according to some prospective studies [26, 27, 28].

Thermal ablation, although with less follow-up (2001 to 2016), appear to show less short-term recurrency [29].

In 2000 [30], Perrin defined a new acronym REVAS (Recurrent Varices after Surgery) as the presence of clinical varicose veins on a lower limb previously treated by surgery.

In 2009 [31], the terminology of PREVAIT (PREsence of VARices after operative InTervention) extends the notion of recurrence not only after surgical treatment but also after any ablative technique (surgical, chemical or thermal).

The term PREVAIT therefore includes not only "true" recurrences (recurrent varicose veins) linked to the evolution of the disease itself, located at a distance from the operated area, but also residual varicose veins located in the area already operated on.

Often used with varicose vein recurrence, we will speak (almost exclusively in France) of unsystematized varicose veins in front of diffuse, scattered varicose veins, without direct link with saphenous incontinence and systematized varicose vein when a saphenous trunk (a part longer or shorter) source of varices remained in place.

Mechanisms of recidivism

– Residual varicose veins can be due to different causes:

- either because of an imprecise initial diagnosis (tactical error), by ignorance of sources of perineal reflux or perforators,
- either by error of therapeutic strategy, the voluntary conservation of the trunk or partial ablation of the trunk of the great saphenous vein does not lead to an improvement in post-operative symptomatology,
- or by technical error of realization:
 - insufficient or incorrect initial surgery,
 - all sources of reflux that have not been eliminated at the junction,
 - incompetent perforators,
 - duplicate veins.

"Modern" surgery, under ultrasound control, should limit this residual varicose veins.

– Finally, recurrent varicose veins, even after a correctly performed surgery, without any technical fault, can be due to the progression of the varicose disease.

- Neovascularization to the previous SFJ or SPJ,
- Incompetent perforators,
- perineal varicose veins in case of multiple pregnancies after a first varicose vein treatment.

A surgical operation without control, nor regular postoperative follow-up, leads to a varicose recurrence in the more or less long term.

This is why a phlebological scanning by echo-doppler is essential in the search for recurrent varicose veins in their early stages. It is widely accepted, both by vascular physicians and surgeons [32], that the treatment of varicose recurrence is easily controlled by foam sclerotherapy, whether in the groin, perineal veins, perforating veins, or a tributary of the thigh or leg. Redo surgery of the previous SFJ or SPJ is no longer necessary. Indeed, ultrasound-guided foam sclerotherapy requires no hospitalization, no anesthesia, no work stoppage, and is an easy, reliable and effective technique.

In conclusion

Duplex ultrasound investigation of the superficial veins of the lower limbs is an important part of the vascular physician's job.

This examination can only be reliable if the examiner has a good knowledge of vein anatomy and its variants, combined with good practice in ultrasound exploration of veins.

The sclerotherapy treatment is suitable regardless the location, size and depth of the varicose veins but cannot be limited only to those who are visible.

Thanks to the ultrasound-guided puncture, all varicose veins can be injected.

The treatment must start at the origin of the reflux (French method, top-down).

Thermal ablation treatments cannot be considered without the use of ultrasound.

According to the CNAM report [33], these thermal procedures should take a more prominent place in the

therapeutic arsenal: "These new techniques would nevertheless allow for lighter interventions, facilitating access to care in safe environments outside the operating theater and reducing the risks of recurrence compared to the surgical "stripping" method with general anaesthesia. They finally allow a faster recovery and return to work".

Finally, in order for the patient to give truly informed consent, the vascular physician must provide information that is as complete and objective as possible.

Therefore, in order to propose the most appropriate treatment, the therapist should be familiar with the different possible techniques and use at least one or more of these other techniques.

Bibliography

- [1] Melliere D. Why and when to preserve the saphenous veins of varicose patients to serve as an arterial bypass? *J Mal Vasc.* 1994; 19(3): 216-21.
- [2] Cavezzi A., Labropoulos N., Partsch H., Ricci S., Caggiati A., Myers K., *et al.* Duplex ultrasound investigation of the veins in chronic venous disease of the lower limbs—UIP consensus document. Part II. Anatomy. *Eur J Vasc Endovasc Surg.* 2006; 31: 288-99.
- [3] Zamboni P., Escribano J.M. "Reflux Elimination Without any Ablation or Disconnection of the Saphenous Vein. A Haemodynamic Model for Venous Surgery" and "Durability of Reflux-elimination by a Minimal Invasive CHIVA Procedure on Patients with Varicose Veins. A 3-year Prospective Case Study". *Eur J Vasc Endovasc Surg.* 2004 Nov; 28(5): 567.
- [4] Pittaluga P., Chastanet S., Locret T., Barbe R. The effect of isolated phlebectomy on reflux and diameter of the great saphenous vein: A Prospective Study. *Eur J Vasc Endovasc Surg.* 2010; 40(1): 122-8.
- [5] Caggiati A., Bergan J.J., Gloviczki P., Jantet G., Wendell-Smith C.P., Partsch H. International Interdisciplinary Consensus Committee on Venous Anatomical Terminology. Nomenclature of the veins of the lower limbs: an international interdisciplinary consensus statement. *J Vasc Surg.* 2002; 36: 416-22.
- [6] Bailly M. Cartography CHIVA. In Editions Techniques Encyclopédie Médico-chirurgicale 1995. Paris: 43-161-B;1-4.
- [7] Lemasle P., Uhl J.F., Lefebvre-Villardebo M., Baud J.M. Proposal of an ultrasound definition of the great saphenous vein and accessory saphenous veins at the crural level. *Phlebology* 1996; 49(3): 279-85.
- [8] Lemasle P. Atlas of superficial venous echo-anatomy. Volume 1. The great saphenous vein, Volume 2. The small saphenous vein, Volume 3. Varicose recurrence. Éditions Laboratoire Tonipharm.
- [9] Mühlberger D., Morandini L., Brenner E. Venous valves and major superficial tributary veins near the saphenofemoral junction. *J Vasc Surg.* 2009; 49(6): 1562-9.
- [10] Perrin M. Open surgery for superficial venous insufficiency. Principles. Technical. EMC results. 19/06/2007 (43-161- B).
- [11] Cappelli M., Molino Lova R., Ermini S., Giangrandi I., Giannelli F., Zamboni P. Hemodynamics of the sapheno-femoral complex: an operational diagnosis of proximal femoral valve function. *Int Angiol.* 2006 Dec; 25(4): 356-60.
- [12] Cappelli M., Molino Lova R., Ermini S., Zamboni P. Hemodynamics of the sapheno-femoral junction. Patterns of reflux and their clinical implications. *Int Angiol.* 2004; 23(1): 25-8.
- [13] Kabnick L.S., Ombrellino M., Agis H., Mortiz M., Almeida J., Baccaglioni U., *et al.* Endovenous heat induced thrombus (EHIT) at the superficial-deep venous junction: a new post-treatment clinical entity, classification and potential treatment strategies. 18th Annual Meeting of the American Venous Forum. Miami, Florida 2006.
- [14] Blanchemaison P., Grenay P. Atlas of anatomy of superficial veins of the lower limbs. Publisher Servier Laboratories.
- [15] Rudarakanchana N., Berland T.L., Chasin C., Sadek M., Kabnick L.S. Arteriovenous fistula after endovenous ablation for varicose veins. *J Vasc Surg.* 2012 May; 55(5): 1492-4.
- [16] C-illotine. An anatomical atlas of the superficial venous devices of the lower limbs. Éditions Phlébologiques Françaises, 1998.

The Duplex ultrasonography investigation of varicose veins, the therapeutic strategy

- [17] Gerard J.L. Ambulatory phlebectomy as a simultaneous treatment after endo thermal ablation is not mandatory. Controversies congress CACVS 2016. Venous Session.
 - [18] Lane T.R., Kelleher D., Shepherd A.C., Franklin I.J., Davies A.H. Ambulatory varicosity avulsion later or synchronized (AVULS): a randomized clinical trial. *Ann Surg.* 2015; 261(4): 654-61.
 - [19] El-Sheikha J., Nandhra S., Carradice D., Wallace T., Samuel N., Smith G.E., Chetter I.C. Clinical outcomes and quality of life 5 years after a randomized trial of concomitant or sequential phlebectomy following endovenous laser ablation for varicose veins. *Br J Surg.* 2014; 101(9): 1093-7.
 - [20] Brittenden J., Cotton S.C., Elders A., Ramsay C.R., Norrie J., Burr J., Campbell B., Bachoo P., Chetter I., Gough M., Earnshaw J., Lees T., Scott J., Baker S.A., Francis J., Tassie E., Scotland G., Wileman S., Campbell M.K. A randomized trial comparing treatments for varicose veins. *N Engl J Med.* 2014; 25, 371(13): 1218-27.
 - [21] Gerard J.L. What is new in laser treatment of the saphenous and perforating veins? Chap 9: 349-354. Mayo Clinic - International Vascular Symposium 2011. *Advances and Controversies in Vascular Medicine. Vascular Surgery and Endovascular Interventions.* Editors Głowiczki P., Shields R.C., Bjarnason H., Becquemin J.P., Głowiczki M.L.
 - [22] Lemasle P., Uhl J.F., Lefebvre-Villardebo M., Baud J.M., Tamisier D., Cornu-Thénard A. Echosurgical confrontation of short saphenous vein termination in exeresis surgery. Preliminary results. *Phlebology* 1995; 48(3): 321-7.
 - [23] Gillet J.L., Perrin M., Hiltbrand B., Bayon J.M., Gobin J.P., Calvignac J.L., Grossetête C. Pre and postoperative contribution of Doppler ultrasonography in superficial venous surgery of the popliteal fossa]. *J Mal Vasc.* 1997; 22(5): 330-5.
 - [24] Ricci S. Ultrasound observation of the sciatic nerve and its branches at the popliteal fossa: always visible, never seen. *Eur J Vasc Endovasc Surg.* 2005; 30: 659-63.
 - [25] Gérard J.L. The Little Saphenous Vein (PVS): anatomical specificities and therapeutic traps. FPSC 2014. FPS Session March 21, 2014.
 - [26] Gad M.A., Saber A., Hokkam EN. Assessment of causes and patterns of recurrent varicose veins after surgery. *N Am J Med Sci.* 2012; 4(1): 45-8.
 - [27] van Rij A.M., Jiang P., Solomon C., Christie R.A., Hill G.B. Recurrence after varicose vein surgery: a prospective long-term clinical study with duplex ultrasound scanning and air plethysmography. *J Vasc Surg.* 2003; 38(5): 935-43.
 - [28] Kostas T., Ioannou C.V., Touloupakis E., Daskalaki E., Giannoukas A.D., Tsetis D., Katsamouris A.N. Recurrent varicose veins after surgery: a new appraisal of a common and complex problem in vascular surgery. *Eur J Vasc Endovasc Surg.* 2004; 27(3): 275-82.
 - [29] Carradice D., Mekako A.I., Mazari F.A., Samuel N., Hatfield J., Chetter I.C. Clinical and technical outcomes from a randomized clinical trial of endovenous laser ablation compared with conventional surgery for great saphenous varicose veins. *Br J Surg.* 2011; 98(8): 1117-23.
 - [30] Perrin M.R., Guex J.J., Ruckley C.V., dePalma R.G., Royle J.P., Eklof B., Nicolini P., Jantet G. Recurrent varices after surgery (REVAS), a consensus document. REVAS group. *Cardiovasc Surg.* 2000; 8(4): 233-45.
 - [31] Eklof B., Perrin M., Delis K.T., Rutherford R.B., Głowiczki P. American Venous Forum. European Venous Forum. International Union of Phlebology. American College of Phlebology; International Union of Angiology. Updated terminology of chronic venous disorders: the VEIN-TERM transatlantic interdisciplinary consensus document. *J Vasc Surg.* 2009; 48: 498-501.
 - [32] Pavei P., Ferrini M., Spreafico G., Nosadini A., Piccioli A., Giraldi E., Baccaglioni U. Ultrasound guided foam sclerotherapy of recurrent varices of the great and small saphenous Vein: 5-Year Follow Up Veins and Lymphatics 2014; 3, 2.
 - [33] Health insurance report on expenses and income for the year 2013. Findings: 20-21. <http://www.ameli.fr/rapport-charges-et-products-2013/appli.htm>
 - [34] Lurie F., Passman M., Meisner M., Dalsing M., Masuda E., Weich H., Bush RL., Blebea J., Carpentier PH., De Maeseneer M., Gasparis A., Labropoulos N., Marston WA., Rafetto J., Santiago F., Shortell C., Uhl J.F., Urbanek T., van Rij A., Ekiof B., Głowiczki P., Kistner R., Lawrence P., Moneta G., Padberg F., Perrin M., Wakefield T., *J Vasc Surg Venous Lymphat Disord.* 2020 May;8(3):342-352 The 2020 update of the CEAP classification system and reporting standard.
 - [35] Franceschi C. Mesures et interpretation des flux veineux lors des manœuvres de stimulation. Compressions manuelles et manœuvre de Paraná. Indice dynamique de reflux (IDR) et Indice de Psatakis, (Measures and interpretation of venous flow in stress tests. Manual compression and Paraná manoeuvre. Dynamic reflux index and Psatakis index). *J Mal Vasc.* 1997 May;22(2):91-5.
-