Aucun article ou résumé dans cette revue ne peut être reproduit sous forme d'imprimé, photocopie, microfilm ou par tout autre procédé sans l'autorisation expresse des auteurs et de l'éditeur. Editions Phlébologiques Françaises
No article or abstract in this journal may be reproduced in the form of print, photocopy, microfilm or any other means without the express permission of authors and the editor. Editions Phlébologiques Françaises

Phlébologie ANNALES VASCULAIRES 2010, 63, 3, p. 31-38

SOCIÉTÉ FRANÇAISE DE PHLEBOLOGIE
SOCIÉTÉ CANADIENNE DE PHLÉBOLOGIE
CANADIAN SOCIETY OF PHLEBOLOGY

New approach of the classification of vascular anomalies.

Une nouvelle approche de la classification des anomalies vasculaires congénitales.

Roche E.[1], Muchart Lopez J.[2]

Summary

Even though vascular anomalies are not uncommon in newborns (estimated to affect up to 12%), there is considerable confusion over the correct diagnosis. Thus misdiagnosis is also common as a misnomer. Some clinics tend to use inappropriate terms because there are different manifestations and syndromes treated by several specialties such as dermatologists, paediatricians, vascular and plastic surgeons, geneticists and angioradiologists.

From the ancient superstitious belief that ascribed these lesions to cravings to the present, there have been numerous classifications.

The most widely accepted classification is Mulliken and Glowaki (1982), which was based on biological features. Its biological and proliferation activity defined two groups:

1) vascular tumors and hemangiomas;

2) vascular malformations.

Later in Hamburg in 1988, a new classification was published, based on the predominant composition of the lesion. This classification was useful for decision-making because it defined whether the lesion was formed by arteries, veins, A-V shunts or combined tissues.

In Rome in 1996 at an ISSVA meeting, the Mulliken Classification was slightly modified **(Table 1)**.

All these classifications aim at helping plan the therapeutic strategy.

A good classification not only allows correct diagnosis but also provides the specialist with a global view in order to plan disease management. Despite the fact that most cases are not severe, this kind of patient sometimes needs complementary examinations with a long follow-up and in certain cases an invasive procedure.

Résumé

Bien que les anomalies vasculaires ne soient pas rares chez les nouveaux nés (taux estimé jusqu'à 12 %), il persiste des confusions considérables pour arriver à un diagnostic correct. Certains cliniciens ont tendance à utiliser des termes inappropriés car les manifestations et les syndromes, différents, sont traités par plusieurs spécialistes de cultures très différentes : dermatologues, pédiatres, chirurgiens vasculaires et esthétiques, généticiens et radiologues vasculaires.

Depuis les croyances superstitieuses des temps anciens qui les attribuaient aux fringales des femmes enceintes jusqu'à présent, il y a eu de nombreuses classifications.

La classification la plus largement acceptée est celle de Mulliken et Glowaki (1982), qui était basée sur des caractéristiques biologiques. Leur potentiel biologique et prolifératif ont permis de définir deux groupes :

1) les tumeurs vasculaires et les hémangiomes ;

2) les malformations vasculaires.

Plus tard, à Hambourg en 1988, une nouvelle classification a été publiée, basée sur la composition prédominante de la lésion. Cette classification a été utile pour la prise de décision, car elle permettait de déterminer si la lésion est formée par des artères, des veines, des shunts A-V ou des combinaisons de ces tissus.

*A Rome en 1996 pendant un congrès de l'ISSVA, la classification de Mulliken a été légèrement modifiée **(Tableau 1)**.*

Toutes ces classifications ont pour objet d'aider à la stratégie thérapeutique et à sa planification.

Une bonne classification permet non seulement un diagnostic correct, mais elle fournit aussi au spécialiste une vue globale qui lui permet d'organiser la prise en charge de la maladie. Bien que la plupart des cas ne soient pas sévères, ces patients ont parfois besoin d'examens complémentaires et d'un suivi au long cours et, dans certains cas, d'une procédure invasive.

1. *Dr. Enrique Roche Rebollo. Hospital Plató. C/Plato nº 21 08006 Barcelona, Spain. Tel 0034607995620.*
E-mail : Enric.roche@hospitalplato.com
2. *Hospital Universitari Sant Joan de Déu, CRC Plató, Barcelona, Spain.*
Accepté le 15 mars 2010

Aucun article ou résumé dans cette revue ne peut être reproduit sous forme d'imprimé, photocopie, microfilm ou par tout autre procédé sans l'autorisation expresse des auteurs et de l'éditeur. Editions Phlébologiques Françaises
No article or abstract in this journal may be reproduced in the form of print, photocopy, microfilm or any other means without the express permission of authors and the editor. Editions Phlébologiques Françaises

Due to the difficulty in managing these patients, a new approach to the classification is proposed, emphasising four clinical aspects to consider with regard to vascular lesion, summarised in the acronym LADS **(Table 2)**.

L: Life-threatening situations.

A: Associations with other diseases.

D: diagnostic algorithm.

S: Strategy or therapeutic plan.

This guide may be useful not only for decision-making but also for adequate referral.

This reason alone justifies the promotion of reference centres where accumulative experience can offer the patient the most appropriate treatment.

En raison de la difficulté de la prise en charge de ces patients, une nouvelle approche pour la classification est proposée. Cette approche souligne quatre aspects cliniques à prendre en compte face à une lésion vasculaire, exprimé par l'acronyme LADS ***(Tableau 2)****.*

L: situations mettant en danger le pronostic vital.

A: associations avec d'autres maladies.

D: algorithme diagnostique.

S: stratégie ou prise en charge thérapeutique.

Ce guide pourrait s'avérer utile non seulement pour la prise de décision, mais aussi pour une orientation appropriée des patients.

Pour cette raison seule, la promotion des centres de référence, où grâce à une expérience cumulée on peut proposer aux patients le traitement le plus approprié, est justifiée.

1. – Vascular tumors
Hemangiomas
Superficial (capillaries and strawberry birthmarks)
Deep and intramuscular
Combined
Congenital hemangioma
Other tumors
Kaposi hemangioendothelioma
Spindle-cell
Hemangiopericytoma
Glomangioma
Angiosarcoma
2. – Vascular malformations
Simple
Capillary (port-wine stain, nevus flammeus)
Venous
Lymphatic (lymphangioma, cystic hygroma)
Arterial
Combined
Arteriovenous fistulae
Arteriovenous malformation
Complex malformations
Low-flow (Klippel-Trenaunay S.)
High-flow (Parkes-Weber S.)

TABLE 1 : Vascular anomalies. Classification modified by ISSVA. Rome 1996.

1. – Life-threatening situations
Airway compromise
Hemodynamic / cardiac compromise
Neuroocular invasion
Coagulopathy
2. – Associations
Neurologic diseases
Phace (s)
Orthopedic syndromes
Visceral extension
3. – Diagnosis plan
Clinical examination
Duplex
X-ray
MRA/CAT
4. – Strategy of treatment
Hemangioma or tumor - Vascular malformation

TABLE 2 : LADS classification.

Introduction

Marks or stigmas appearing on newborns have been referred to since ancient times. Such marks were often attributed to magical or religious origins and were frequently considered punishment of the child by the gods.

While the origin of such lesions remained unknown, it was necessary to find an anatomical means of classifying such natural quirks which, curiously, might appear in recurring patterns, such as sickle-shaped marks on the forehead, an accumulation of purple-red clusters on the forehead and face or pale pink maculae on the shoulders and thorax.

Aucun article ou résumé dans cette revue ne peut être reproduit sous forme d'imprimé, photocopie, microfilm ou par tout autre procédé sans l'autorisation expresse des auteurs et de l'éditeur. Editions Phlébologiques Françaises
No article or abstract in this journal may be reproduced in the form of print, photocopy, microfilm or any other means without the express permission of authors and the editor. Editions Phlébologiques Françaises

The first histological studies that helped provide one of the first classifications were carried out in the 19th century and are attributed to Virchow. This physiologist classified tumors on the basis of tissue architecture. Depending on how cell structures and different canalicula were grouped, they were characterized as angioma simplex, cavernosum or racemosum.

Also during the 19th century, Wegner contributed to the proper understanding of these lesions by studying those whose main component was lymph tissue. This histomorphological classification divided such lesions into: simple, cavernous and cystic lymphangiomas.

In 1908, Adami made a very significant refinement to properly understanding the development of these lesions. For the first time, this author defined «angioma» as a vascular tumor with independent growth.

The complexity and variability of this pathology was one of the reasons why it was many years before a more complete and clear classification appeared.

Current classifications

• In 2004 and 2007 Redondo published a number of exhaustive reviews of the classification of vascular malformations and global approaches to them [1, 2].

• The first complete classification is attributed to Mulliken and Glowaki in 1982 **(Table 3)**. This classification was based on the study of the composition of the predominant endothelium and on biological findings from the analysed tissue.

These studies observed the biological activity of the lesion, differentiating between those that developed naturally through growth due to cell proliferation or hyperplasia and those that tended towards hypertrophy. It was shown that their behavior and prognosis were different and thus required different strategic approaches [3].

In 1988, at an interdisciplinary meeting held in Hamburg, variations were added to the Mulliken classification, taking truncal and extra-truncal composition as a discriminatory criterion. This was then related to the embryological moment of the appearance of the defect.

These types of defects were categorized as being predominantly arterial, venous, arterio-venous shunt or communication or a combination of defects. Each one could be a limited or infiltrating lesion and could be caused by dilation, aplasia or vascular obstruction.

In 1988, Mulliken and Young published a modification to the original classification, which was adopted in Rome in 1996 by the International Society for the Study of Vascular Anomalies (ISSVA). **Table 4** lists the changes [4].

Based on the Mulliken classification, Waner and Suen, 1999, distinguished between malformations of venular origin on the basis of the size of the vessels involved, differentiating between small pink lesions (< 80 micras) and nodular, palpable violet-red lesions (> 150 micras) [5].

Vascular tumors
Infantile hemangioma
Vascular malformations
Slow-flow
Capillary
Lymphatic
Venous
Fast-flow
Arterial malformation
Arterivenous fistulae
Arteriovenous malformation

TABLE 3 : Classification Mulliken & Glowaki, 1982.

Vascular tumors
Hemangiomas
Superficial (capillary hemangiomas)
Deep (cavernous)
Mixed
Other
Kaposiform hemangioendothelioma
Tufted angioma
Hemangiopericytoma
Spindle-cell hemangioendothelioma
Glomangioma
Kaposi's sarcoma
Angiosarcoma
Vascular malformations
Simple
Capillary (C)
Venous (V)
Lymphatic (L)
Arterial (A)
Combined
Arteriovenous fistula (AVF)
Arteriovenous malformation (AVM)
CLVM (Klippel-Trenaunay)
CVM, LVM, CAVM, CLAVM

TABLE 4 : Mulliken and Young Classification adopted by the ISSVA, 1996.

Other authors, such as Frieden, have focused their studies on the analysis and sub-classification of specific lesions.

After analyzing over 400 hemangiomas, Frieden categorizes them according to their morphology and location, observing that 72% of his series occupy one or two regions, appearing in the form of well-delimited plaques or nodules, considered localized hemangiomas.

Aucun article ou résumé dans cette revue ne peut être reproduit sous forme d'imprimé, photocopie, microfilm ou par tout autre procédé sans l'autorisation expresse des auteurs et de l'éditeur. Editions Phlébologiques Françaises
No article or abstract in this journal may be reproduced in the form of print, photocopy, microfilm or any other means without the express permission of authors and the editor. Editions Phlébologiques Françaises

Segmental hemangiomas (18%) are generally characterized by appearing in specific sites. Finally, undetermined (8%) and multifocal (3%) hemangiomas do not normally follow a defined pattern [6].

In his review, Redondo also includes other sub-classifications with a more practical approach.

Puig et al. use hemodynamic characteristics and site as the basis for classification to help choose a therapeutic strategy [7].

Finally, Shobinger [8] sub-divides these lesions into four types according to their clinical-developmental stage, distinguishing between:

1) quiescent lesion: stable, duplex-detectable and with artério-venous shunt;

2) expansive lesion: with tortuous pulsating vessels;

3) destructive lesion: inclusion of cutaneous changes, ulceration, bleeding and/or pain;

4) decompensated lesion: destabilization of cardiac hemodynamics.

Heterogeneity of diagnostic criteria and divergence in nomenclature is a constant among professionals who do not work closely with this pathology. The same lesion can have different diagnoses depending on the origin or specialty of the observer.

The updated Mulliken classification very clearly distinguishes between different malformations according to the biological component and it makes an initial, major distinction between vascular tumor and vascular malformation.

The aim of the proposal described here is not to replace any of the existing classifications but to try to provide a new approach to the problem. It is important to attempt a simplification and offer new, more practical formulae or algorithms aimed at clarifying vital aspects such as the prognosis, follow-up and conduct for these patients.

A practical approach: LADS

On the basis of the different classifications described above, a global approach is suggested which aims at linking diagnostic, clinical and prognostic aspects so that the clinician may rapidly assess the patient's situation.

The acronym LADS summarizes the four fundamental aspects required to choose a treatment or attitude.

Life-threatening situations

Regardless of the origin of the lesion, there are certain situations that pose a threat to life due to possible complications arising from growth, progression or systemic disorders that may result.

The main causes of death are divided into:

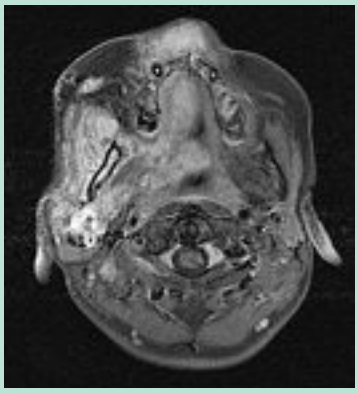

FIGURE 1 :
MRA. Right face malformation that affects cheek muscle and deep structures with lower jaw infiltration.

FIGURE 2 :
MRA. Limpho-venous tumor with oral structures infiltration.

Airway compromise

All lesions located in areas near the airways are potentially fatal, given the possibility that their progression can lead to occlusion of the airway and cause growth through the vascular-nervous structures.

The most frequent site for these lesions is the trachea, oral cavity, neck and occasionally the mediastinum.

Most of these lesions are usually venous and veno-lymphatic malformations. Their diagnosis requires imaging studies such as angio MRI (arterial or venous phases) with the aim of studying the lesion ratios and extent. Their treatment requires a multidisciplinary approach **(Figure 1, Figure 2)**.

These lesions should be distinguished from hemangiomas of the airways. Such hemangiomas are usually focal and most of them are located in the subglotic area. Their severity depends on their focality or extent and their treatment can be combined, with laser resection being the most frequently used treatment on well-delimited lesions [9].

Aucun article ou résumé dans cette revue ne peut être reproduit sous forme d'imprimé, photocopie, microfilm ou par tout autre procédé sans l'autorisation expresse des auteurs et de l'éditeur. Editions Phlébologiques Françaises
No article or abstract in this journal may be reproduced in the form of print, photocopy, microfilm or any other means without the express permission of authors and the editor. Editions Phlébologiques Françaises

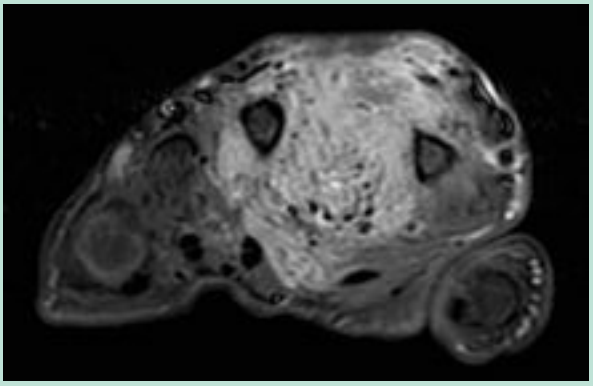

FIGURE 3 : MRA. Arterio-venous malformation in hand with muscle hyperthrophy.

FIGURE 4 : Duplex image of a limphangioma in mediastinum. Axial section through sternum.

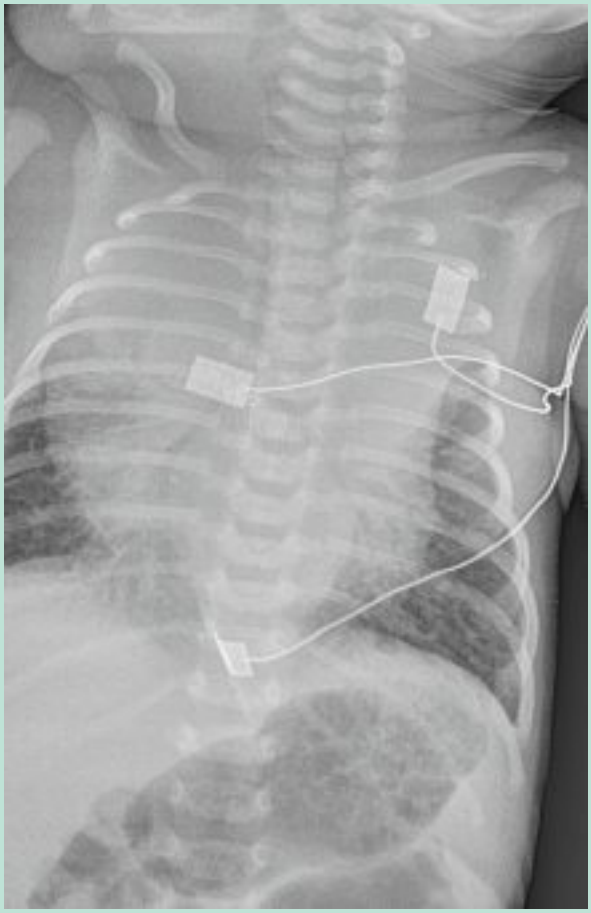

FIGURE 5 : Thorax X-Ray study showing a mediastinum mass which provoke respiratory distress in newborn.

Haemostatic complications

There are lesions which, due to their complexity and composition, can cause bleeding complications. Among the group of vascular tumors or hemangiomas, those that cover large areas or which are formed of neoplastic cells, such as Kaposiform hemangioma, can cause the phenomenon of platelet entrapment or the Kasabach-Meritt phenomenon **(Figure 3**, **Figure 4)**.

In the vascular malformation group, combined syndromes such as the low-flow Klippel-Trenaunay or Parkes-Weber (high flow) syndromes can lead to potentially lethal thrombotic complications.

Neuro ocular / orbital lesions

This group of lesions is characterized by an insidious clinical course and difficult diagnosis.

Lesions located in the cranial cavity and in the orbital zone can grow asymptomatically and invisibly to simple examination.

Their most frequent manifestation is amblyopia and occasionally vascular tumors go unnoticed until there is clear exophthalmos.

Diagnosis by CT scan is often useful.

Combined treatment using local or systemic intralesional corticosteroids and surgery are required to cure these tumors.

Other malformations such as artério-venous cranial fistulae or familial cavernous angiomas require percutaneous endovascular treatments.

The lesions known as cerebral venous malformations have a familial character with an autosomal dominant hereditary pattern and can produce hyperkeratotic skin lesions and also further ocular lesions.

Hemodynamic

High-flow vascular malformations, such as Parkes-Weber syndrome, consisting of an artério-venous anomaly can cause progressive deterioration in heart function due to chronic hemodynamic overload **(Figure 5)**.

Aucun article ou résumé dans cette revue ne peut être reproduit sous forme d'imprimé, photocopie, microfilm ou par tout autre procédé sans l'autorisation expresse des auteurs et de l'éditeur. Editions Phlébologiques Françaises
No article or abstract in this journal may be reproduced in the form of print, photocopy, microfilm or any other means without the express permission of authors and the editor. Editions Phlébologiques Françaises

Associations/ syndromes

When a diagnosis of vascular tumor or malformation is suspected, it is advisable to be aware of a number of associated syndromes or group of diseases that can occur. Identification of these syndromes can favor early diagnosis and thus immediate treatment.

Neurological

Neurological effects are frequently associated with venular-type vascular malformations, such as ***Sturge-Weber angiomatosis*** (encephalotrigeminal angiomatosis):

Facial venular malformation associated with a leptomeningeal vascular malformation and ocular alterations. The port-wine stain is generally unilateral and can be associated with gingival and even hemifacial hypertrophy.

Cobb Syndrome (cutaneo-meningeal angiomatosis): symptoms are a venular malformation on the trunk or proximal part of the extremities. It is often associated with progressive paraplegia or paraparesis as it affects the spinal cord below the lesion. It is important to be aware of the associated risk, as occasionally surgical treatment may be available.

Phakomatosis pigmento-vascularis is a combination of nevus vascularis and melanocytes which is occasionally associated with ophthalmologic, central nervous system or musculoskeletal lesions.

Segmental lumbosacral hemangiomas

These are hemangiomas frequently associated with spinal or genitourinary lesions. In such cases, there is occasionally a sign close to the lumbar area.

PHACE syndrome is the acronym for the association of posterior fossa malformations, hemangiomas, arterial anomalies, coarctation of the aorta and cardiac defects and eye anomalies.

Orthopedic lesions

Another type of secondary effect of the progression and growth of predominantly lymphatic vascular malformation is osteolysis of the long bones.

The Gorham-Stout Syndrome or disappearing bone disease is characterized by the appearance of lymphatic and venous malformations in the skin, mediastinum and bone. It produces osteolysis and secondary fibrosis, which can cause whole bones to disappear.

Maffucci Syndrome is a mesenchymal dysplasia associated with venous and capillary malformations with exostosis and enchondromatosis. These bone lesions can become malignant in the form of chondrosarcomas and fragile deformities which can easily fracture.

Diagnostic algorithm

As with any medical specialty, correct diagnosis of a pathology is based on applying a correct anamnesis, physical examination and information from the requested complementary examinations.

The fact that most infantile vascular lesions are vascular tumors or hemangiomas diagnosed correctly through physical examination alone does not exclude the fact that occasionally it is necessary to consider more complex examinations to assess the complications or extent of the lesion.

The table below gives a summary of the diagnostic algorithm.

Vascular tumors in infancy	→	Clinical examination/ Comments
If	Signs of growth/ association suspected	Angio-MRI
If	Atypical growth	Biopsy

Usually, the lesions that appear in infancy are self-limiting or involutional hemangiomas.

Other types of vascular tumors, such as non-involutional tumors, require follow-up and combined treatment [10].

The study of vascular malformations frequently requires a number of functionally useful examinations. As well as a complete, meticulous physical examination, it is extremely helpful to apply a duplex study.

A Doppler ultrasound study can immediately and non-invasively provide a rapid image of the scope, extent and hemodynamic component of the malformation. Therefore, the complete study of a vascular malformation requires, when technically possible, a hemodynamic examination by Doppler ultrasound.

The extent of the malformation can be studied by CT scan or even MRI, the latter being particularly useful due to the possibility of performing an angiographic reconstruction. For some malformations, selective angiographic study by direct arterial puncture enables the diagnostic process to be used to treat these lesions endovascularly. Currently, although diagnosis aims to avoid invasive examinations, the nature of these types of lesions and their low incidence favors excessive prescription of diagnostic tests.

Other examinations such as conventional X-ray or phlebography can provide complementary information, although this is not usually definitive for defining the strategy to follow.

Aucun article ou résumé dans cette revue ne peut être reproduit sous forme d'imprimé, photocopie, microfilm ou par tout autre procédé sans l'autorisation expresse des auteurs et de l'éditeur. Editions Phlébologiques Françaises
No article or abstract in this journal may be reproduced in the form of print, photocopy, microfilm or any other means without the express permission of authors and the editor. Editions Phlébologiques Françaises

	Tumors / hemangiomas ++++	Vascular malformations –	Comment
Pharmacological treatment			
Oral-local corticosteroids	++++	±	
Interferon, cytostatics			
Propanololi B-bloquers			
Laser	+++	++	Nd-Yag,
Diode		Capillary, venular M.	
Surgery	++	++	
Sclerotherapy	+	++++ Venous, lymphatic, combined	
Percutaneous embolization		± Visceral hemangiomas (hepatic)	++++ High-flow, combined AFM

TABLE 5

Strategy

Therapeutic possibilities for these patients are highly varied. Some lesions do not require any kind of treatment while others may require all possible medical and surgical combinations.

Based on the major distinction between vascular tumors and vascular malformations, the currently accepted strategic trends are given below **(Table 5)**.

The most frequent lesions are those that do not require treatment but which, given the high variability in manifestations, end up being treated using various procedures.

Hemangiomas, which are normally involutional, may require treatment if the aim is to prevent their retraction leaving unsightly marks.

In this context, the use of both systemic and local adjuvant anti-inflammatory treatment may be useful.

Vascular tumors in the form of red capillary plaques that do not spontaneously disappear may benefit from percutaneous laser treatment. And in the case of large neoformations, surgery may offer guarantees of success.

Among this group of patients, sclerotherapy and embolization are not usually indicated. Only a few hepatic tumors may benefit from percutaneous embolization.

Vascular malformations, which are much more heterogenous and have a worse prognosis, benefit increasingly from percutaneous endovascular procedures and the injection of sclerosing products.

FIGURE 6 : Combined low flow malformation in leg suitable for foam sclerotherapy.

Microfoam sclerotherapy, described by Juan Cabrera has been a significant advance in recent years due to the less invasive treatment comparing with open surgery [11].

The results reported with low-flow venous, lympho-venous and combined malformations probably demonstrate the superiority of this treatment over any other procedure in this type of lesions **(Figure 6, Figure 7)**.

Among high-flow malformations, the primary indication for artério-venous fistulae is treatment by selective catheterization and occlusion with coils, adhesives or other particles [12].

Aucun article ou résumé dans cette revue ne peut être reproduit sous forme d'imprimé, photocopie, microfilm ou par tout autre procédé sans l'autorisation expresse des auteurs et de l'éditeur. Editions Phlébologiques Françaises
No article or abstract in this journal may be reproduced in the form of print, photocopy, microfilm or any other means without the express permission of authors and the editor. Editions Phlébologiques Françaises

FIGURE 7 : Low flow malformation in tongue suitable for foam sclerotherapy.

Conclusion

A good classification not only allows correct diagnosis but also provides the specialist with a global view in order to plan disease management. Despite the fact that most cases are not severe, this kind of patient sometimes needs complementary examinations with a long follow-up and, in certain cases, an invasive procedure.

Due to the difficulty in managing these patients a new approach to the classification is proposed, emphasising four clinical aspects to consider with regard to vascular lesion - summarised in the acronym LADS.

Even though this is not exactly a classification, this acronym aims at facilitating a quick review of the main aspects of the vascular anomalies and their management.

The review of this complex pathology demonstrates the need to work in multidisciplinary teams with experience in treating these patients. This reason alone justifies the promotion of reference centres where accumulative experience can offer the patient the most appropriate treatment.

References

1. Redondo P. An. Sist. Sanit. Navar. 2004 ; 27(Supl) : 9-25.
2. Redondo P. Actas Dermosifiliogr. 2007 ; 98 : 219-35.
3. Mulliken J.B., Glowacki J. Plastic & Reconstructive Surgery 1982 ; 69(3) : 421-2.
4. Mulliken J.B. Vascular malformations of the head and neck. In: Mulliken J.B., Young A.E., Eds. Vascular birthmarks: Hemangiomas and vascular malformations. Philadelphia: WB Saunders, 1988.
5. Waner M., Suen J.Y., Eds. Hemangiomas and vascular malformations of the head and neck. New York: Wiley-Liss, 1999.
6. Chiller K.G., Passaro D., Frieden I.J. Hemangiomas of infancy. Clinical characteristics, morphologic subtypes, and their relationship to race, ethnicity and sex. Arch. Dermatol. 2002 ; 138 : 1567-76.
7. Puig S., Aref H., Chigot V., Bonin B., Brunelle F. Classification of venous malformations in children and implications for sclerotherapy. Pediatr. Radiol. 2003 ; 33 : 99-103.
8. Shobinger R.A. Guidelines to the classification of congenital vascular malformations. Phlébologie 89. J. Libbey Eurotext 1989 : 208-20.
9. Frieden I.J., et al. Infantile Hemangiomas: Current Knowledge, future directions. Proceedings of a research workshop on Infantile Hemangiomas. Pediatric Dermatology 2005 ; 22(5) : 383-406.
10. Current concepts in the classification, diagnosis and treatment of hemangiomas and vascular malformations of the head and neck. Eur. Arch. Otorhinolaryngol. 2001 ; 258 : 141-9.
11. Cabrera J., Cabrera J. Jr, Garcia-Olmedo M.A., Redondo P. Treatment of venous malformations with sclerosant in microfoam form. Arch. Dermatol. 2003 ; 139 : 1409-16.
12. Léauté-Labrèze C., Dumas de la Roque E., Hubiche T., Boralevi F., Thambo J.B., Taïeb A. Propanolol for severe hemangiomas of infancy. N. Engl. J. Med. 2008 ; 358 : 2649-51.