Aucun article ou résumé dans cette revue ne peut être reproduit sous forme d'imprimé, photocopie, microfilm ou par tout autre procédé sans l'autorisation expresse des auteurs et de l'éditeur. Editions Phlébologiques Françaises
No article or abstract in this journal may be reproduced in the form of print, photocopy, microfilm or any other means without the express permission of authors and the editor. Editions Phlébologiques Françaises

Nerve Injury Associated with Sclerotherapy.

Lésions iatrogènes des nerfs périphériques après sclérothérapie.

Hill D.

Summary

Nerve injury associated with sclerotherapy is a rare event.

Two cases involving sensory nerve injury in the calf are described.

The first case followed ultrasound guided foam sclerotherapy of a popliteal fossa perforating vein.

The second was related to drainage of an intravascular hematoma in the popliteal fossa.

The sensory nerves that may have been damaged and possible mechanisms of injury are discussed.

Keywords : *nerve injury, sclerotherapy.*

Résumé

La survenue d'une lésion nerveuse en lien avec une sclérothérapie est un événement rare.

Deux cas de lésion de nerfs sensitifs du mollet sont décrits.

Le premier cas après sclérothérapie échoguidée à la mousse d'une veine perforante de la fosse poplitée.

Le deuxième après drainage d'un hématome intravasculaire de la fosse poplitée.

Les mécanismes possibles de ces lésions sont étudiés.

Mots-clés : lésion de nerfs, sclérothérapie.

Introduction

Nerve injury related to sclerotherapy is an unusual occurrence. It is often listed as a potential complication of sclerotherapy but rarely elaborated on or reported [1, 2]. Two cases of nerve injury associated with sclerotherapy are presented.

Case 1

T.M. was a 43 year old homemaker who presented with extensive lower limb varicosities and a history of varicose vein surgery 10 years previously.

She subsequently received several sessions of ultrasound guided foam sclerotherapy (UGFS) with good results. Her fourth UGFS session involved treatment of an incompetent lateral popliteal fossa perforator vein in the left leg.

The popliteal fossa perforator connected directly to a dilated superficial accessory small saphenous vein which extended distally in the posterolateral aspect of the calf.

The accessory small saphenous vein was cannulated with a 20 g. 2 inch angiocatheter at 12 cm distal to the popliteal crease as the vein was less tortuous at that point.

A small intradermal bleb of 1% xylocaine was raised on the skin prior to cannulation. After ensuring there was good return of venous blood, 2 mL of sodium tetradecyl sulphate (STS) 3% foam was slowly injected under duplex ultrasound visualization.

The foam was monitored with ultrasound as it moved proximally in the accessory small saphenous vein and into the popliteal fossa perforator.

When the foam reached the junction of the perforator and the popliteal vein, the injection was discontinued and probe pressure was applied for 3 minutes. The patient experienced no pain or paresthesia during or immediately following the injection. The treated vein was then bandaged with an overlying pad and a 30-40 mmHg thigh high support stocking was applied to be worn for the next 5 to 7 days.

At her next visit, 4 weeks post injection; the patient revealed that she had noticed a patch of decreased sensation in her lateral calf when she removed her support stocking 5 days after treatment. There was no pain or paresthesia.

Douglas Hill, MD, FACPh, The Vein Treatment Centre, #207, 2004 - 14 St. N.W., Calgary, Alberta T2M 3N3, Canada.
E-mail : vtcentre@telus.net
Accepté le 1er avril 2010

Aucun article ou résumé dans cette revue ne peut être reproduit sous forme d'imprimé, photocopie, microfilm ou par tout autre procédé sans l'autorisation expresse des auteurs et de l'éditeur. Editions Phlébologiques Françaises
No article or abstract in this journal may be reproduced in the form of print, photocopy, microfilm or any other means without the express permission of authors and the editor. Editions Phlébologiques Françaises

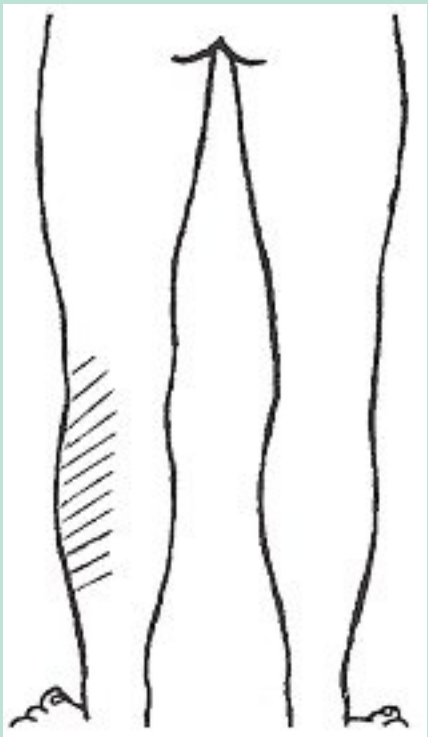

FIGURE 1

On examination, she displayed a discreet area of sensory loss to pin prick and altered sensation to light touch in the proximal 2/3 of the calf distal to the popliteal fossa.

This area extended laterally from the posterior mid line of the calf to the outer aspect of the calf **(Figure 1)**.

The patch of decreased sensation was still present at her most recent examination 3 1/2 months after the injection but had decreased in area by about 50 percent.

Discussion

The clinical presentation is consistent with damage to the lateral cutaneous nerve of the calf as a result of the treatment **(Figure 2)** [3].

This nerve is also referred to as the lateral sural cutaneous nerve [4]. The lateral sural cutaneous nerve is a sensory branch of the common peroneal nerve **(Figure 3)**.

It is described as providing sensation for the skin and fascia on the lateral and adjacent parts of the posterior and anterior surfaces of the upper part of the leg [3].

It is very unlikely that the nerve was traumatised by the cannulation needle as the patient did not experience pain or paresthesia during venipuncture.

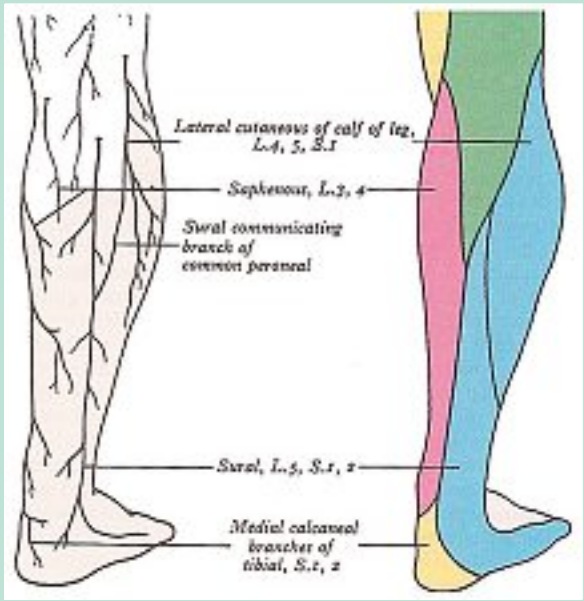

FIGURE 2

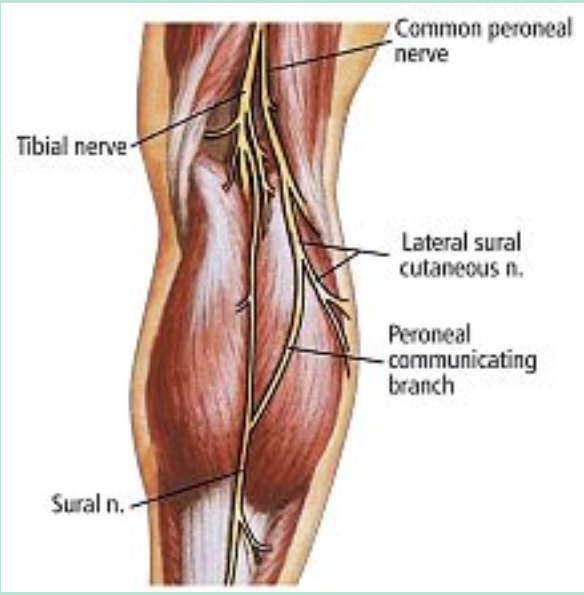

FIGURE 3

There was definitely no direct nerve injection as good venous return was evident from the inserted catheter, the injection was painless and foam could be seen flowing proximally within the vein. It is possible that the eccentric compression applied post injection may have resulted in compromise of the nerve fibres.

An alternative and more likely explanation is that the treated vein was in close approximation to the lateral sural cutaneous nerve and perivenous inflammation affected the nerve.

Aucun article ou résumé dans cette revue ne peut être reproduit sous forme d'imprimé, photocopie, microfilm ou par tout autre procédé sans l'autorisation expresse des auteurs et de l'éditeur. Editions Phlébologiques Françaises
No article or abstract in this journal may be reproduced in the form of print, photocopy, microfilm or any other means without the express permission of authors and the editor. Editions Phlébologiques Françaises

The nerve may have been sclerosed or its function may have been temporarily compromised with no structural changes occurring. If the nerve axons were structurally damaged, full return of sensation may not occur. However, if only axonal conduction was disrupted, sensation can be expected to recover in several months from the time of injury. This type of injury is termed a neurapraxia.

In retrospect, this complication might have been avoided if a lower concentration of STS foam had been used.

STS 3% was chosen because the patient had displayed a degree of sclero-resistance in previous treatments and because popliteal fossa perforators can be difficult to sclerose.

Case 2

In this case, a nerve injury was likely associated with drainage of an intravascular hematoma post sclerotherapy.

K.S. was a 44-year-old pharmacy technician who presented with mainly cosmetic concerns about small veins on her lower legs.

She underwent 3 sessions of sclerotherapy one month apart for treatment of dilated reticular veins and telangiectasia, mostly in her lateral thighs and popliteal area.

At the time of the 3rd session she was noted to have some small intravascular thrombi in previously treated reticular veins on the backs of her knees.

These small thrombi were released by venipuncture with the tip of an 18 g needle and subsequent gentle milking to express the clot.

In my clinic, a tiny skin bleb of the local anaesthetic is generally instilled over the hematoma prior to puncture.

Drainage of these intravascular hematomas is often performed by one of my nursing staff or specially trained medical assistants.

One month later the patient attended a 4th sclerotherapy session but complained of an area of decreased sensation in the right posterior lateral calf.

She recounted experiencing a sharp burning pain from the knee to the ankle with a needle puncture behind her knee during the previous treatment session.

She continued to have pain and paresthesia in the posterior calf for the next 10 days or so.

The patient was left with an area of loss of sensation in the mid posterior and distal lateral calf which persisted over the next 6 months.

At 18 months following the incident, the patient described moderate improvement but still noted loss of sensation in the posterolateral ankle and slight deficit in the distal lateral calf.

She had no complaints of pain or paresthesia.

Discussion

It is probable that during venipuncture to release a hematoma, the 18 g needle was inserted too deeply and transected a nerve.

The 27 g and 30 g needles we use for sclerotherapy are likely too small to cause an injury such as this.

Transection of a nerve results in axonotmesis if only the axon and myelin sheath is disrupted but surrounding connective tissue is preserved.

This leads to degeneration of the distal axon fibers but subsequent slow spontaneous regeneration and good recovery of function as the axons proximal to the site of injury regrow along the nerve sheath. If the connective tissue surrounding the nerve is also destroyed then no recovery occurs. This permanent injury is termed neurotmesis.

The nerve injury in this case may have been to some of the fibers of the sural nerve in the distal popliteal fossa. The sural nerve supplies sensation to the skin of the lateral and posterior part of the lower one-third of the leg, which was the area of sensory loss in the patient **(Figure 2)**.

It is also possible that the damage occurred to axons of the sural communicating branch (called the peroneal communicating branch in some texts) of the lateral sural cutaneous nerve **(Figure 3)**.

The peroneal or sural communicating branch joins the sural nerve in the mid or upper part of the posterior calf [4, 3, 5].

This case illustrates the necessity of employing caution and meticulous technique in relatively simple procedures such as draining hematomas, particularly in areas where important structures may be close to the skin surface.

References

1. Brouse N.L. Diseases of the Veins. London : Arnold, 1999.
2. Goldman M.P. Sclerotherapy: Treatment of Varicose Veins and Telangiectatic Leg Veins. 2nd ed. St. Louis : 1995.
3. Gray's Anatomy. 36th ed. eds. Williams, PL and Warwick, R. Edinburgh: Churchill Livingstone, 1980.
4. Netter F.H. The Ciba Collection of Medical Illustrations. Volume 1, Nervous System, Part I, Anatomy and Physiology. Eds. Brass, A and Dingle, RV. West Caldwell, New Jersey, 1983.
5. Clemente C.D. Anatomy. 3rd Ed. Baltimore: Urban and Schwarzenberg, 1987.

Aucun article ou résumé dans cette revue ne peut être reproduit sous forme d'imprimé, photocopie, microfilm ou par tout autre procédé sans l'autorisation expresse des auteurs et de l'éditeur. Editions Phlébologiques Françaises
No article or abstract in this journal may be reproduced in the form of print, photocopy, microfilm or any other means without the express permission of authors and the editor. Editions Phlébologiques Françaises

SOCIÉTÉ FRANÇAISE DE PHLÉBOLOGIE

Subscribe

to Phlébologie
ANNALES VASCULAIRES

The International Journal of Phlebology

Official journal
of the SFP and the CSP/SCP



A scientific publication and a journal for pratical continuing medical education from the best international authors

A joint publication of the SFP and the CSP/SCP

News from drug and medical compression industries

Access the journal online at
www.revue-phlebologie.org