



Treatment of incompetent perforating veins with percutaneous laser under Doppler US control.

Traitement au laser par voie percutanée des veines perforantes incontinentes sous contrôle écho-Doppler.

Pietravallo A., Pietravallo E.

Summary

The participation of insufficient perforating veins in the phlebological clinic determining with their reflux secondary varicose veins besides their participation in the pathogeny of varicose recurrences and in certain clinical forms of the venous ulcer, is being indicated increasingly in the international bibliography.

- Echo-Doppler shows us with major efficiency, like insufficient perforating veins produce secondary varicose veins to their reflux.
- Both open surgery like subaponeurotic videoscropy (SEPS) show us daily as insufficient perforating veins produce secondary varicose veins and intervene in the pathogeny of trophic disorders and in the varicose recurrences.
- Opposite to this scientific evidence increasingly sustained by the experience, in numerous authors of different latitudes have appeared the conviction of closing to the insufficient perforating veins with minimally invasive methods under echo-Doppler guide.
- There are numerous the authors of the international bibliography who treat insufficient perforating veins with percutaneous laser or with sclerotherapy or with radiofrequency under echo-Doppler guide.

In this work we show our experience with percutaneous laser under echo-Doppler guide.

- As original contribution at this topic we show in 20 cases in which with scientific investigation criteria we observed by SEPS the enter of the needle carrying the fiber laser to the interior of the perforating.
- We have observed with the laser fluence that to close the perforating vein is sufficient a power of 4 watts in 3 series of 3 seconds each one, it means, a fluence of 36 joules to achieve an effective closure without side effects.

Résumé

L'insuffisance des veines perforantes, identifiée en phlébologie clinique lors d'un diagnostic de reflux veineux au niveau de la jonction saphéno-fémorale, contribue à la récidence variqueuse ainsi qu'à la formation de certaines manifestations d'ulcères veineux, comme il l'est indiqué de plus en plus dans les ouvrages internationaux.

- *L'écho-Doppler est une méthode fiable pour dépister une insuffisance des veines perforantes susceptible de provoquer des varices secondaires causées par un reflux veineux.*
- *La chirurgie à ciel ouvert, comme la vidéo-endoscopie sous-fasciale (ou CEPS), révèle très souvent une insuffisance des veines perforantes provoquant un reflux au niveau de la jonction saphéno-fémorale, entraînant des troubles trophiques et des varices récurrentes.*
- *Malgré ces preuves scientifiques, confirmées de plus en plus par la pratique, de nombreux auteurs du monde entier soutiennent que l'occlusion des veines perforantes insuffisantes à l'aide de méthodes peu invasives sous contrôle écho-Doppler sont efficaces.*
- *Un grand nombre d'auteurs d'articles ont traité cette insuffisance veineuse au moyen du laser par voie percutanée, de la sclérothérapie ou de la radiofréquence sous contrôle écho-Doppler.*

Nous expliquons dans cet article notre utilisation d'un traitement au laser par voie percutanée sous contrôle écho-Doppler.

- *Nous apportons notre contribution à ce sujet, tout en respectant les critères de l'enquête scientifique, en décrivant 20 cas au cours desquels nous avons fait des observations grâce à la vidéo-endoscopie suite à l'insertion d'une aiguille reliée à un laser à fibre optique introduite dans l'incision.*
- *Nous avons découvert que l'efficacité du traitement au laser, relatif à la sclérose de la veine perforante, résultait de 3 tirs à puissance de 4 watts de 3 secondes chacun. Cette circulation de 36 joules produit une sclérose décisive dépourvue d'effets secondaires.*

E-mail: flebologiapietravallo@hotmail.com

Submitted for publication on January 5th, 2013.

Accepted on March 28th, 2013

– According to the cases and according to the size of the perforating veins between 36 and 60 joules is the power adapted to achieve efficiency without side effects.

Keywords: *percutaneous laser, joules, insufficient perforating veins, reentry perforating veins.*

– *Selon les cas et la taille des veines perforantes, 36 à 60 joules devraient suffire pour assurer une efficacité sans provoquer d'effets secondaires.*

Mots-clés : *laser par voie percutanée, joules, insuffisance veineuse, introduction dans les veines perforantes.*

Introduction

Treatment of insufficient perforating veins with percutaneous laser under Doppler US control is considered by us a significant technical welfare progress in the chapter corresponding to the therapeutic directed to the insufficient perforating veins.

We have no hesitation in saying that if insufficient perforating veins and their secondary varicose veins to their reflux are not treated effectively is high the rate of recurrence and persistence varicose.

This is demonstrated by one of the significant work by the authors' experience **Nicos Labropoulos** and **Michel Perrin** who affirm that insufficient perforators are among the three leading causes of varicose recurrences [1].

This is demonstrated also by the Book of the Argentinean writer **Jorge Pozzi**[2] which sets eleven papers of international authors that show the presence of insufficient perforating, in different percentages, in the etiology of recurrent varicose.

In the role of insufficient perforating veins generating hemodynamic alterations in venous return, although many studies about it, we consider the **Ashar Wadoodi** and **Kevin Burnand**, authors of Chapter 5 of Handbook of Venous Disorders edited by Peter Gloviczki [3], as one of the most current and significant.

In this work the authors demonstrate with their investigation the following thing:

1. When there aren't insufficient perforating veins functional recovery post muscle contraction is between 50 and 80%.
2. However when there are insufficient perforating veins venous functional recovery post muscular contraction is between 10 and 20%.

This demonstration had already been pointed out earlier by **A. Nicolaides** and **D. Sumner** [4].

In our book [5], we collect various arguments that demonstrate the importance of insufficient perforators.

One of the eloquent arguments that shows how the insufficient perforating vein generates secondary varicose veins is that we observed with the operation of Sherman, open surgery that is now replaced with the technique described below (**Figure 1**, **Figure 2**, **Figure 3** et **Figure 4**).

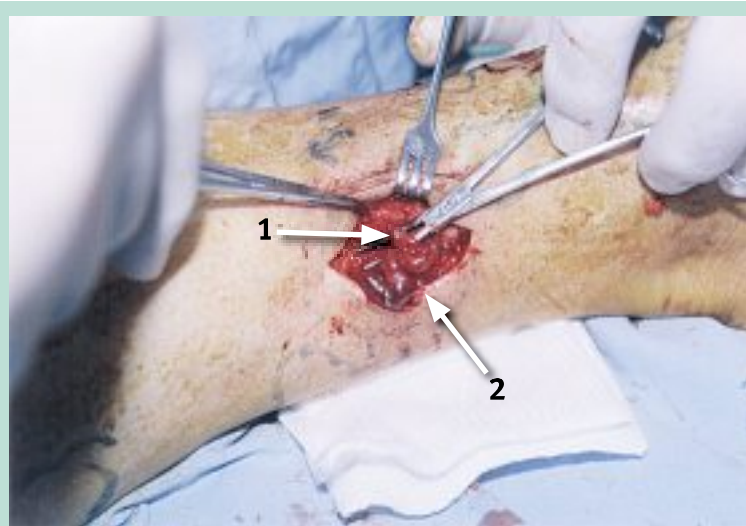


FIGURE 1 : *Surgical photo that shows the insufficient perforating vein and the secondary varicose vein.*

1. *Insufficient perforating vein.*
2. *Secondary varicose vein to the reflux of insufficient perforating.*

Treatment of incompetent perforating veins with percutaneous laser under Doppler US control.

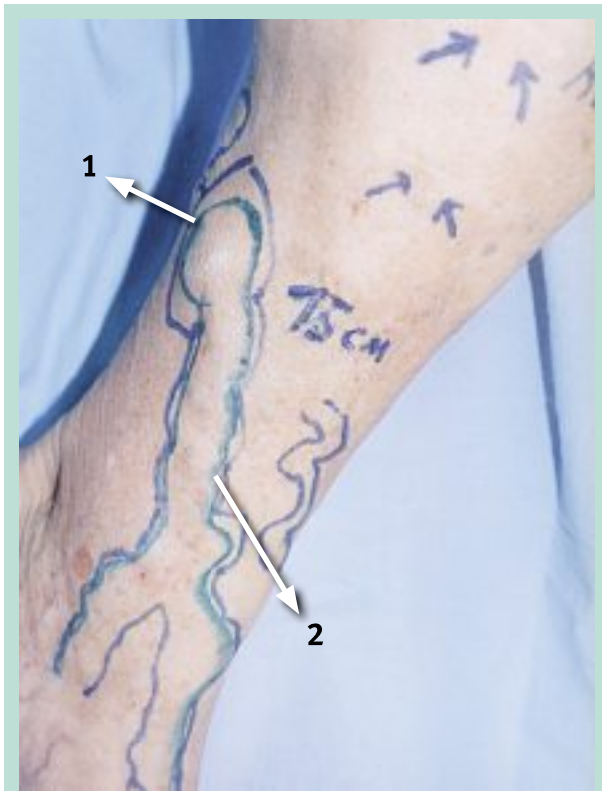

FIGURE 2 : Varicose vein secondary to the insufficient.
1. Varicose gulf secondary to insufficient perforating vein.
2. Varicose vein secondary to the insufficient perforating vein.

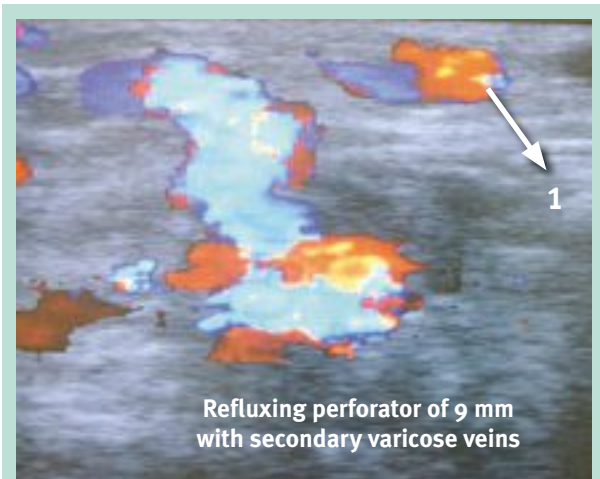


FIGURE 3 : Echo-Doppler photo that shows the reflux in the secondary varicose vein.
1. Varicose vein secondary to the reflux of insufficient perforating vein

Insufficient Perforating Veins

- 1- With the maneuver of the calf compression appears bidirectional flow turning from blue to red (Carls Dalotte)
- 2- In the spectral Doppler curve passage below abscissa to the upper part to a stimulus in the calf compression (Jorge Segura)
- 3- Diameter: 4 mm. or more (Raúl Lacour – Antonio Pietravallo)
International consensus meeting, October 15th to 17th 2009, University of Buenos Aires
* 3.5mm. or more: Nicol Labrepoulos
- 4- Reflux duration: more of 1 second
- 5- Reflux registrable in successive Doppler examinations (Joaquín Simón)
- 6- These that produce secondary pathology:
A- varicose veins secondary to their reflux
B- trophic disorders _____ Dr. Antonio Pietravallo

FIGURE 4 : Which are the insufficient perforating veins that we treat with percutaneous laser?

Arguments made us decided to make percutaneous surgery of insufficient perforating veins for a surgeon of 4 decades making open surgery (Figure 5).

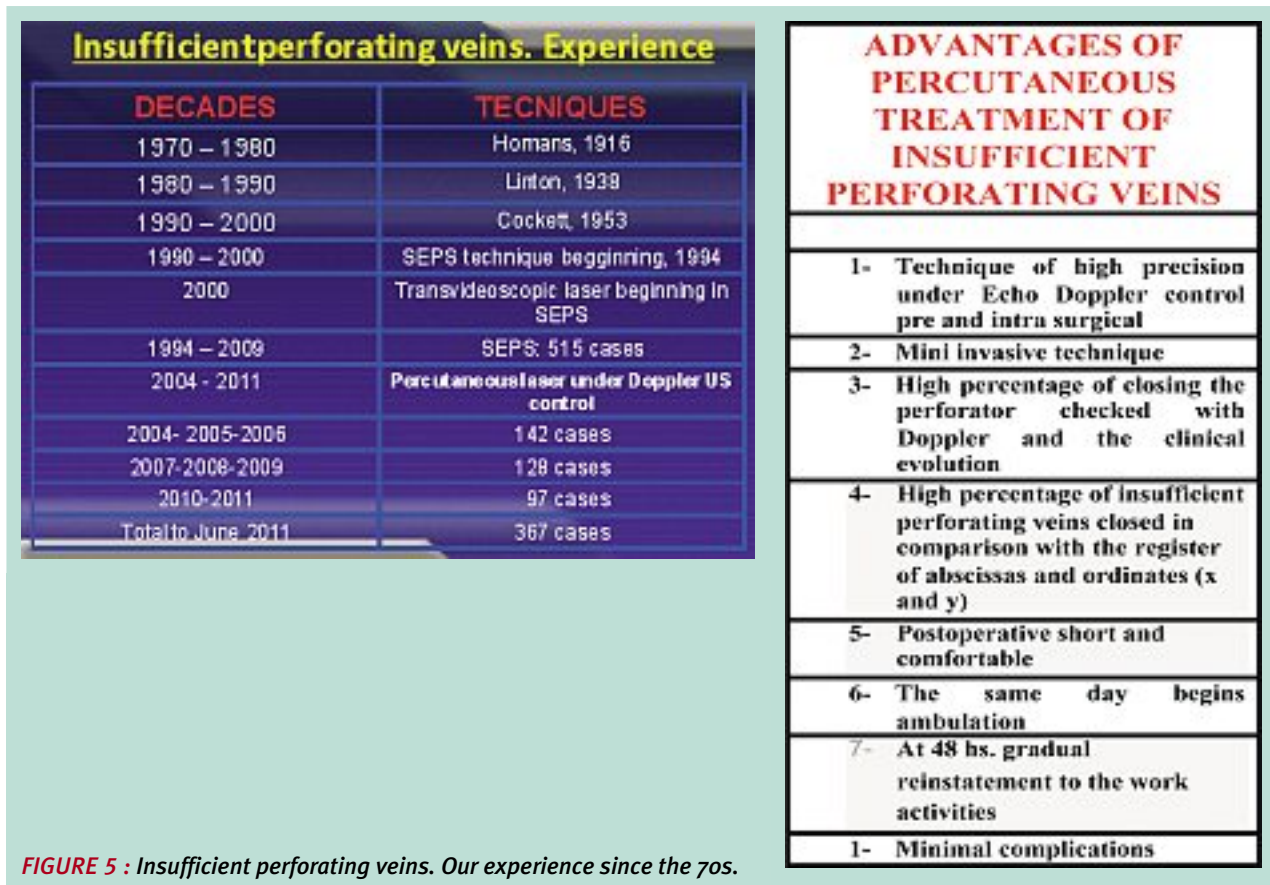


FIGURE 5 : Insufficient perforating veins. Our experience since the 70s.

Background

The first publications of this technique in our country were made by two working groups who encouraged our attention and interest to begin us developing this technique from the year 2004.

These scientific works are next:

1. Jorge Soracco, Jorge López D'Ambola. Published in 2000 in Magazine Phlebology, Official Publication of Argentine Society of Phlebology and Lymphology and International Union of Phlebology (UIP) [6, 7].
2. Oscar Bottini, Oscar Gural. Beginning of the method in 2004. Published in Argentina Magazine Forum of Phlebology and Lymphology, May 2006 [8].

We believe that this technique provides significant benefits and is very auspicious in their results. It's a technique that we are performing more and more frequently in our team of work in Medical Centers in which we develop now an intensive clinical and surgical activity.

We start to perform the first cases in 2004 and since then because of the effectiveness obtained we have developed this technique systematically to date and we'll continue to perform it because it is our technique of choice.

Indications

We perform this technique only in insufficient perforating veins that with their reflux produce secondary varicose veins or trophic disorders.

Method

We use a 980 nm laser, fiber laser of 400 o 600 microns. To fiber of 400 microns we make the puncture with needle 18G x 1 1/2" and to fiber of 600 microns we use Abbocath 14G.

1. The patient must be studied with a precise topography of insufficient perforating veins pointing with abscissas and ordinates the exact location of the aponeurotic emergency (ostium aponeurotic) of the perforating vein that will be treated (method described by Drs. Antonio Pietravallo and Angel Guzmán: "Determination of insufficient perforating veins by topographical coordinates", work first presented in 2004 at the Scientific Sessions of the Argentine Society of Phlebology and Lymphology).
2. Day before surgery we mark again with echo-Doppler putting a sticker circle colored of paper on the exact point where the perforating vein through the aponeurotic ostium.

Treatment of incompetent perforating veins with percutaneous laser under Doppler US control.

3. In surgery we locate again with precision the insufficient perforating vein in the supine patient with slight knee flexion downward with leg in Trendelenburg invested in a 45° angle downwards. Indeed, look for the perforating vein with Doppler and its respective function respecting this angle is essential because many perforating veins decrease its flow and consequently its diameter lateral decubitus. For this reason days or weeks earlier we do the precise diagnosis with the patient standing, but we mark again in operating room with this angle.
4. In the intraoperative Doppler image confirms the insufficient perforating vein.
5. And we confirm how the needle finds the perforating vein under echo-Doppler control.
6. We lead the fiber laser through the lumen of the needle 18G \times 1 1/2" or Abbocath 14G that it is we use for puncture.
7. Once the needle is in the perforating vein the laser discharge shows us the image of the "bubble" in the light of the perforating vein.
8. Are downloads of 3" with power of 4 watts.
9. The Doppler image shows how the perforating vein is closed at that level.
10. Making pressure on the calf muscle is confirmed that the reflux is stopped in the closed perforating vein.

We should clarify that when insufficient perforating veins produce trophic disorders CEAP IV and V we prefer Phlebologic Subaponeurotic Videoscope (SEPS) that allows to treat insufficient perforating veins under trophic disorders very effectively. Thus we avoid percutaneous punctures because it is inappropriate perform them through trophic disorders for the nourishing defects that the skin has on them and that can cause skin lesions with difficulties in healing.

Control under videoscopic vision

To confirm the laser effect in a treated perforating vein in a group of 20 patients with scientific research objective we have observed in subaponeurotic space by videoscopic vision how the needle once it crosses the fascia it penetrates in the perforating vein under external ultrasound guidance.

Once laser discharge is located in the lumen of the perforating vein it shows:

1. It is observed in the subaponeurotic space the needle that is directed toward the insufficient perforating vein (**Figure 6**).
2. The laser light is observed as a white flash through the wall of the insufficient perforating vein being treated (**Figure 7**).
3. The new laser discharge darks the wall of the perforating vein which immediately begins to retract being completely closed (**Figure 8**).

This sequence that has been captured by videoscope is observed in the attached pictures in this paper.

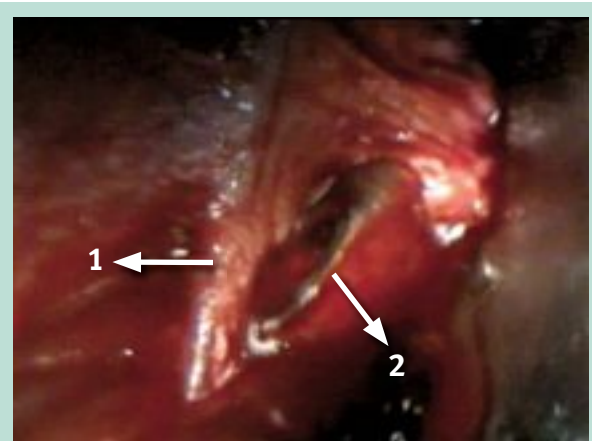


FIGURE 6 : 1. Perforating vein.
2. Needle that appears in the subaponeurotic space after crossing skin, subcutaneous cellular and aponeurosis under ultrasound guidance.

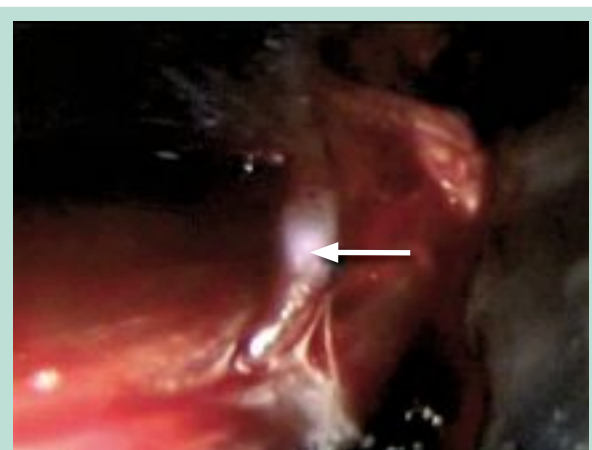


FIGURE 7 : Laser Effect Light limited to the wall of the perforating vein. No perivenous effect is observed.

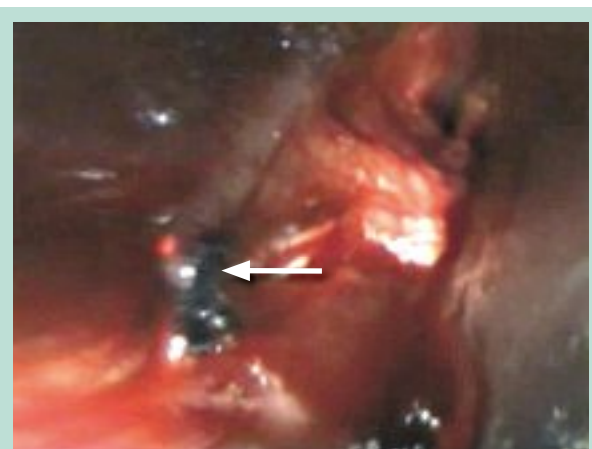

FIGURE 8 : Closed and retracted perforating vein.

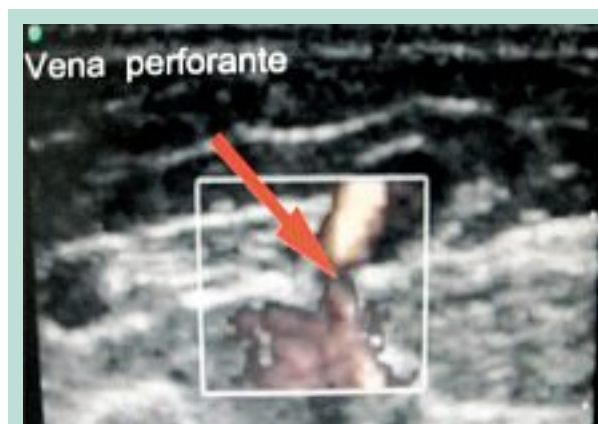


FIGURE 9 : Echo-Doppler control of the perforating vein starting the surgical procedure.

So we found that it's enough 3 downloads of 4 watts each one of 3 seconds, a total of 36 joules, to effectively close the perforating vein.

Until this research there was no absolute certainty:

1. The effect of laser in the light of the perforating vein.
2. As the closure of the perforating vein is achieved by gradual retraction until full closure.
3. With that fluence do not occur side perivenous effects.
4. No drilling occurs of wall of treated perforating vein while it is treated with adequate power.

The videoscope with Gerald Hauer device was used only in these 20 cases as research:

Currently we are making another research with laser 1470. This research will do in 10 cases to observe with wich fluence the perforating vein is closed and from which fluence starts perforations in the treated perforating veins. Videoscope research is of particular importance to learn from wich fluence can occur perforations in the wall of the perforating vein and this is important because if this happens, the procedure must be canceled because Doppler control becomes ineffective at to be canceled the field of ultrasound guidance to coming out blood from the perforator to the subaponeurotic space.

We have found in our research that begin to observe some perforations with laser 980 in the wall of the perforator from 90 joules of fluence offered to the treated perforating vein.

SEPS brought these research data, is a highly effective procedure according to data provided us with excellent insight provided by Gerald Hauer device.

SEPS produces no negative effect to the research itself, does not interfere at all on the endovenous laser procedure used to treat insufficient perforating veins.

It is just a method of checks made in rare cases with scientific research purposes, it is just a videoscopic visual contribution without any influence on the endovenous laser procedure in the perforator treated.

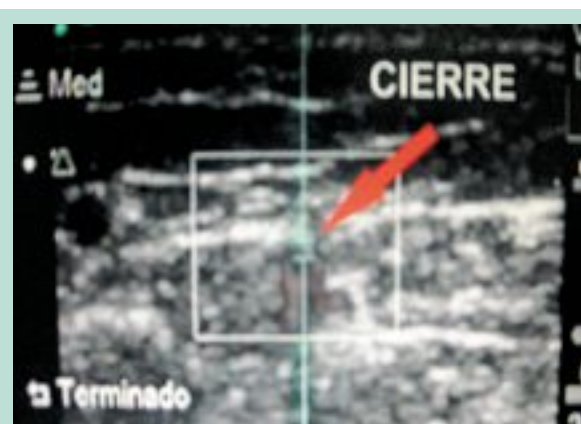


FIGURE 10 : Echo-Doppler control of the same case once finished the closure of the perforating vein with percutaneous laser.

Casuistry and results

While we are working on a follow-up to 5 years in patients who have completed this period of evolution, we present the results of three years in each group of patients in the three periods that compose our casuistry.

We believe that it is necessary for an accurate assessment of the results because in all series of other authors consulted confirmed that recurrences occur in the first 6 months post-treatment.

Assessments within the first three years with either sclerotherapy or laser in perforating veins were published by Bo Eklof, Steve Elias, Paul Thibault, Frédéric Vin, among other prestigious authors.

On basis on this we consider the high value of three years following-up because if recurrences occur is within that period, because once the perforating vein fibrosed by the laser effect it does not return to permeabilize again, in fact, we have observed no new recurrences beyond the first three years (**Table 1**).

	Operated	Evaluated	Recurrences
First series 2004-2005-2006	142	138	5 %
Second series 2007-2008-2009	128	115	4 %
Third series 2010 -2012	97	97	2 %

TABLE 1

Treatment of incompetent perforating veins with percutaneous laser under Doppler US control.

We clarify the difference between clinical and ultrasound recurrences. The first is when it is found reflux in the treated perforating vein and it generates new secondary varicose veins.

Ultrasound recurrence is when it is found a defile in the light of the treated perforating vein but this reflux doesn't have the gradient be able to develop secondary varicose veins or trophic disorders, consequently, does not require a new treatment of the perforating vein. In contrast, clinical recurrences need a new treatment of the treated perforating vein.

In our case it was ultrasound recurrence.

References

1. Perrin M.R., Labropoulos N., Leon L.R. Jr. Presentation of the patient with recurrent varices after surgery (REVAS). *J. Vasc. Surg.* 2006 Feb ; 43(2) : 327-34 ; discussion 334.
2. Pozzi J. Várices recidivadas. Diagnóstico, prevención, tratamiento. UNR Editora, Editorial de la Universidad Nacional de Rosario, República Argentina, Abril 2001.
3. Burnand K., Wadoodi A. The physiology and hemodynamics of chronic venous insufficiency of the lower limb. *Cáp 5 del Libro Handbook of Venous Disorders Third Edition, Guidelines of the American Venous Forum*, págs. 47-55. Editado por Peter Gloviczki, 2009.
4. Nicolaides A., Sumner D. Investigation of patients with deep vein thrombosis and chronic venous insufficiency. London: Med-Orion; 1991.
5. Pietravallo A. Venas perforantes. Clínica – Anatomía – Tratamiento. Videoscopía Flebológica Subaponeurótica. Editado en Talleres Gráficos Eglo S.A., 1999, Buenos Aires, Argentina.
6. Soracco J., López D'Ambola J. Fototermobliteración intravascular de venas varicosas de los miembros inferiores. Láser 532 nm y láser 810 nm. Primera comunicación. *Revista Flebología* 2000 ; 1 : 27-9. Órgano oficial de difusión de la Sociedad Argentina de Flebología y Linfología y de la Unión Internacional de Flebología.
7. Soracco J., López D'Ambola J., Ciucci J.L. Fototermobliteración venosa láser en la insuficiencia venosa superficial (FOTOV). *Revista Flebología* 2001 ; 1 : 11-4. Órgano oficial de difusión de la Sociedad Argentina de Flebología y Linfología y de la Unión Internacional de Flebología.
8. Gural Romero O., Bercovich J., Morales M., Bottini O., La Mura R. Esclerosis con laser ecoasistido de perforantes (ELEAP). *Revista Forum de Flebología y Linfología* 2006 ; 8 (1) : 5-9.
9. Pietravallo A., Guzmán A., Parrotta L., Pietravallo E. Traitement de perforantes insuffisantes avec le laser endoveineux sous contrôle écho-Doppler. Résultats du traitement de 142 perforantes, dont 20 sous contrôle vidéoscopique. *Phlébologie* 2010 ; 63 (4) : 31-9.
10. Pietravallo A., Segura J., Pietravallo E., Guzmán A., Guglielmo D. Treatment of perforating veins with percutaneous laser under Echo-Doppler control. *Int. Ang.* 2010 ; 29 (25 to issue 2) : 41-2. XXIV World Congress of the International Union of Angiology (IUA); 21-25 Abril, 2010. Buenos Aires, Argentina.
11. Pietravallo E. Tratamiento de perforantes insuficientes con laser percutáneo bajo control Eco Doppler Color. *Revista Flebología, Órgano oficial de la Sociedad Argentina de Flebología y Linfología* 2012 ; 1 : 14-22.
12. Kabnick L. Outcome of different endovenous laser wavelengths for great saphenous vein ablation. *J. Vasc. Surg.* 2006 ; 43 : 88-93. Outcomes in varicose veins treatment using longer wavelength endovenous laser ablation. *Int. Ang.* 2012 ; 29 (25 to issue2) : 57. XXIV World Congress of the International Union of Angiology (IUA); 21-25 Abril, 2010. Buenos Aires, Argentina.
13. Segura J. Echo-Doppler Color en Flebología. De la normalidad al intervencionismo. Editorial Medrano. Mayo de 2011. Buenos Aires, Argentina.
14. Simkin R., Simkin C. Laser en Flebología. Editorial Medrano. Mayo 2012. Buenos Aires, Argentina.
15. Patt J.C. Láser En Flebología y Dermatología Estética. Publicado en la Revista de la Sociedad de Flebología y Linfología Bonaerense (SFLB). *Lecturas Vasculares. Flebología y Linfología* 2010 ; 11: 656-64.
16. Patt J.C. Laser endoluminal. Como funciona? Como lo usamos? Que usamos? *Revista de Flebología de la Asociación de Flebología y Linfología de la Provincia de Buenos Aires (AFLIPBA)* 2012 ; 3 : 17-22.
17. Vellezz R., Norman C. Laser endoluminal percutáneo ecoguiado. *Flebología y Linfología, Lecturas Vasculares* 2006 ; 1 : 2 : 91-100.