Aucun article ou résumé dans cette revue ne peut être reproduit sous forme d'imprimé, photocopie, microfilm ou par tout autre procédé sans l'autorisation expresse des auteurs et de l'éditeur. Editions Phlébologiques Françaises
No article or abstract in this journal may be reproduced in the form of print, photocopy, microfilm or any other means without the express permission of authors and the editor. Editions Phlébologiques Françaises

Phlébologie
Article en partenariat avec "Phlebologie" organe de la Société Allemande de Phlébologie
Phlébologie 2009, 62, 1. p. 23-34

Foam sclerotherapy, how to improve results and reduce side effects

Morrison N.

Résumé

Pour rendre la sclérothérapie à la mousse plus efficace, on pourrait envisager les méthodes suivantes : une agitation plus vigoureuse afin d'obtenir une mousse plus stable composée de bulles plus petites ; l'augmentation du volume et/ou de la concentration du sclérosant ; l'utilisation d'un cathéter intraveineux ; l'élévation de la jambe pour mieux la vider de son sang. **Pour améliorer la sécurité de la sclérothérapie à la mousse,** on pourrait envisager : l'utilisation d'un cathéter in situ ; l'occlusion de la jonction saphéno-fémorale ; une diminution du volume de la mousse ; l'utilisation de seringues de faible teneur en silicone; la fabrication d'une mousse sans air ; de ne pas utiliser de sclérosants en forte concentration chez les patients avec des segments de veine fémorale dédoublés ; l'élévation de la jambe avant et après l'injection de mousse ; le maintien du patient immobile après l'injection. Une série d'études et d'exercices est présentée qui mettent en doute la validité de nombreuses méthodes proposées pour limiter la dispersion de la mousse après injection. L'utilisation de mousse fabriquée sans air pourrait diminuer l'incidence d'effets secondaires.

Mots clés : sclérothérapie à la mousse ; échographie transthoracique ; Doppler transcranien.

Summary

Methods to improve the efficacy of foam sclerotherapy might include: more vigorous agitation methods to produce more stable foam with smaller bubble size, increasing the volume and/or concentration of the sclerosing agent, use of an intravenous catheter, and leg elevation to evacuate as much blood as possible. Methods to improve the safety of foam sclerotherapy might include: use of an intravenous indwelling catheter; saphenofemoral junction occlusion; low foam volume; use of low silicon syringes; use of non air-based foam; avoidance of high concentration sclerosing agents in patients with duplicated femoral vein segments; leg elevation before or after injection of foam; and maintaining patient immobility after injection. A series of studies and exercises are described which call into question many methods proposed to limit the dispersal of injected foam. The use of non air-based foam may reduce the incidence of side effects.

Keywords : Foam sclerotherapy, transthoracic echocardiography, transcranial Doppler.

Introduction

Reports of sclerosis of abnormal lower extremity veins using foam sclerotherapy (UGFS) have appeared in the world literature since 1950.[1] Beginning with personal reports by Antonio Luis Cabrera, and then with literature reports in 1997[2], discussion has continued to gain momentum.[3-6]

The detergents used to create foam for sclerosis are: sodium morrhuate, ethanolamine oleate, sodium tetradecyl sulfate (STS), and polidocanol. In most reports either Polidocanol or STS has been utilized.

Successful ablation rates have been reported to range from 68%7 to 96%8, although interpretation of these results is made more difficult because of the differences in definitions of success, the use of surrogate markers (occlusion of treated vein, resolution of reflux), differing primary outcome markers (resolution of symptoms, improved quality of life scores, recurrent varices, ulcer healing), and the number of UGFS sessions needed to achieve success, among others. Moreover, reports of follow up periods range from 1 month to 10 years, although the studies reporting results of over 3 years demonstrated success rates of 81%-92%.[9-12]

To demonstrate the difficulty in obtaining accurate information from duplex scans following treatment, we have shown that efforts to identify and report a surrogate marker such as incomplete ablation of the treated vein by duplex scan are plagued by inconsistencies in the sensitivity of duplex equipment.[13] These inconsistencies directly affect the ability to detect residual flow in the treated vein, and potentially lead to overestimation of success rates. Furthermore, the accuracy of the follow up duplex examination is dependent on the expertise and independence of the examiner, and the vigor with which the examination is conducted.

Many methods proposed to improve efficacy and safety have appeared in the literature and have been presented in scientific congresses around the world. These methods will be the subject of this article.

Nick Morrison, MD - 8575 E. Princess Dr - Suite 223 - Scottsdale, AZ 85255 - Tel: 480 860 6455 - Fax: 480 860 6679"
email: nickmorrison2002@yahoo.com

Aucun article ou résumé dans cette revue ne peut être reproduit sous forme d'imprimé, photocopie, microfilm ou par tout autre procédé sans l'autorisation expresse des auteurs et de l'éditeur. Editions Phlébologiques Françaises
No article or abstract in this journal may be reproduced in the form of print, photocopy, microfilm or any other means without the express permission of authors and the editor. Editions Phlébologiques Françaises

Improvement of Efficacy

Suggestions to improve efficacy (Table 1) have included agitation methods which enhance the durability and uniformity of foam[4,14], increasing the concentration of the liquid sclerosant[15-16], and increasing the volume of foam utilized during and injection session.[15,17-18]

However in a review of the published and unpublished data available in the world literature, Jia, et al19 concluded that there exists "insufficient data to determine the optimal volume of foam, optimal concentration and optimal foam-producing method."

Foam sclerotherapy of the saphenous vein via an indwelling catheter may be able to better deliver sclerosant foam to the endothelium of the targeted vein.[20] However, according to the 2nd European Consensus Conference on Foam Sclerotherapy, there is no clear consensus on the use of catheters for foam sclerotherapy.[21]

Foam production methods that create microbubbles of smaller size may add to the efficacy by increasing the direct contact of the sclerosing agent with the endothelium first by displacing blood as much as possible from the targeted vein; and second by greatly increasing the total surface area of the smaller bubbles to which the active sclerosant is attached, thereby increasing endothelial contact.[22-23]

For similar reasons, leg elevation prior to the injection will also help clear blood from the vein, thus allowing greater sclerosant contact with the endothelium and less sclerosant mixing with and deactivation by blood.[24]

And finally, it is clear that simply creating thrombosis of a target vein will likely not result in permanent occlusion of the vein. Damage to or destruction of the vein wall is necessary to assure sclerosis. [24-25]

Table 1

- Increased Efficacy
- Agitation methods
- Increased sclerosant concentration
- Increased sclerosant volume
- Indwelling catheter
- Smaller bubble size
- Leg elevation (for "empty vein")

Improvement of Safety

Just as with liquid sclerotherapy, all of the methods proposed to improve efficacy carry the risk of side effects and complications.[19] Many reports in the literature mention the safety of foam sclerotherapy anecdotally[15,26-35], and there are numerous reports describing infrequent or rare neurologic or visual disturbances,[15,22,27,30,33-38] A few reports examine specific complications of foam39-42, but studies that critically examine the overall safety of foam for sclerosis of abnormal leg veins remain scant.[22,36,43]

Several methods have been proposed to improve the safety of foam sclerotherapy, some of which are listed in Table 2.

Table 2

- Indwelling catheter (Balloon-tipped or open-ended)
- SFJ occlusion
- Limitations of sclerosant volume
- Low silicon syringe
- Non air-based foam
- Avoidance of duplicated femoral vein thrombosis
- Leg elevation pre-injection
- Leg elevation post-injection
- Patient immobility

One method to improve safety of ultrasound guided foam sclerotherapy is to insert an indwelling catheter for the delivery of foam rather than direct injection.[20,44] By aspiration of blood and a small "test dose" of foam injected through the catheter into the target vein, this method will give the phlebologist more assurance that the catheter is intravenous and thus foam is being delivered to the targeted vein. It will also allow for the formation of foam to immediately precede injection, thus producing a more robust foam as there will be little time for foam degradation that produces bubble coalescence, larger bubble size, and thereby less active sclerosant made available for endothelial contact. Large bubbles migrating into the central circulation potentially carry the increased risk of lodging in the arterial microcirculation in the presence of a right-to-left shunt.[39] When foam is prepared and then injected through the syringe and needle directly into a vein, there will be necessarily some time between foam production and injection, depending on how long it takes to image the target vein and advance the needle into the vein. Factors influencing this "lag time" are the technical skill of the person acquiring the target vein image and the skill of the phlebologist in needle puncture of the target vein.

A ballon-tipped catheter will allow for occlusion of the saphenous junction, theoretically preventing foam from entering the deep venous system. However, during a study using just such a catheter in the author's center, foam bubbles could be seen by duplex examination entering the deep venous system during balloon inflation through small thigh perforators resulting in a significantly higher incidence of deep venous thrombosis (4/27 patients, 15% - unpublished data).[45]

Aucun article ou résumé dans cette revue ne peut être reproduit sous forme d'imprimé, photocopie, microfilm ou par tout autre procédé sans l'autorisation expresse des auteurs et de l'éditeur. Editions Phlébologiques Françaises
No article or abstract in this journal may be reproduced in the form of print, photocopy, microfilm or any other means without the express permission of authors and the editor. Editions Phlébologiques Françaises

And in fact many European phlebologists think it is better to have foam gradually migrating into the deep venous system than to have a large bolus enter the central circulation when the occlusive balloon is deflated.

Limiting the volume of foamed sclerosant injected at any one time has been proposed as a method to improve safety.[21-22] In a study from the author's center, examination of the side effects and complications of large volume air-based foam is described below: [46]

Study 1

Objective

A prospective clinical trial of 49 consecutive patients with truncal or nontruncal superficial venous insufficiency, treated with UGFS using 1% Polidocanol air-based foam, to analyze rates of peri-operative toxicity and complications, and to establish an adverse effect profile.

Materials and Methods

Forty-nine patients with truncal or nontruncal venous insufficiency, all with previous ablation of the proximal great saphenous vein, were treated with 1% Polidocanol foam, injected under ultrasound guidance into the distal great or small saphenous veins and/or tributaries. Polidocanol foam was produced by the Tessari method, using room air and 1% Sclerovein®, mixed in a 4:1 ratio. Injected volumes ranged from 8-52mL (mean, 27mL). Patient interviews and monitoring of BP, pulse rate, respiratory rate, EKG, and pulse oximetry were conducted preoperatively, at 15-minute intervals during treatment, immediately postoperatively, 30 and 60 minutes after completion of treatment (longer if symptoms occurred). Patients were then interviewed 2, 6, and 24 hours post treatment. Adverse effects were monitored for 24 hours or until resolution, and included: chest discomfort, dry cough, changes in BP, pulse rate, EKG, or pO2, dizziness, visual disturbances, and nausea.

Results

Statistically significant decreases in heart rate occurred ($P<.001$), less than 5 bpm, which were not physiologically significant. Blood pressure, respiratory rate, electro-cardiogram, and partial oxygen pressure (pO2) did not change significantly during UGFS or for 60 minutes afterwards ($P>.05$). The most commonly occurring adverse effects were dry cough, chest discomfort, and visual disturbances (none of which occurred in patients receiving less than 16mL of foam), although only with dry cough was there a positive correlation between symptoms and increasing volume of injectate over 16mL. Chest discomfort was seen in 18% (4/49). Visual disturbances were experienced by 8.2% (4/49). Other adverse effects included dizziness reported in 12% and nausea in 4%. Side effects rarely lasted more than 1-4 hours. No deep vein thromboses (DVTs) were detected by follow-up duplex scan performed in response to symptoms.

Conclusions

Ultrasound-guided injection of Polidocanol foam, in large volumes, appears to be associated with few significant complications, although some short-lived adverse effects do occur in patients injected with more than 16mL of foam. Concerning these adverse effects, only dry cough appeared to have a direct correlation with the volume of foam injected (above 16mL).

Use of low-silicone syringes enhances foam stability, it is presumed because silicone helps speed foam degradation. Thus foam will remain stable longer with silicone-free or low-silicone syringes, allowing for more time to complete a successful injection.[23,47]

Foam degradation will also be influenced by the type of gas used to create the foam. While the use of CO2-based foam may be desirable to lower the side effect profile[46], the same high solubility coefficient and high diffusibility in body fluids results in rapid degradation and thus significantly shortens the time period between foam production and injection.[16] As interest grew in replacing the air used to produce foam with a more soluble and diffusible gas[27,39], a second clinical trial was conducted to test the theory that because of its presumably more rapid dissolution CO2-based foam would produce fewer adverse effects than air-based foam.

Study 2

Objective

To report a prospective clinical trial, enrolling 128 patients with truncal or nontruncal superficial venous insufficiency, treated with ultrasound-guided injection of 1% Polidocanol CO2-based foam, analyzing rates of toxicity and complications in the perioperative period, and to establish an adverse effect profile.

Materials and Methods

This study was a follow up to the study using air-based foam, and was performed in precisely the same manner, utilizing different patients who also had previously undergone saphenous vein ablation procedures. In this study, pure CO2 was used to produce the foamed sclerosant instead of air with a range of injected foam volume of 6-45mL (mean=26mL).

Aucun article ou résumé dans cette revue ne peut être reproduit sous forme d'imprimé, photocopie, microfilm ou par tout autre procédé sans l'autorisation expresse des auteurs et de l'éditeur. Editions Phlébologiques Françaises
No article or abstract in this journal may be reproduced in the form of print, photocopy, microfilm or any other means without the express permission of authors and the editor. Editions Phlébologiques Françaises

Results

As in Study 1, no physiologically significant changes were seen while monitoring blood pressure, electrocardiogram, heart rate, respiratory rate, or pO2. Chest tightness, dry cough, and dizziness occurred in 3.1% (4/128), 1.6% (4/128), and 3.1% (4/128) respectively, statistically significantly less often with CO2-based foam than with air-based foam (P<0.001, P<0.001, P<0.02 respectively). **(Table 3)**

CO2 vs.Air-based Foam Side Effects			
Symptom	Air	CO2	Chi square
Chest tightness	9 (18%)	4 (3.%)	P<.001
Dry Cough	8 (16%)	2 (1.6)	P<.001
Dizziness	6 (12%)	4 (3.1%)	P=.019
Metallic/ Medicinal Taste	0 (0%)	2 (1.6)	P=.39
Nausea	2 (4%)	3 (2%)	P=.53
Circumoral Paresthesia	0 (0%)	1 (0.8%)	P=.53

TABLE 3: Comparison of Side effects of patients treated with CO2-based foam and air-based foam

Visual disturbances and nausea were seen to trend lower for an incidence of 3.1% (4/128) and 2% (3/128) respectively, compared to the air-based foam group (8.2% and 4% respectively, P=0.15).

Conclusions

Comparing CO2-based foam with air-based foam, adverse effects decreased statistically significantly (or trended downward) if CO2 was employed to produce the sclerosing foam.

Tessari has shown that a gas combination of 70% CO2 and 30% O2 to produce foam will result in a more stable, longer-lasting foam than pure CO2-based foam.[48] Of practical significance is if, as in most of Europe, the phlebologist must also function as the sonographer, use of the more stable CO2/O2-based foam will be more advantageous allowing for more time to acquire the target vein image, direct the needle into the vein, and inject foam. The side effect profile advantage of a more soluble gas such as the CO2/O2 combination as compared to air is also maintained.

In a follow up study to the previous two studies, reported in November, 2007, another cohort of patients were injected with CO2/O2-based foam and the side effect profile was compared to that of the air-based foam and the pure CO2-based foam.[49] Patients in the CO2/O2-based foam group were 40 times less likely to experience the side effects of dry cough, metallic taste, and chest tightness than patients in the air-based foam group. And patients in the CO2/O2-based foam group were 7 times less likely to experience nausea, visual disturbances, and dizziness than patients in the air-based foam group.

Another specific safety concern regarding complications of foam sclerotherapy is the incidence of deep vein thro mbosis(DVT).[15,27,32,36,50-51] An apparently high incidence of thrombosis in duplicated femoral vein segments following UGFS has been seen in our center. The following study was conducted to see if the presence of a duplicated femoral vein represents a risk factor for thrombosis.

Study 3

Objective

Because it has been reported that approximately 30% of the normal population has a duplicated femoral vein segment[26,52], and the incidence of deep vein thrombosis (DVT) following ultrasound guided foam sclerotherapy is generally reported to be <1%[32,36,50-51], the aim is to determine if the presence of a duplicated femoral vein segment is a risk factor for development of deep vein thrombosis following ultrasound guided foam sclerotherapy.

Patients, materials, and methods

Forty-three patients with duplex ultrasound-documented true duplicated segments of femoral veins were treated with ultrasound guided foam sclerotherapy for superficial venous insufficiency, using a foam volume range of 1.5-9mL. One to three percent Polidocanol and sodium tetradecylsulfate (STS) foamed with air or CO2 gas was injected into truncal and non truncal superficial veins of the lower extremity. Injections were delivered by needle or a balloon-tipped catheter. Standard post sclerotherapy treatment included immediate and continued compression and ambulation, with 30-40mmHg compression hose for three weeks. Detailed duplex examination of the treated leg was conducted within 48 hours, including evaluation of the common femoral vein, femoral vein, profunda femoral vein, popliteal vein, posterior tibial veins, anterior tibial veins, peroneal veins, and gastrocnemius veins. If thrombosis of any vein was identified, follow up duplex examination was continued until resolution or stabilization

Aucun article ou résumé dans cette revue ne peut être reproduit sous forme d'imprimé, photocopie, microfilm ou par tout autre procédé sans l'autorisation expresse des auteurs et de l'éditeur. Editions Phlébologiques Françaises
No article or abstract in this journal may be reproduced in the form of print, photocopy, microfilm or any other means without the express permission of authors and the editor. Editions Phlébologiques Françaises

of the thrombosis was confirmed. If no thrombosis was identified, the patient was re-examined at one week and six weeks.

Results

Five of 43 patients (8.6%) were found to have complete thrombosis of the duplicated femoral vein segment. (Figure 1) In four of the five patients with thrombosis 3% STS air-based foam was used, and in the remaining patient 3% Polidocanol CO2-based foam was used. No other deep venous thromboses were identified.

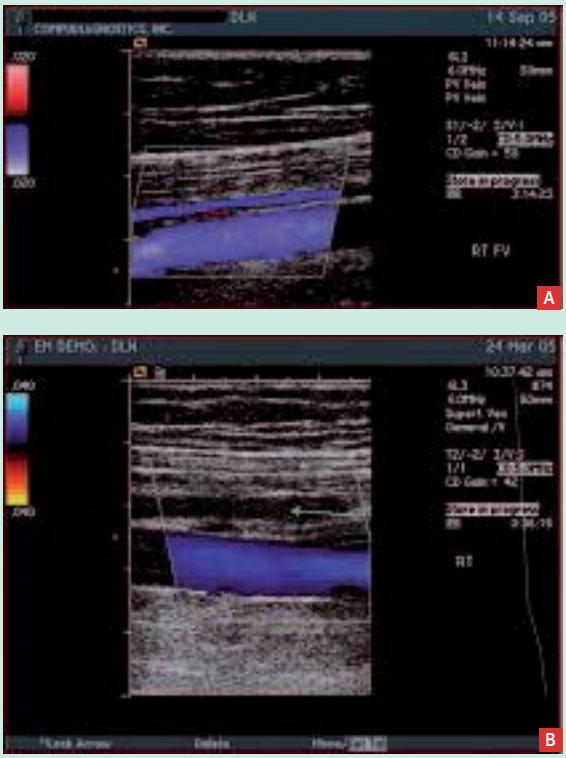

FIGURE 1: a: color Doppler showing antegrade flow in duplicated femoral vein segment
b: color Doppler post foam sclerotherapy showing thrombosed duplicated femoral vein segment (green arrow)

Conclusion

The presence of a duplicated femoral vein segment in patients undergoing ultrasound guided foam sclerotherapy appears to be a risk factor for deep vein thrombosis in the duplicated segment, especially with the use of 3% detergent sclerosants.
Next, because of uncertainty regarding the extent to which foam travels from the target vein and the belief expressed in scientific assemblies and the literature that the dispersal of foam, once injected, could be controlled and specifically prevented from entering the deep venous system, a series of exercises were designed and conducted to follow the course of foam injected into peripheral superficial leg veins.

Exercise 1

Objective

Follow course of foam from peripheral vein injection site to deep venous system and heart

Materials and Methods

Twenty-one patients undergoing ultrasound guided foam sclerotherapy using 1% foamed sclerosant, were injected with 1-2mL of foamed sclerosant into 1-2mm peripheral superficial leg veins. The foam was produced in the standard Tessari method33– 4:1 ratio of room air to 1% liquid Polidocanol. All patients had a preoperative transthoracic echocardiogram negative for right-to-left shunt. All patients had transthoracic echocardiography simultaneous with ultrasound guided injection of foam.

Results

Bubbles could be identified by ultrasound in the injected peripheral vein, perforator vein, deep venous system, inferior vena cava, and the right heart 10-30 seconds after every injection. Furthermore, bubbles could still be seen in the right heart more than two minutes after each injection.

Conclusion

Small volumes of foamed sclerosants injected into peripheral venous leg tributaries are quickly and persistently identified within the perforators, deep venous system, inferior vena cava, and heart, even several minutes following the initial injection. Dispersal of foam microbubbles is rapid and extensive.

Because bubbles passed so quickly to the right heart, the next exercise was designed to determine if a right-to-left shunt could be identified by means of the appearance of bubbles in the left heart.

Exercise 2

Objective

To test whether it is possible to reliably identify right-to-left shunting during ultrasound guided foam sclerotherapy using simultaneous transthoracic echocardiography.

Aucun article ou résumé dans cette revue ne peut être reproduit sous forme d'imprimé, photocopie, microfilm ou par tout autre procédé sans l'autorisation expresse des auteurs et de l'éditeur. Editions Phlébologiques Françaises
No article or abstract in this journal may be reproduced in the form of print, photocopy, microfilm or any other means without the express permission of authors and the editor. Editions Phlébologiques Françaises

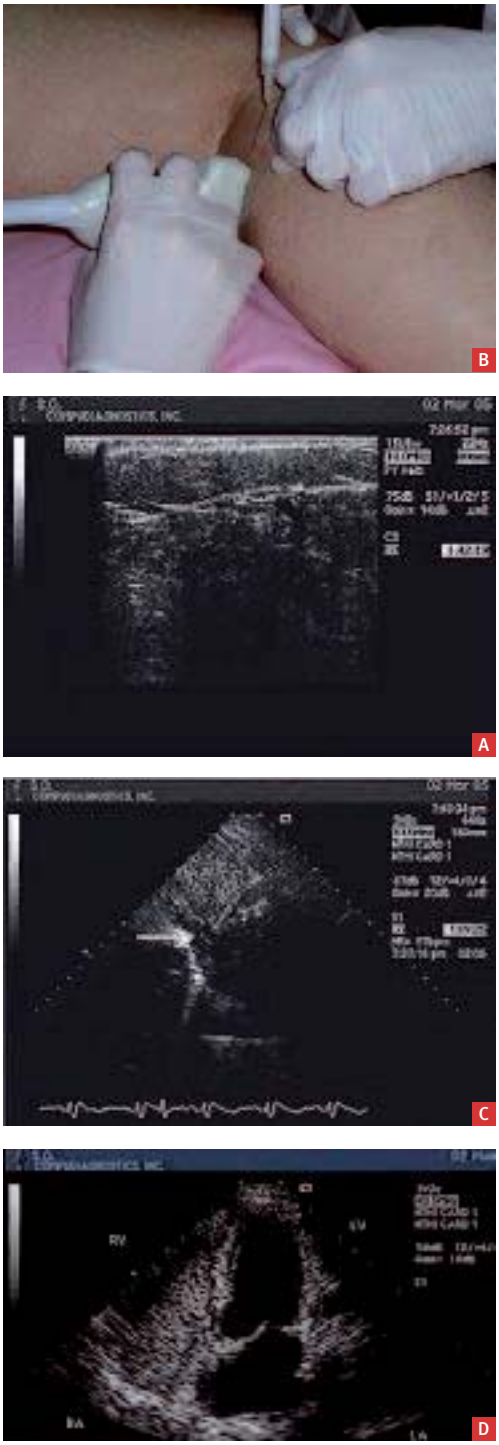

FIGURE 2: Under ultrasound guidance, a 1mm peripheral leg vein is injected with foam(a), bubbles are seen in popliteal vein (b, arrows), in the abdominal inferior vena cava (c, arrow-foam debris IVC), and in the right heart (d, RV, RA).

Materials and Methods

With symptoms of visual disturbances, headache, or altered mentation following UGFS 21 patients were studied using additional UGFS simultaneous with transthoracic echocardiography. Patients in reversed Trendelenberg and modified left lateral decubitus postions, during and after injection of 1-3mL of foam into a peripheral leg vein, were studied with transthoracic echocardiography. Pressure gradients were then established by asking patients to perform Valsalva's maneuver or cough.

Results

No right-to-left shunts could be demonstrated on preoperative transthoracic echocardiography and none were seen immediately following ultrasound guided foam injection into a peripheral leg vein, even though bubbles were readily identified in the right heart. However, following the establishment of pressure gradients with Valsalva's maneuver or cough there was demonstrated right-to-left shunting in 7 of 21 patients (30%). This ratio approximates that in the normal population expected to have patent foramen ovale.[53]

FIGURE 3: four chamber transthoracic echo showing left heart with bubbles from right heart within 10 seconds of initial injection of foam into peripheral leg vein (arrow-left heart chamber foam debris).

Conclusion

It is possible to reliably identify right-to-left shunts in patients undergoing peripheral leg vein ultrasound guided foam sclerotherapy with the use of transthoracic echocardiography and the establishment of a pressure gradient.

Because bubbles could readily be identified in the left heart in patients with right-to-left shunts, the question arose as to whether bubble emboli could be identified by transcranial Doppler (TCD) monitoring of the middle

Aucun article ou résumé dans cette revue ne peut être reproduit sous forme d'imprimé, photocopie, microfilm ou par tout autre procédé sans l'autorisation expresse des auteurs et de l'éditeur. Editions Phlébologiques Françaises
No article or abstract in this journal may be reproduced in the form of print, photocopy, microfilm or any other means without the express permission of authors and the editor. Editions Phlébologiques Françaises

cerebral arteries in patients with proven right-to-left shunts. Exercise 3 examines this question.

Exercise 3

Objective

Examine the middle cerebral artery for emboli during and following UGFS by means of transcranial Doppler via the temporal window in patients with known right-to-left shunts undergoing UGFS.

Materials and Methods

Seven patients found to have right-to-left shunts during simultaneous ultrasound guided foam sclerotherapy of peripheral superficial veins of the lower extremity and transthoracic echocardiography were re-examined adding bilateral transcranial Doppler monitoring of the middle cerebral arteries. One to three mL of foam were injected into a peripheral leg vein 1-2mm in diameter under ultrasound guidance, with the patient in a modified left lateral supine position (in order to permit simultaneous UGFS, transthoracic echocardiography, and transcranial Doppler monitoring), followed by multiple active calf pumps to mobilize the foam into the central circulation.

Results

Four of seven patients (57%) were found to have middle cerebral artery HITS (High-Intensity Transient Signals) during the transcranial Doppler examination, confirmed with 97% likelihood to be emboli.

Conclusions

Emboli can be detected and followed through the heart into the cerebral circulation by use of transcranial Doppler in patients undergoing UGFS who have right-to-left shunts (Figure 4).

Because the exercise described above is cumbersome for patients, technologists, and physicians, we are attempting to simplify our investigations by designing a protocol wherein only bilateral transcranial Doppler monitoring is performed during ultrasound guided foam sclerotherapy on a series of patients in which the status of any right-to-left shunting was unknown. We have observed that patients frequently will not develop neurologic or visual symptoms until they move upon completion of the foam sclerotherapy session. We are examining the timing of the symptoms to test for a temporal correlation to emboli in the middle cerebral arteries. This study is ongoing and will be presented with a detailed analysis of the data at the 22nd Annual American College of Phlebology Congress, November, 2008.

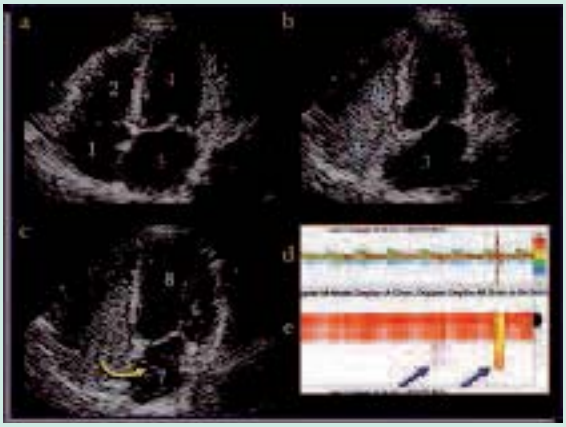

FIGURE 4:
a – Four chamber view of heart on transthoracic echocardiography
b – Bubbles filling right atrium and ventricle following injection of foam sclerosant into peripheral leg vein
c - Bubbles (yellow arrow) progressing from right atrium through patent foramen ovale into left atrium
d,e – Transcranial Doppler images depicting HITS (blue arrows) in middle cerebral artery following foam injection into peripheral leg vein

A major question that remains unanswered is whether neurologic or visual symptoms can be correlated with bubble emboli in the cerebral circulation. One could postulate that these emboli could lodge in the cerebral microcirculation, causing ischemia which produces the transient symptoms described by patients. An elegant study was conducted by David Eckmann, MD, et al39, sponsored in part by the manufacturer of a commercial foam preparation, to compare flow characteristics of commercial foam to so-called "homemade" foam (such as is prepared in all vein treatment centers currently using foam sclerotherapy).

Study 4

Microvascular Embolization Following Polidocanol Microfoam Sclerosant Administration*

Objective

To determine the relationship between polidocanol microfoam formulation and arteriolar embolization bubble lodging and clearance in vivo.

Materials and Methods

Polidocanol microfoam formulations using different physiologic gas mixtures composed primarily of oxygen

*David M. ECKMANN, PHD, MD, Shunji KOBAYASHI, MD, PHD,† AND Min LI, MD‡

Aucun article ou résumé dans cette revue ne peut être reproduit sous forme d'imprimé, photocopie, microfilm ou par tout autre procédé sans l'autorisation expresse des auteurs et de l'éditeur. Editions Phlébologiques Françaises
No article or abstract in this journal may be reproduced in the form of print, photocopy, microfilm or any other means without the express permission of authors and the editor. Editions Phlébologiques Françaises

and carbon dioxide were mixed with venous blood and injected into the rat cremaster arterial microcirculation. Bubble dimensions and dynamics were recorded using intravital microscopy. This was, in essence, a comparison of so-called "homemade" foam (air-based Polidocanol foam as produced by the majority of phlebologists using the Tessari method) and commercially-prepared foam (Varisolve - Provensis, BTG).

Results

Bubble entry frequency, size, and dynamics depended on microfoam formulation. Air-based bubbles lodged in arterioles, obliterating blood flow. Varisolve bubbles entered but either did not lodge or cleared within seconds. Bubble size and number were different among these microfoams.

The commercially-prepared foam bubbles were smaller than "homemade" foam bubbles, and did not appear to obstruct micro-arterial flow as did the bubbles from "homemade" foam.

Conclusions

The Varisolve formulations produced smaller embolism bubbles than occurred with air-based microfoam. Rapid clearance of Varisolve bubbles suggests that they are so small that they do not have adequate surface area available for significant binding interactions with arteriolar endothelium. Larger air-based bubbles obstruct arteriolar vessels and block blood flow.

While Dr. Eckmann did not speculate as to whether neurologic or visual symptoms might be caused by obstruction in the cerebral arterial microcirculation by bubble emboli, several centers have postulated that certain maneuvers might have a protective effect on the cerebral circulation by limiting or preventing bubbles from arriving in the brain. We conducted a series of experiments designed to test the efficacy of these maneuvers in limiting or preventing the dispersal of microbubbles.

Testing Theories

Theory 1

If the patient is kept in a moderate Trendelenberg position, foam injected into truncular veins of the leg under ultrasound guidance will "rise" to the distal leg rather than progress into the central circulation.

Method

3mL of 1% Polidocanol air-based foam injected into the great saphenous vein in the distal thigh under ultrasound guidance in 5 patients.

FIGURE 5: Four chamber transthoracic echocardiogram of patient in Trendelenberg three seconds following injection with patient in Trendelenberg. Bubbles are seen to fill the right atrium and ventricle (RA and RV).

Conclusion

Trendelenberg position does not prevent foam from entering the central circulation

Theory 2

Keeping patients immobile following ultrasound guided foam sclerotherapy will prevent bubbles from dispersing into the central circulation.[21]

Method

2mL of 1% Polidocanol air-based foam injected into a 1.7mm peripheral leg vein under ultrasound guidance, with the patient immobile for over 10 minutes, while continuously monitoring the heart for bubbles using transthoracic echocardiography.

FIGURE 6: Four chamber transthoracic echocardiogram of immobile patient 10 minutes following ultrasound guided injection. Bubbles can still be detected in the right heart (arrow-right heart bubbles).

Aucun article ou résumé dans cette revue ne peut être reproduit sous forme d'imprimé, photocopie, microfilm ou par tout autre procédé sans l'autorisation expresse des auteurs et de l'éditeur. Editions Phlébologiques Françaises
No article or abstract in this journal may be reproduced in the form of print, photocopy, microfilm or any other means without the express permission of authors and the editor. Editions Phlébologiques Françaises

Conclusion

Maintaining patient immobility for a period of time following and ultrasound guided foam injection into a peripheral leg vein will not prevent bubbles from entering the central circulation

Theory 3

If the patient remains immobile during ultrasound guided foam sclerotherapy, bubbles will not pass into the left heart through a right-to-left shunt

FIGURE 7: Four chamber transthoracic view of heart in immobile patient showing right heart filled with bubbles (right heart chamber foam debris), and also in the left heart.

Conclusion

In patients with existent right-to-left, maintaining patient immobility following UGFS does not prevent bubbles from circulating to the left heart.

Theory 4

If the patient remains immobile for several minutes after ultrasound guided foam sclerotherapy, foam will then not embolize to the cerebral circulation.

Conclusion

Following injection of a small peripheral leg vein, using small volumes of foamed sclerosant, just as foam is detected in the left heart in patients with right-to-left shunts following UGFS, emboli can also be detected in the middle cerebral artery when the patient sits up after maintaining immobility for as long as 15 minutes.

Theory 5

Using low volumes of foam during ultrasound guided foam sclerotherapy will prevent cerebral embolization.[54] See Figure 8 above

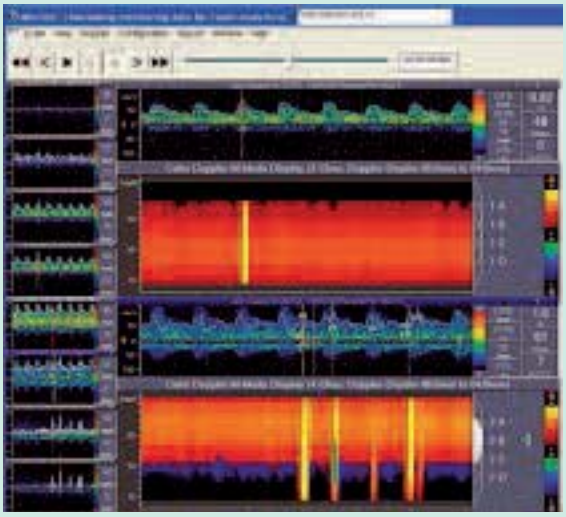

FIGURE 8: Transcranial Doppler tracing of middle cerebral artery in an immobile patient 15 minutes after being injected with 3mL of 1% foamed sclerosant into a 2mm peripheral leg vein under ultrasound guidance. The patient remained immobile following the injection, and then carefully (to avoid disruption of the TCD monitoring device) sat up. Several emboli can be identified in the middle cerebral artery (lower row 2A-2D).

Conclusion

Cerebral emboli can readily be detected by TCD following injection of as little as 3 mL of foam during UGFS.

Limiting the volume of foam injected in any one sclerotherapy session will not prevent cerebral emboli in patients with right-to-left shunts.

Questions

While some information may be gleaned from these studies, other questions have arisen or remain unanswered.

Do the bubbles seen in the heart on transthoracic echocardiography during UGFS contain active sclerosing agent?

Are the cerebral emboli seen on transcranial Doppler following UGFS gas bubbles, cellular debris, or other particles with or without active sclerosant agent?

Is there a positive correlation between the number of emboli and the development of symptoms?

Is there a positive correlation between the number of emboli and the volume of foam injected, or with the development of symptoms?

And lastly, since all of the adverse effects in **Table 4** have been reported following the use of liquid sclerosants,[15] are these symptoms now reported following UGFS related to the chemical sclerosant itself, cellular debris from

Aucun article ou résumé dans cette revue ne peut être reproduit sous forme d'imprimé, photocopie, microfilm ou par tout autre procédé sans l'autorisation expresse des auteurs et de l'éditeur. Editions Phlébologiques Françaises
No article or abstract in this journal may be reproduced in the form of print, photocopy, microfilm or any other means without the express permission of authors and the editor. Editions Phlébologiques Françaises

vein wall destruction, the foam transmission agent and resultant gas bubbles, or something else entirely?

The answers to some of these questions may come as a result of carefully-conducted clinical trials currently on-going in the U.S., specifically looking for adverse effects of cerebral, cardiac, and renal origin.

Table 4

- Adverse Effects
- Dry cough
- Migraine
- Chest tightness
- Circumoral paresthesia
- Metallic taste
- Nausea
- Dizziness
- Hyperpigmentation
- Occular migraine
- Visual disturbance
- Panic attack
- Respiratory difficulty
- Cutaneous necrosis
- DVT
- STP

Conclusions

In spite of the fact that it is not possible to control the course and dispersal of foam injected into peripheral or truncal superficial veins, and in light of the thousands of UGFS sessions performed throughout the world on a daily basis with minimal or rare adverse effects reported, UGFS appears to be a reasonably safe method of superficial venous ablation. However, it may be prudent that caution should guide the phlebologist as more information on the physiologic effects of foam is forthcoming.

References

1. Orbach E.J. Contributions to the therapy of the varicose complex. *J Int Coll Surg* 1950; 29: 765–71.
2. Cabrera Garrido J., Cabrera J.R. J., Garcia-Olmedo M.A. Elargissement des limites de la sclerotherapie: nouveaux produits sclerosants. *Phlebologie* 1997; 50: 181–8.
3. Monfreux A. Treatement sclerosant des troncs sapheneis et leurs collaterales e gros calibre par la methode MUS. *Phlebologie* 1997; 50: 351–3.
4. Tessari L. Nouvelle technique d'obtention de la sclero-mousse. *Phlebologie* 2000; 53: 129–33.
5. Cabrera AL. Endoluminal therapy with echo-guided sclerosing foam - Current Situation after 30 years of experience. UIP World Congress Chapter Meeting, San Diego, California, 2003.
6. Hamel-Desnos C, Ouvry P, Benigni J-P, Boitelle G, Schadeck M, Desnos P, Allaert F-A. Comparison of 1% and 3% polidocanol foam in ultrasound guided sclerotherapy of the great saphenous vein: A randomised, double-blind trial with 2-year follow-up. "The 3/1 Study". *Eur J Vasc Endovasc Surg* 2007; 34: 723-9.
7. Yamaki T, Nozaki M, Iwasaka S. Comparative study of duplex-guided foam sclerotherapy and duplex-guided liquid sclerotherapy for the treatment of superficial venous insufficiency. *Dermatol Surg* 2004; 30: 718–22.
8. Hamel-Desnos C, Allaert FA, Benigni J, Boitelle G, Chleir F, Ouvry P et al. Polidocanol foam 3% versus 1% in the great saphenous vein: Early results. *Phlebologie* 2005; 58: 175–82.
9. Belcaro G, Cesarone MR, Di Renzo A, Brandolini R, Coen L, Acerbi G et al. Foam-sclerotherapy, surgery, sclerotherapy, and combined treatment for varicose veins: A 10-year, prospective, randomized, controlled, trial (VEDICO trial). *Angiology* 2003; 54: 307–15.
10. Cabrera J., Cabrera J. Jr, Garcia-Olmedo A. Treatment of varicose long saphenous veins with microfoam form: Long-term outcomes. *Phlebology* 2000; 15: 19-23.
11. McDonagh B., Huntley D.E., Rosenfeld R., King T., Harry J.L., Sorenson S. et al. Efficacy of the comprehensive objective mapping, precise image guided injection, anti-reflux positioning and sequential sclerotherapy (COMPASS) technique in the management of greater saphenous varicosities with saphenofemoral incompetence. *Phlebology* 2002; 17: 19–28.
12. Grondin L. Foam echosclerotherapy of incompetent saphenous veins. *Phlebolymphology* 2003; 42: S24.
13. Morrison N. The Interaction and Complimentary Role of Surgery, Sclerotherapy and Thermal Ablation in the Managment of Varicose Veins - The US Perspective. The Australian and New Zealand Society for Vascular Surgery, Melbourne, August 2007.
14. Rabe E., Otto J., Schliephake D., Pannier F. Efficacy and safety of great saphenous vein sclerotherapy using standardised polidocanol foam (ESAF): A randomised controlled multicentre clinical trial. *Eur J Vasc Endovasc Surg* 2008; 35: 238-45.
15. Myers K.A., Jolley D., Clough A., Kirwan J. Outcome of ultrasound-guided sclerotherapy for varicose veins: Medium-term results assessed by ultrasound surveillance. *Eur J Vasc Endovasc Surg* 2007; 33: 116-21.

Aucun article ou résumé dans cette revue ne peut être reproduit sous forme d'imprimé, photocopie, microfilm ou par tout autre procédé sans l'autorisation expresse des auteurs et de l'éditeur. Editions Phlébologiques Françaises
No article or abstract in this journal may be reproduced in the form of print, photocopy, microfilm or any other means without the express permission of authors and the editor. Editions Phlébologiques Françaises

16. Wollmann J.-C. An Experimental Model to Pinpoint Properties and Behavior of Sclerosing Foams. 17th Annual Congress of the American College of Phlebology, San Diego, California, 2003.

17. Sierra A., Redondo P., Cabrera J., Cabrera J. Jr, Garcia-Olmedo M.A. Large volume microfoam therapy for recurrent variscose veins. 16th Annual Congress of the American College of Phlebology, Fort Lauderdale, Florida, 2002.

18. Morrison N. Large-volume, ultrasound-guided, polidocanol foam sclerotherapy: A prospective study of toxicity and complications. International Vein Congress 2004. Key Biscayne, Florida, 2004.

19. Jia X., Mowatt G., Burr J.M., Cassar K., Cook J., Fraser C. Systematic review of foam sclerotherapy for varicose veins. *Br J Surg* 2007; 94: 925-36.

20. Gobin J.-P. French experience with sclerotherapy. Angiologia E Cirurgia Vascular, Ubelandia, Brazil, 2008.

21. Breu F.X., Guggenbichler S., Wollmann J.-C. Second European Consensus Meeting on Foam Sclerotherapy. Duplex ultrasound and efficacy criteria in foam sclerotherapy from the 2nd European Consensus Meeting on Foam Sclerotherapy 2006, Tegernsee, Germany. *Vasa* 2008; 37: 90-5.

22. Frullini A., Cavezzi A.. Sclerosing foam in the treatment of varicose veins and telangiectases: history and analysis of safety and complications. *Dermatol Surg* 2002; 28: 11-5.

23. Wollmann J.-C. The History of Sclerosing Foams. *Dermatol Surg* 2004; 30: 694–703.

24. Coleridge Smith P. Saphenous ablation: sclerosant or sclerofoam? *Semin Vasc Surg* 2005; 18: 19-24.

25. Fegan W.G. Injection with compression as a treatment for varicose veins. *Proc R Soc Med* 1965; 58: 874-6.

26. Barrett J.M., Allen B., Ockelford A., Goldman M.P. Microfoam ultrasound-guided sclerotherapy of varicose veins in 100 legs. *Dermatol Surg* 2004; 30: 6-12.

27. Cabrera J., Redondo P., Becerra A., Garrido C., Cabrera J. Jr, Garcia-Olmedo M.A., et al. Ultrasound-guided injection of polidocanol microfoam in the management of venous leg ulcers. *Arch Dermatol* 2004; 140: 667-73.

28. Cavezzi A., Frullini A. The role of sclerosing foam in ultrasound guided sclerotherapy of the saphenous veins and of recurrent varicose veins: Our personal experience. *Aust NZ J Phlebol* 1999; 3: 49-50.

29. Kakkos S.K., Bountouroglou D.G., Azzam M., Kalodiki E., Daskalopoulos M., Geroulakos G.. Effectiveness and safety of ultrasound-guided foam sclerotherapy for recurrent varicose veins: Immediate results. *J Endovasc Ther* 2006; 13: 357-64.

30. Kern P., Ramelet A.A., Wutschert R., Bounameaux H., Hayoz D. Single-blind, randomized study comparing chromated glycerin, polidocanol solution, and polidocanol foam for treatment of telangiectatic leg veins. *Dermatol Surg* 2004; 30: 367-72.

31. Rabe E., Pannier-Fischer F., Gerlach H., Breu F.X., Guggenbichler S., Zabel M. Guidelines for sclerotherapy of varicose veins (ICD 10: 183.0, 183.1, 183.2, and 183.9). *Dermatol Surg* 2004; 30: 687-93.

32. Coleridge Smith P. Chronic venous disease treated by ultrasound guided foam sclerotherapy. *Eur J Vasc Endovasc Surg* 2006; 32: 577-83.

33. Tessari L., Cavezzi A., Frullini A. Preliminary experience with a new sclerosing foam in the treatment of varicose veins. *Dermatol Surg* 2001; 27: 58-60.

34. Wright D., Gobin J.-P., Bradbury A.W., Coleridge Smith P., Spoelstra H., Berridge D., et al. Varisolve polidocanol microfoam compared with surgery or sclerotherapy in the management of varicose veins in the presence of trunk vein incompetence: European randomized controlled trial. *Phlebology* 2006; 21: 180-90.

35. Henriet J.-P. Expérience durant trois années de la mousse de polidocanol dans le traitement des varices réticulaires et des varicosities. *Phlébologie* 1999; 52: 277-82.

36. Guex J.-J., Allaert F.A., Gillet J.-L., Chleir F. Immediate and midterm complications of sclerotherapy: Report of a prospective multicenter registry of 12,173 sclerotherapy sessions. *Dermatol Surg* 2005; 31: 123-8.

37. Hamel-Desnos C., Guias B., Jousse S., Desnos P., Bressollette L. Foam echosclerotherapy by puncture-direct injection: Technique and quantities. *J Mal Vasc* 2006; 31: 180-9.

38. O'Hare J.L., Earnshaw J.J. The use of foam sclerotherapy for varicose veins: A survey of the members of the Vascular Society of Great Britain and Ireland. E*ur J Vas Endovasc Surg* 2007; 34: 232-235.

39. Eckmann D.M., Kobayashi S., Li M. Microvascular embolization following polidocanol microfoam sclerosant administration. *Dermatol Surg* 2005; 31: 636-43.

40. Hoffman K. An unusual complication of facial sclerotherapy. Dermatol Surg 2003; 29: 423-4.

41. Benigni J.-P., Ratinahirana H., Bousser M.G. Polidocanol 400 foam injection and migraine with visual aura [abstract]. 16th Annual Congress of the American College of Phlebology, Ft Lauderdale, Florida, 2002.

42. Scurr J., Gilling-Smith G., Fisher R. Letter to the editor re: Systematic review of foam sclerotherapy for varicose veins (*Br J Surg* 2007; 94: 925-36). *Br J Surg* 2007; 94: 1306-9.

Aucun article ou résumé dans cette revue ne peut être reproduit sous forme d'imprimé, photocopie, microfilm ou par tout autre procédé sans l'autorisation expresse des auteurs et de l'éditeur. Editions Phlébologiques Françaises
No article or abstract in this journal may be reproduced in the form of print, photocopy, microfilm or any other means without the express permission of authors and the editor. Editions Phlébologiques Françaises

43. Alòs J., Carreño P., López J.A., Estadella B., Serra-Prat M. Efficacy and safety of sclerotherapy using polidocanol foam: A controlled clinical trial. *Eur J Vas Endovasc Surg* 2006; 31: 101-7.

44. Brodersen J., Geismar U. Catheter-assisted vein sclerotherapy: A new approach for sclerotherapy of the greater saphenous vein with a double-lumen balloon catheter. *Dermatol Surg* 2007; 33: 469–75.

45. Neuhardt D. Incidence of deep vein thrombosis in a duplicated femoral vein following Foam USG of the GSV. First Days of Phlebology, Parma, Italy, 2006.

46. Morrison N., Neuhardt D.L., Rogers C.R., McEown J., Morrison T., Johnson E., Salles-Cunha S.X. Comparisons of side effects using air and carbon dioxide foam for endovenous chemical ablation. *J Vasc Surg* 2008; 47: 830-6.

47. Lai S.W., Goldman M.P. Does the relative silicone content of different syringes affect the stability of foam in sclerotherapy? *J Drugs Dermatol* 2008; 7: 399-40.

48. Tessari L. 8° International Phlebological Symposium, Bologna, Italy, 2006.

49. Morrison N. Relative incidence of side effects with CO2/O2 foam sclerotherapy comparison air, CO2, &CO2/O2- based foam. 21st Annual Congress, American College of Phlebology, Tucson, Arizona, 2007.

50. Creton D., Uhl J.F. Foam sclerotherapy combined with surgical treatment for recurrent varicose veins: Short term results. *Eur J Vas Endovasc Surg* 2007; 33: 619-24.

51. Pascarella L., Bergan J.J., Mekenas L.V. Severe chronic venous insufficiency treated by foamed sclerotherapy. *Ann Vasc Surg* 2006; 20: 83-91.

52. Dona E., Fletcher J.P., Hughes T.M., Saker K., Batiste P., Ramanathan I. Duplicated popliteal and superficial femoral veins: incidence and potential significance. *Aust N Z J Surg* 2000; 70:438-40.

53. Meier B., Lock J.E. Contemporary management of patent foramen ovale. *Circulation* 2003; 107: 5-9.

54. Breu F.X., Guggenbichler S. European Consensus Meeting on Foam Sclerotherapy, April 4-6, 2003, Tegernsee, Germany. *Dermatol Surg* 2004; 30: 709-17.

Summary of the Phoenix Hemodynamics Conference, Part I,February 7-9, 2009

Nick Morrison
President, American College of Phlebology

It was led by ***Claude Franceschi and Paolo Zamboni, and moderated by Attilio Cavezzi and Nick Morrison.***

During the Conference, information regarding venous hemodynamics and CHIVA was first presented by Drs. Franceschi and Zamboni, followed by examination of live patients with various types of venous disease.

Following each section, a discussion ensued which was joined by the participants at a very high level, including the physics of fluid dynamics, pressure and energy, and anatomic and physiologic vascular topics.

These discussions were extensive, in depth, and produced an outstanding interaction. Participants and leaders alike were excited and engaged by the sessions, with the results being a very high level discourse regarding the hemodynamics of the venous system.

The desire to continue the exploration of these subjects here in the U.S. was unanimously expressed by participants, moderators, and conference leaders.

Venous Hemodynamics sessions have already been scheduled in two conferences in the U.S.: **the International Vein Congress in Miami, Florida in May and the American College of Phlebology Annual Congress in Palm Desert, California in November.**

Dates for Part II of this Hemodynamics Conference, which will be led by ***Massimo Cappelli*** and ***Fausto Passariello***, among others, will be posted in the near future.

Funding for Parts I and II of the Hemodynamics Conference has been generously provided by the American College of Phlebology Foundation.