Aucun article ou résumé dans cette revue ne peut être reproduit sous forme d'imprimé, photocopie, microfilm ou par tout autre procédé sans l'autorisation expresse des auteurs et de l'éditeur. Editions Phlébologiques Françaises
No article or abstract in this journal may be reproduced in the form of print, photocopy, microfilm or any other means without the express permission of authors and the editor. Editions Phlébologiques Françaises

Phlébologie ANNALES VASCULAIRES 2018, 71, 4, p. 35-41

SOCIÉTÉ FRANÇAISE DE PHLEBOLOGIE

Chapitre 15

Duplex ultrasound for early and remote assessment of results

Bertrand Chauzat

Summary

Duplex ultrasound (DUS) has taken a prominent place in phlebology.

In addition to the clinical assessment of superficial venous disorders in the lower limbs, DUS exploration makes it possible to establish an initial state, and to carry out a mapping to define a therapeutic strategy.

DUS is also an essential and almost a permanent aid during endovenous thermal or sclerosing foam treatments.

Finally, it allows precise monitoring of early results, in terms of effectiveness but also complications, as well as the evolution of the treated venous network and possible recurrences.

The polymorphic nature of ultrasound images, particularly at early control, must be known to all, to offer the patient appropriate follow-up and therapeutic support if necessary.

Keywords: Duplex ultrasound, foam sclerotherapy, thermal ablation.

Introduction

Duplex Ultrasound (DUS) is vital for any endovenous treatment of saphenous veins.

We focus on describing the DUS data collected after various endovenous ablations.

Endovenous laser and Radiofrequency of saphenous veins

Ultrasound inspection in immediate post-procedure

A specific element immediately after procedure: the "boiling gases".

Immediately after endovenous laser (EVLA) or radiofrequency ablation (RFA), the visualisation of the treated vein may be hindered by the infiltration of tissues by the tumescence liquid and by the emission of gases resulting from the boiling of the blood.

The latter can create "parasitic" images in the vascular lumen, which sometimes extend into the tributaries of the treated vein.

Heat induced gases are often also responsible for a shadow cone under the treated vein, but this can sometimes help to better locate the vein. It can be viewed in cross section **(Fig. 1)** and longitudinal section **(Fig. 2)**. Since the boiling intensity is very high with the laser, the gases are more present after laser treatment than after the segmental resistive RF procedure (Medtronic-Venefit®).

Indeed, the laser induces temperatures of around 729°C according to Weiss [1] while the resistive catheter of RF Fast® only reaches 120°C; in addition, the temperature rise of the latter is slower.

Objectives of the immediate post-procedure DUS control

Monitoring at this stage uses only B mode ultrasound and is essentially intended to check the patency of the deep venous network, particularly the common femoral vein (CFV) or the popliteal vein (PV), respectively, depending on whether a Great Saphenous Vein (GSV) **(Fig. 3)** or a Small Saphenous Vein (SSV) has been treated.

The control of the immediate appearance of the vein after treatment is only indicative but does not have a decisive predictive value on the quality of the occlusion at this stage.

37 avenue du Professeur Albert Calmette, 24100 Bergerac- France – chauzat.b@gmail.com

Aucun article ou résumé dans cette revue ne peut être reproduit sous forme d'imprimé, photocopie, microfilm ou par tout autre procédé sans l'autorisation expresse des auteurs et de l'éditeur. Editions Phlébologiques Françaises
No article or abstract in this journal may be reproduced in the form of print, photocopy, microfilm or any other means without the express permission of authors and the editor. Editions Phlébologiques Françaises

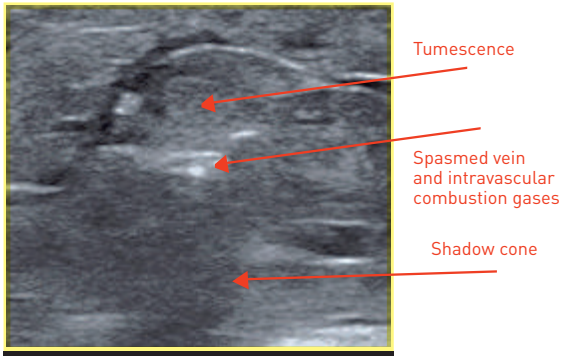

Figure 1: Saphenous trunk immediately after thermal ablation: shadow cone, in cross-section.

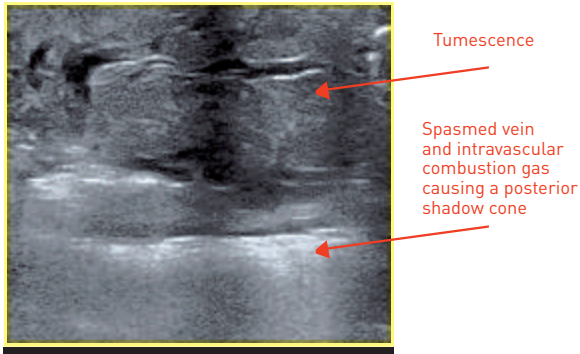

Figure 2: Saphenous trunk: immediately after thermal ablation, in longitudinal section

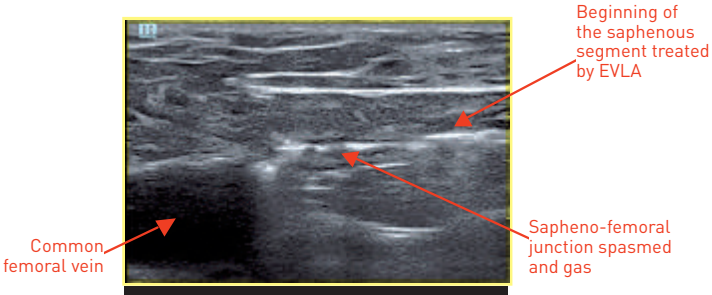

Figure 3: Sapheno-femoral junction in longitudinal section, immediately after a thermal ablation

Ultrasound images

The CFV or PV must be perfectly patent and their lumen well exposed and free, except for some possible images of gases.

The treated vein is the site of a venous spasm with an aspect of parietal thickening. The persistence of an endovenous channel, compressible under the ultrasound probe, is possible, especially if the vein was large.

This residual channel is more frequent after RFA, but has no negative impact on the occlusion, which occurs spontaneously over the following days.

Early Duplex ultrasound monitoring

Objectives of early DUS control

In France, according to the Haute Autorité de Santé (HAS; High Health Authorities), it is recommended to carry out a first clinical and DUS control within 10 days following the thermal ablation [2].

The consensus of the IUP (International Union of Phlebology) recommends a first control at 4 weeks [3].

The DUS control allows to verify the safety (absence of deep vein thrombosis) and the efficiency (correct occlusion of the treated vein) of the treatment.

However, it is generally too early at this stage to assess the final clinical outcome of the procedure, including the impact of the procedure on the subsidence and disappearance of dependent varicose veins.

The territories explored

For greater clarity, we will separate the description of the ultrasound images into two territories: "the sapheno-femoral junction" (SFJ) and "the saphenous vein trunk".

The first corresponds to the safety check, the second to the occlusion check of the treated vein.

Ultrasound images

The sapheno-femoral junction

Normal Images

Thermal ablation of the GSV should respect the related tributaries of the GSV which must be able to continue the physiological drainage of blood coming from the abdomino-pelvic region. The tip of the fibre is therefore positioned under these connections, often at 1 to 2 cm below the SFJ thus preserving part or the whole proximal inter-valvular segment of the GSV.

At the early DUS control at the SFJ, there is therefore a patent stump with a length of about 20 mm [4]. The diameter of the SFJ in the weeks following the procedure gradually decreases to a physiological diameter.

The afferent tributary veins of the SFJ are visible, particularly the epigastric vein, and continue to drain into

Aucun article ou résumé dans cette revue ne peut être reproduit sous forme d'imprimé, photocopie, microfilm ou par tout autre procédé sans l'autorisation expresse des auteurs et de l'éditeur. Editions Phlébologiques Françaises
No article or abstract in this journal may be reproduced in the form of print, photocopy, microfilm or any other means without the express permission of authors and the editor. Editions Phlébologiques Françaises

the SFJ, thus "washing" the SFJ and helping to keep it patent **(Fig. 4)**.

The CFV is patent and its lumen is completely free.

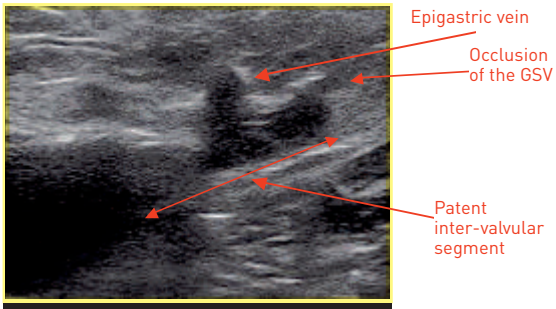

Figure 4: Sapheno-femoral junction patent, in longitudinal section, 15 days after a thermal ablation of the GSV.

Heat-induced venous thrombosis

Early DUS control can sometimes detect images of temporary thrombus in the SFJ that may extend into the CFV.

This is referred to as heat-induced thrombosis, which Kabnick called "EHITS" (Endothermal Heat-Induced Thrombosis) [4].

EHITS correspond to the propagation of a thrombus from the superficial venous network (SVN) to the SFJ or even to the deep venous network. The starting point of the thrombus is at the beginning of the endovenous thermal treatment site [5].

The EHITS were classified into 4 stages [4] **(Table 1)**.

Only stage IV is considered pathological and should be managed in the same way as a deep vein thrombosis.

Images in stages I to III **(Fig. 5)** generally do not require treatment, with simple clinical and DUS surveillance at 8-10 days being enough.

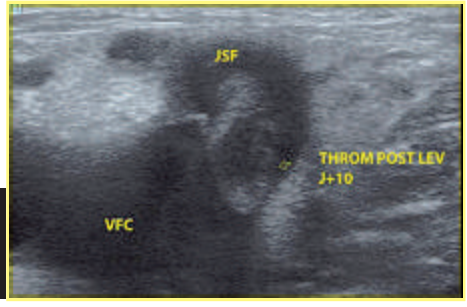

Figure 5: Example of EHITS stage 1, at 10 days after an EVLA.

Table 1: Classification of heat-induced venous thrombosis (EHITS) [4].

I	Thrombosis at the junction between the superficial and deep venous system
II	Thrombus extension in the deep venous network (thrombus with a transverse diameter of less than 50% of the deep vein lumen)
III	Thrombus extension in the deep venous network (thrombus with a transverse diameter greater than 50% of the deep vein lumen)
IV	Deep vein occlusion

Arteriovenous fistula

We mention here, an exceptional and poorly known complication. The arteriovenous fistula occurs early and, in general, does not require invasive treatment, as the communication occlusion occurs spontaneously [4].

A simple DUS monitoring will be carried out.

The VENOUS TRUNK

Regarding the treated saphenous trunk, at early DUS control, ideally in cross-section, there will be a "French rosette" image and a decrease in vein size [6].

The classical roundel image **(Fig. 6)** consists of a hyper-echoic circumferential zone, thickened corresponding to the inner wall (intima) and a hypo-echoic zone corresponding to the media and weed **(Fig. 7)**.

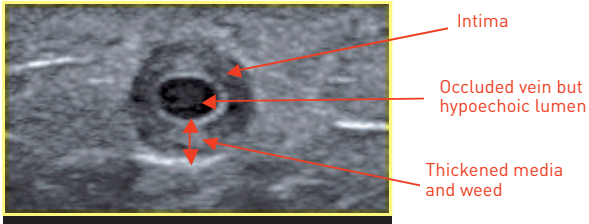

Figure 6: Trunk of GSV, in cross-section, 8 days after a thermal ablation.

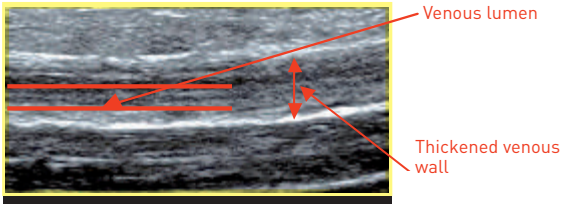

Figure 7: Trunk of GSV, in longitudinal section, 8 days after a thermal ablation

Aucun article ou résumé dans cette revue ne peut être reproduit sous forme d'imprimé, photocopie, microfilm ou par tout autre procédé sans l'autorisation expresse des auteurs et de l'éditeur. Editions Phlébologiques Françaises
No article or abstract in this journal may be reproduced in the form of print, photocopy, microfilm or any other means without the express permission of authors and the editor. Editions Phlébologiques Françaises

The venous lumen is hypo-echoic and can remain compressible under the ultrasound probe. Nevertheless, a manual compression flushing manoeuvre upstream of the explored venous segment confirms the absence of flow in this lumen.

However, this type of image is not always present, especially less frequent after RFA.

The rosette image may also be present on only one segment of the treated vein.

Other ultrasound images are possible:

- **images with an off-centre, non-central hyper-echoic zone (Fig. 8). In our experience, the hyperechoic centre image is an early specific image of RFA processing**
- **Heterogeneous circumferential images (Fig. 9).**

The content of the vein can form heterogeneous ultrasound images (Fig. 9).

- **images of vein wall ruptures (Fig. 10).**

The vein wall may have areas of rupture, its limit is then difficult to specify, as the destruction has exceeded the vein (Figure 10). These images were quite frequent with the use of bare-tip fibres for the laser, also explaining that post-procedure pain was often more severe with this type of fibre.

- **images of perivenous "halo" that correspond to a perivascular inflammation distributed around the treated vein. This halo often has a hyper-echoic aspect with poorly delineated contours (Fig. 11).**
- **no reduction in venous size and hypo-echoic aspect of the entire treated segment.**

These images may support a poor-quality occlusion with an increased risk of recanalisation over time [6] (Fig. 12).

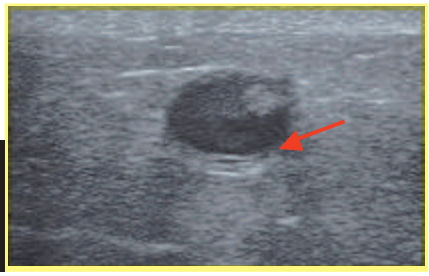

Figure 8: Image with off-centre hyperechoic zone, 9 days after RF ablation (cross-section)

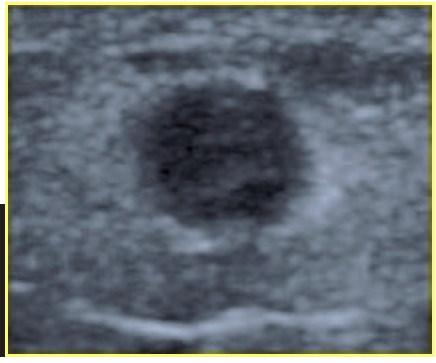

Figure 9: Heterogeneous vascular content at 8 days of endovenous thermal treatment (cross-section)

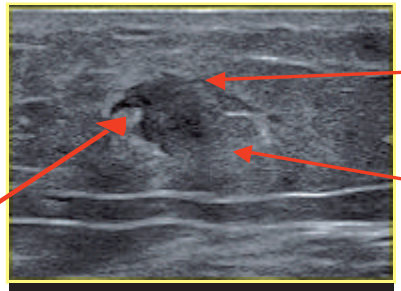

Figure 10: Image of vein wall continuity rupture (cross_section);

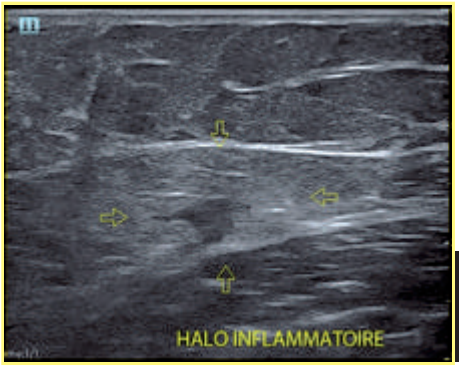

Figure 11: Perivenous inflammatory halo image (cross-section).

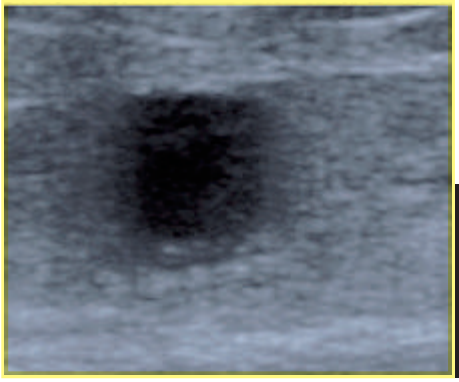

Figure 12: Absence of visible parietal thickening and homogeneous hypoechoic lumen (cross-section)

Ultrasound guided sclerotherapy (Echosclerotherapy)

Ultrasound guided foam sclerotherapy allows, in common practice, to treat the saphenous trunk but also its tributaries. The ultrasound aspects of sclerosed veins are common to both.

We will not mention DUS images of veins treated with sclerosing agent in liquid form because of its lack of specificity (particularly for remote controls) and its use, which has become exceptional for treating saphenous trunks.

Aucun article ou résumé dans cette revue ne peut être reproduit sous forme d'imprimé, photocopie, microfilm ou par tout autre procédé sans l'autorisation expresse des auteurs et de l'éditeur. Editions Phlébologiques Françaises
No article or abstract in this journal may be reproduced in the form of print, photocopy, microfilm or any other means without the express permission of authors and the editor. Editions Phlébologiques Françaises

Immediate post-procedure ultrasound inspection

Immediate ultrasound inspection, in B mode, after the injection of sclerosing foam is the fourth step in the development of the sclerotherapy technique with ultrasound guidance [7, 8].
The visualisation of sclerosing foam is easy because of the air component which provides a high echogenicity. A shadow cone image is visible.

The interest of immediate control after the injection of sclerosing foam is to highlight the venous spasm and a dense and homogeneous distribution of the foam in the target venous segment, both positive predictive criteria for the success of sclerosis.

The cross-sectional image of the vein after injection is that of a spasmed vein of very small size or even punctiform with a hyper-echoic tone due to the presence of sclerosing foam. **(Fig. 13a and 13b)**

The longitudinal cross-section image shows an "intense white line" corresponding to the venous spasm **(Fig. 14)** whose lumen is filled by sclerosing foam with a hyperechoic ultrasound aspect.

When this image is obtained, no additional injection is performed on this venous segment during the same session. On the other hand, depending on the planning, another injection may be carried out on another segment that is not or only slightly filled by the foam.

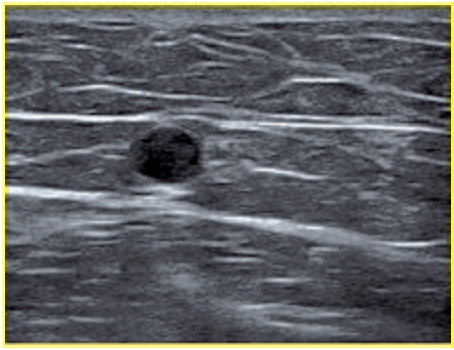

Figure 13a: GSV before injection of sclerosing foam (cross section)

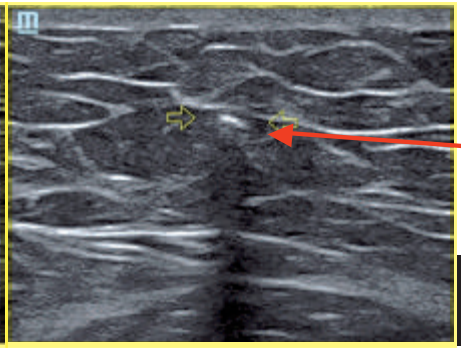

Figure 13b: GSV after injection of sclerosing foam: venous spasm

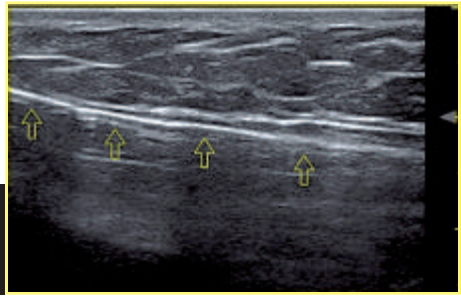

Figure 14: Venous spasm in longitudinal section, after injection of sclerosing foam

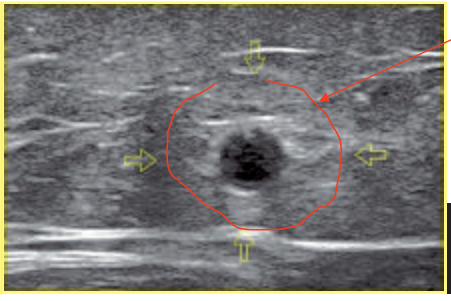

Figure 15: GSV 6 weeks after injection of sclerosing foam (cross-section)

Early Duplex ultrasound monitoring

– Objectives and planning of the control
As with the early control after thermal ablation, this assessment is aimed at safety and effectiveness. The absence of deep venous thrombosis will therefore be checked, as well as the correct occlusion of the treated venous network.
The French agency for drugs safety (Agence Nationale de Sécurité du Médicament- ANSM), in the summaries of characteristics of sclerosing products (Aetoxisclérol® and Fibrovein®) recommends clinical and DUS control at least at 1 month. [9]
The Tegernsee consensus recommends a period of 4 to 12 weeks [10].
– Ultrasound images

At this stage, the vein is occluded, incompressible.

The venous lumen is filled by homogeneously distributed hypo-echoic material whose image is like that of a thrombus.

A perivascular hypo-echoic-inflammatory halo can be noted. At this stage, the reduction in vein size may still be limited **(Fig. 15)**.

The vascular wall begins to change, it becomes hyper-echoic. This increased echogenicity is circumferential and sometimes discontinuous.

Aucun article ou résumé dans cette revue ne peut être reproduit sous forme d'imprimé, photocopie, microfilm ou par tout autre procédé sans l'autorisation expresse des auteurs et de l'éditeur. Editions Phlébologiques Françaises
No article or abstract in this journal may be reproduced in the form of print, photocopy, microfilm or any other means without the express permission of authors and the editor. Editions Phlébologiques Françaises

Ultrasound assessment after 6 months

Beyond 6 months, the evolution of ultrasound images of the treated vein is similar whether the treatment was thermal (EVLA or RFA) or by sclerosing foam.

Ideally, all treated saphenous trunks evolve towards fibrosis or even a virtual disappearance of ultrasound images.

However, there is a time difference in this evolution. Indeed, it is after the laser, that fibrosis sets in fastest, usually within 3 to 6 months after the procedure [6].

In the case of sclerosing foam, the fibrosis process can sometimes take 1 to 2 years [11, 12].

We will differentiate between images on the saphenous trunk and those of the SFJ.

The saphenous trunk

If the treatment is successful, the treated vein progresses to hyperechoic images and then to fibrosis over the entire treated venous segment **(Fig. 16)**.

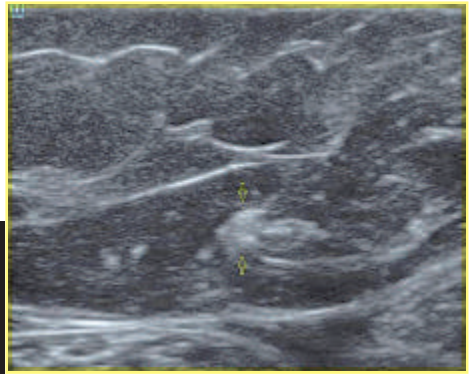

Figure 16: Fibrosis of the GSV 9 months after injection of sclerosing foam (cross-section)

This change in ultrasound appearance is always associated with a marked reduction in size.

Over time this fibrous cord may disappear. The vein is atrophied. There is no longer a specific image.

In the event of treatment failure, there is an image of partial, total or segment recanalisation associated with venous reflux.

It should be noted that the closure of perforators in saphenous trunks is a "risk zone" for recanalisation due to the venous pressures and "washing" that can occur with these deep venous supplies. Parietal increased echogenicity is present, generally circumferential at this stage **(Fig. 17)**.

It is also possible to find partial recanalisation images with or without reflux.

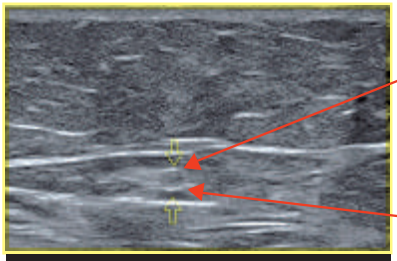

Figure 17: GSV 10 months after injection of sclerosing foam (cross section).

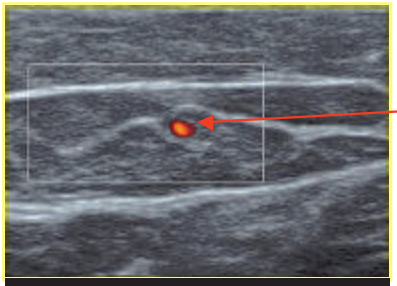

Figure 18: GSV 10 months after foam sclerosing treatment: partial recanalisation.

The venous wall is generally thickened, the circulating channel is not necessarily centered **(Fig. 18)**.

The sapheno-femoral junction

The SFJ remains patent at a distance from the treatment.

It continues to perform its role of draining abdomino-pelvic veins.

Its size evolves towards a physiological diameter.

Over time, the SFJ in its proximal part evolves towards a "flute mouthpiece" image **(Fig.19)**. This ultrasound appearance occurs due to the reduction in size of the saphenous trunk and the maintenance of a physiological diameter of the SFJ.

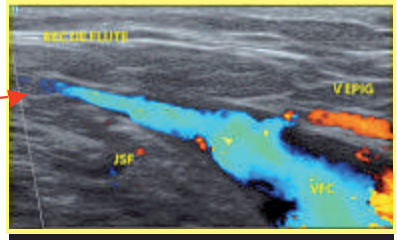

Figure 19: Sapheno-femoral junction, 6 months after thermal ablation of a GSV.

Aucun article ou résumé dans cette revue ne peut être reproduit sous forme d'imprimé, photocopie, microfilm ou par tout autre procédé sans l'autorisation expresse des auteurs et de l'éditeur. Editions Phlébologiques Françaises
No article or abstract in this journal may be reproduced in the form of print, photocopy, microfilm or any other means without the express permission of authors and the editor. Editions Phlébologiques Françaises

Conclusion

Ultrasound examinations are carried out early and later, after endovenous treatments. Their purpose is to evaluate the safety and effectiveness of these treatments.

Beyond the tone of the ultrasound images (hypo or hyperechoic), the retraction kinetics of the treated venous segment is undoubtedly a determining factor in predicting the evolution towards venous fibrosis.

Bibliography

[1] Weiss RA. Comparison of endovenous radiofrequency versus 810 nm diode laser occlusion of large veins in animal model. Dermatol Surg 2002;28(1):56-61.

[2] Haute Autorité de Santé (HAS). Occlusion de veine saphène par laser par voie veineuse transcutanée. Rapport d'évaluation technologique. Service évaluation des actes professionnels. Avril 2008. http://www.has-sante.fr/portail/upload/docs/application/pdf/2008-07/rapport_laser_saphene_vd_2008-07-29_10-34-45_555.pdf.

[3] Coleridge-Smith P., Labropoulos N., Partsch H., Myers K., Nicolaides A., Cavezzi A. Duplex Ultrasound Investigation of the Veins in Chronic Venous Disease of the Lower Limbs—UIP Consensus. Document. Part I. Basic Principles. Eur J Vasc Endovasc Surg. 2006 Jan;31(1):83-92.

[4] Dexter D., Kabnick L., Berland T, Jacobowitz G., Lamparello P., Maldonado T., Mussa F., Rockman C., Sadek M, Giammaria LE., Adelman M. Complications of endovenous laser. Phlebology, March 2012; vol. 27, suppl 1: pp. 40-45.

[5] Aspects échographiques après procédure Phlébologie 2013 N° 2 p. 87 (spécial laser endoveineux).

[6] Hamel-Desnos C., Gérard J.L., Pichot O. Traitements endoveineux Thermiques. In: La Maladie veineuse chronique. Elsevier Masson SAS 2015 : 127-149.

[7] Hamel-Desnos C., Desnos P., Ouvry P. Nouveautés thérapeutiques dans la prise en charge de la maladie variqueuse : échosclérothérapie et mousse. Phlébologie 2003, 56, N° 1, 41-8.

[8] ANAES. Traitement des varices des membres inférieurs. Rapport de l'Agence Nationale d'Accréditation et d'Évaluation en Santé. Service Évaluation en santé publique – Évaluation technologique Juin 2004.

[9] ANSM. Résumé des caractéristiques du produit Aetoxisclérol® 2%; mise à jour 01.07.2013. En ligne, http://agence-prd.ansm.sante.fr/php/ecodex/rcp/R0225040.htm.

[10] Breu FX, Guggenbichler S, Wollmann JC. 2nd European Consensus Meeting on Foam Sclerotherapy 2006, Tegernsee, Germany. Vasa. 2008;37 Suppl 71:1-29. Epub 2008/04/23.

[11] Hamel-Desnos C, Ouvry P, Benigni JP, Boitelle G, Schadeck M, Desnos P, et al. Comparison of 1% and 3% polidocanol foam in ultrasound guided sclerotherapy of the great saphenous vein: a randomised, double-blind trial with 2 year-follow-up. «The 3/1 Study». Eur J Vasc Endovasc Surg. 2007;34(6):723-9; discussion 30. Epub 2007/09/22.

[12] Hamel-Desnos C, Moraglia L, Ramelet AA. Sclérothérapie. In: La Maladie veineuse chronique. Elsevier Masson SAS 2015 : 89-126.